

Efficiency of Percutaneous Transhepatic Biliary Stent Implantation in Management of Obstructive Biliary Pathologies: A Study in a Tertiary Care Hospital in Eastern India

Dr. Debashis Dakshit, Dr. Prithvijit Chakraborty*

Associate Professor, Medical College & Hospital, Kolkata

Resident, Medical College & Hospital, Kolkata

*Corresponding Author: Dr. Prithvijit Chakraborty

ABSTRACT:-

Objectives- Treatment by percutaneous biliary drainage and stenting plays an important role in the management of the patients of obstructive biliary pathologies presenting in poor general condition and inoperable state. Drainage or stenting in patients with malignant biliary obstruction not only can relieve the symptoms and signs of obstructive jaundice but also optimizes the patient's condition for surgical resection or for receiving palliative chemotherapy or radiotherapy, bringing about an improvement in their quality of life, even if only for a matter of weeks or months. In this study we have retro-spectively evaluated the efficiency of percutaneous transhepatic biliary stent implantation in management of obstructive biliary pathologies presented in our institute.

Methods:- A retrospective study was done at our institute between February 2018 to February 2019. 16 patients of obstructive jaundice due to obstructive biliary pathologies admitted at our institute were included in the study after they met the inclusion criteria.

Results:- In our study, the average age of male patients was 62 years and that of female patients was 56 years. The overall average age was 58.6 ± 2.8 years. As our institute has a regional cancer centre, most of the patients admitted had malignant biliary obstruction (87.5%). Among them, bile duct involvement of most of them (57.1%) was of Bismuth Type 1. Most (42.8%) of the malignant biliary strictures were due to cholangiocarcinoma. The most striking result of our study was that all the PTBD with SEMS implantation cases were successful and in each of the cases the direct bilirubin level came to subclinical level within 3 weeks.

Conclusion:- PTBD with stent implantation offers a safe and effective method in providing palliative treatment for patients with biliary obstruction. At times, it can be considered as an alternative of endoscopic stent placement in a hospital with well equipped IR set up due to its shorter on table time, shorter post operative hospital stay, ability and effectivity in management of biliary obstruction at different levels.

KEYWORDS:- Percutaneous transhepatic biliary drainage; Internal external drainage; Self expandable metallic stents; Malignant biliary obstruction; Magnetic compression anastomosis;

Date of Submission: 18-03-2020

Date of Acceptance: 03-04-2020

LIST OF ABBREVIATIONS:-

ERCP= Endoscopic retrograde cholangiopancreatography;

MRCP= Magnetic resonance cholangiopancreatography;

PTC= Percutaneous transhepatic cholangiography;

PTBD= Percutaneous transhepatic biliary drainage;

SEMS= Self expandable metallic stents;

BBS= Benign biliary stricture;

DES= Drug eluting stent;

MCA= Magnetic compression anastomosis;

I. Introduction:-

Many of the patients of obstructive jaundice due to obstructive biliary pathologies, especially patients with malignant biliary obstruction often present in poor general condition and inoperable state. Treatment by percutaneous biliary drainage and stenting plays an important role in their

overall management. Drainage or stenting in patients with malignant biliary obstruction can relieve the symptoms and signs of obstructive jaundice. This optimizes the patient's condition for surgical

resection or for receiving palliative chemotherapy or radiotherapy, bringing about an improvement in their quality of life, even if only for a matter of weeks or months. In this study we have retro-spectively

evaluated the efficiency of percutaneous transhepatic biliary stent implantation in management of obstructive biliary pathologies presented in our institute.

II. Materials And Methods:-

A retrospective study was done at our institute between February 2018 to February 2019. 16 patients of obstructive jaundice due to obstructive biliary pathologies admitted at our institute were included in the study after they met the inclusion criteria.

Institutional Ethics Committee: Approval from institutional ethics committee obtained.

Inclusion criteria:

1. Patients of obstructive jaundice due to obstructive biliary pathologies presenting in poor general condition and/or inoperable state.
2. Patients who gave consent to take part in the study.

Exclusion criteria:

1. Patients of obstructive jaundice due to obstructive biliary pathologies presenting in operable state.
2. Patients who refused to take part in the study.

Before the data of the patients were collected and analysed, following informations were obtained -

- Age, Sex
- History of present illness, past history, drug history and family history of neoplastic disorders
- Clinical features and examination findings were noted
- Records of baseline laboratory investigations like Complete Blood Count, serum lipid profile, blood sugar, serum creatinine, ECG, Chest X-ray were noted.
- Liver function test with liver enzyme levels and direct and indirect bilirubin levels, Serum PT-INR profile and serology for Hepatitis B, Hepatitis C and HIV were also checked.
- Pre-operative Imaging evaluation of hepatobiliary system by ultrasonography, contrast enhanced computed tomography and Magnetic resonance cholangiopancreatography.

Findings were recorded in predesigned and pretested case record sheet for subsequent analysis.

Patient preparation and Procedure: Pre-procedure preparation of patients included a single dose of prophylactic antibiotics (cefuroxime and metronidazole), checking the coagulation results and obtaining informed consent. The preprocedure imaging was reviewed and was an important aspect of interventional radiology practice. The procedure was performed under local anaesthetic (1% Lidocaine) with sedo-analgesia using intravenous midazolam (1-6 mg) and fentanyl (25-100 micrograms) under continuous monitoring until the end of the procedure. The PTBD and stenting were performed with US-guided and digital subtraction angiography. Cholangiography was first used to evaluate the exact level and extension of the stenosis or stenoses and to select the most appropriate liver segments for drainage. We used **Bard E-LUMINEXX® Vascular Stent**, 10 mm x 80 mm, 80 cm catheter length, 6 Fr self-expanding metallic stent for insertion alongside the guide-wire into the narrow segment. All patients were monitored for vital signs, oxygen saturation, and liver and kidney function post-surgery, and routine blood investigations were performed. Rehydration was considered paramount to protect the liver and prevent infection.

III. Results:-

In our study, number of male and female patients were almost similar (Male=7, Female=9). The average age of male patients was 62 years and that of female patients was 56 years. The overall average age was 58.6 ± 2.8 years. As our institute has a regional cancer centre, most of the patients admitted had malignant biliary obstruction (87.5%). Only 12.5% patients had benign biliary strictures, all of whom gave history of post operative biliary stricture following bile duct injury during choledocholithiasis. Among patients having malignant biliary strictures, bile duct involvement of most of them (57.1%) was of Bismuth Type 1. Among them, 50% involved distal CBD , 37.5% involved proximal CBD and 12.5% involved whole length of CBD. 21.4% was of Bismuth Type 2 (involving confluence). 7.1% stricture was of Bismuth Typa IIIA. 14.3% stricture involved the ampulla of CBD.

While reviewing the etiologies, we came to know that 42.8% of the malignant biliary strictures were due to cholangiocarcinoma, 35.7% were due to metastasis (among which 80% were from gallbladder carcinoma, rest 20% were from hepatocellular carcinoma). 14.28% were due to periampullary carcinoma and 7.1% were due to pancreatic carcinoma. The most striking result of our study was that all the PTBD with SEMS implantation cases were successful and in each of the cases the direct bilirubin level came to subclinical level within 3 weeks.

IV. Discussion:-

The current biliary interventional techniques can be divided at the most basic level into endoscopic procedures and percutaneous procedures. Combined procedures, where both endoscopic and percutaneous biliary approaches are employed, are used less frequently. In **Endoscopic retrograde cholangiopancreatography (ERCP)**, a side-viewing endoscope allows visualisation of the ampulla and cannulation of the bile duct. Cholangiography is performed, and wires and catheters can be passed into the bile ducts. A large range of instrumentation can then be deployed, including balloon catheters and baskets for removing stones, brushes for taking bile duct wall specimens, and plastic and metallic biliary stents. Fine needle **percutaneous transhepatic cholangiography (PTC)** became a commonly performed procedure in the 1980s to evaluate and treat biliary tract obstruction. Typically, a 22 gauge needle is passed through the skin into the liver and then into a bile duct and contrast is injected to opacify the biliary system. For therapeutic procedures a wire is then passed down the needle and into the bile duct; this then allows a large variety of instruments to be used. For instance, balloon catheters can be inserted to dilate strictures, biliary drain tubes can be placed to relieve obstruction or infection, and stents can be deployed. **Percutaneous transhepatic biliary drainage** play an important role in the treatment of both benign and malignant biliary disease. Current indications include the treatment of biliary obstruction when endoscopic techniques are not appropriate or have failed. These include complex hilar or intrahepatic bile duct obstruction, interventions involving biliary-enteric anastomoses (where the normal transampullary ERCP access is lost), the evaluation and treatment of post-surgical bile duct injuries and as access for treatment of biliary stone disease. The main contraindication to PTBD is deranged clotting parameters which can usually be corrected with intramuscular or intravenous Vitamin K or fresh frozen plasma transfusion. Ascites is a relative contraindication and, if present, an ascitic drain is routinely placed before or at the time of PTBD. Patients presenting with obstructive jaundice due to malignancy with cholangitis or very high bilirubin levels undergo external or external and internal biliary drainage after diagnostic imaging, usually with ultrasonography and contrast enhanced computed tomography (CT). Magnetic resonance cholangiopancreatography may be useful in more complex cases to plan drainage and stenting in malignancies causing hilar, segmental or proximal common bile duct (CBD) obstructions. A preliminary ultrasound (US) of the liver helps in the assessment of intra and extra hepatic biliary duct dilatation and in locating the gall bladder and hepatic mass lesions. The US scan also helps plan the approach and allows selective ductal puncture. This relieves jaundice and sepsis and decreases the risk of hepato-renal failure. Stents can occasionally block due to either biliary sludge or tumor recurrence resulting in the reappearance of jaundice. Then a similar size or smaller metal stent is coaxially inserted into the blocked one with or without balloon dilatation. Immediate complications of PTBD include pain at the site of puncture; bile leak; intrahepatic and extrahepatic bleeding, including haemobilia; pneumothorax; haemothorax; septicaemia; and catheter related problems of kinking or dislocation. Patients may find the left lobe punctures less painful as these do not cross the intercostal space, although bile leak or bleeding may be more common as there may be less liver to tamponade the puncture tract. Bile leak and bleeding may be mild to severe, resulting in pain secondary to peritonitis, especially referred pain at the shoulder tip. Pneumothorax and haemothorax are rare and may result from traversing the pleura. Late complications include cholangitis, pancreatitis, liver abscess, septicaemia, drainage catheter or stent blockage, and arterial or venous biliary fistula.^[1]

Stent technology has undergone a rapid series of advances over the last two decades. The introduction of nitinol, a nickel-titanium alloy, which exhibits the properties of superelasticity and thermal shape memory has led to the introduction of a new generation of stents. These stents demonstrate increased flexibility and conformability compared to their stainless steel predecessors, without significant compromise in stent radial force. Nitinol's good biocompatibility and suitability for MR imaging are additional benefits. Stent properties such as the radial force, radio-opacity and flexibility can be modified by the use of similar alloys such as Platinol®. Originally only uncovered self-expandable metallic stents (USEMS) were available. Covered SEMS (CSEMS) are now available; these stents are lined with a material that prevents passage of materials between the metal interstices of the stent. These stents can be used to treat bile leaks, or to treat malignant obstruction. Covered stents are also now manufactured either fully covered or partially covered (PCSEMS) for different indications. The introduction of both PCSEMS and fully covered SEMS has further improved stent patency rates especially in malignant disease by reducing or eliminating the problem of tumor ingrowth. The design of the metallic structure of the stent can also be varied. Metallic biliary stents are usually uniform in structure along their length, but stents are now available that have larger gaps in the metallic material at certain points.^[2] **Metallic stents** are also now available in removable forms. This potentially broadens the clinical applications of metallic stents into treatment of benign strictures. Removable stents are available for both percutaneous and endoscopic insertion and percutaneous stents can be retrieved either percutaneously or endoscopically. Endoscopic covered stent removal can be performed using snare forceps to grip the tip of the stent, which is then pulled towards the working channel of the duodenoscope. Some stents, for example, Niti-S covered biliary stents, contain a removal suture that collapses the stent when pulled. This can be gripped with

biopsy forceps endoscopically or 'hooked' and withdrawn into a sheath using a specifically designed device for percutaneous removal. This allows the stent to be pulled inside-out easily during removal. The timing of removal is dependent on a number of technical and clinical issues, but in the setting of benign biliary strictures covered stent removal is usually performed approximately 6–8 weeks following insertion. When used to treat bile leaks, stents are often left for longer and are usually removed approximately 3 months after insertion. In malignant disease, the primary indication for percutaneous biliary intervention remains the palliation of biliary obstruction in patients who are either unfit for surgery or who have an unresectable tumor.

Malignant biliary obstruction is usually due to a primary pancreatico-biliary malignancy or less commonly external biliary compression by lymphadenopathy or metastatic disease. Other indications for PTC in malignant disease include percutaneous endobiliary biopsy and biliary drainage as an adjunct to surgical intervention. Percutaneous biliary stenting using SEMS became established in the late 1980s following the first percutaneous placement in a canine model in 1985. There continues to be a role for both percutaneous and endoscopic techniques depending on the anatomical location of the biliary obstruction, local expertise and postsurgical anatomy following any previous upper gastrointestinal surgery. The use of USEMS is well established. SEMS have been shown to be superior to plastic stents with lower complication rates, longer patency rates and require fewer re-interventions. Numerous studies have shown that patients with malignant biliary obstruction, unsuitable for surgery and with a life expectancy of greater than 4–6 months should be treated with USEMS rather than endoscopic plastic stents.^[3] Imaging findings in patients with suspected malignant biliary obstruction are often nonspecific. As pathology guides treatment regimes and prognosis, an attempt should be made to obtain a tissue diagnosis in patients undergoing transhepatic drainage. Cytological evaluation of bile aspirated at the time of PTC is rarely performed as it has been shown to have a very poor sensitivity of 15%. Endobiliary brushings done at the time of PTC have sensitivities of up to 75% but poor negative predictive values of around 12.5%. The reported sensitivity of biopsy using percutaneous biliary forceps biopsy is higher (78%) than for cytology, and is even higher for cholangiocarcinoma (94%). Percutaneous biliary drainage with crossing of the stricture, at which time a stent(s) can be deployed, is usually possible, although occasionally an external drain only is required at first attempt and, in the presence of significant biliary sepsis, this may be initially safer. A one stage PTC and stenting with either placement of a temporary small access catheter or rarely immediate removal of percutaneous access and tract embolization, has obvious benefits for patients in terms of hospital stay and quality of life. The newer lower profile stent delivery systems reduce the occasions when predilation is required. USEMS used to treat malignant biliary obstruction are prone to re-obstruction due to sludge, stone formation and tumor obstruction (both overgrowth at the ends of the stent and ingrowth through the interstices of the stent). In an attempt to reduce tumor ingrowth, prolong stent patency and avoid reintervention, there has been increasing interest in the use of both PCSEMS and CSEMS. The majority of studies comparing covered and uncovered stents have demonstrated improved patency rates in the covered stent group. Complications and cost were similar in both groups. Importantly, patency rates were significantly higher in the CSEMS group.^[4] Reinterventions were significantly lower in the CSEMS group with stent dysfunction. This suggests that the use of CSEMS could play an important role in reducing reinterventions and maintaining quality of life. A recent meta-analysis of studies comparing uncovered and covered metal stents in malignant distal biliary obstruction shows improved patency rates in the covered group. Earlier studies had shown higher rates of cholecystitis and pancreatitis when using CSEMS but this meta-analysis demonstrated these complications were not significantly higher in the covered stent group. Patient selection remains of key importance in planning percutaneous biliary drainage. Patients with very advanced or rapidly progressive cancer may have such limited survival that a CSEMS is unlikely to provide any benefit. The value of being able to remove a covered biliary stent has the potential to make a major impact on current clinical practice, particularly in patients who have a suspected but unconfirmed bile duct malignancy; placement of such a stent is not an irrevocable step and options are preserved. A lack of consensus remains regarding use of stents in preoperative biliary drainage both in patients who are candidates for pancreaticoduodenectomy or hepatic resection. Most clinical studies have failed to support experimental data which suggests preoperative drainage would lead to improved surgical outcomes. A recent review of the literature concludes that preoperative drainage should be reserved for patients with proximal obstruction, cholangitis, renal failure, or who are planned for neoadjuvant chemotherapy.^[5] Hilar malignancy includes all tumors involving the confluence of the left and right hepatic ducts or the proximal 2cm of the common hepatic duct. Cholangiocarcinoma is the most common malignancy in this region, but intrahepatic and perihilar metastatic disease as well as gall bladder carcinoma can also cause anatomically similar biliary obstruction. Malignant hilar biliary obstruction is a particularly challenging area in interventional biliary radiology; obtaining a tissue diagnosis and achieving longterm palliation in hilar cholangiocarcinoma are both often difficult. Accurate preprocedure imaging is of critical importance, and good quality MRCP is an invaluable tool for procedural planning. The Bismuth system of classification of hilar cholangiocarcinoma is a well-established method of describing these lesions. Accurate imaging, most often a combination of CT and MRI and MRCP, helps determine potential resectability which provides the main

opportunity for longterm survival. In the majority of patients, surgery is not possible and palliation in most centres involves biliary stenting. Percutaneous biliary drainage and stenting (usually using ultrasound guidance) has the distinct advantage over ERCP in hilar disease in that one or more appropriate segments for drainage can be selected with confidence. This has the added benefit of avoiding injection of contrast medium into segments that are too small to be drained. The exact details of a malignant hilar stenting procedure can be complex. The operator can choose to place a single unilobar stent, or can choose to drain both sides of the liver. If multiple stents are used, one stent can be placed through the interstices of another, or the stents can be placed alongside each other. The stent(s) can be passed all the way into the duodenum, or the inferior part of the stent can be left within the normal portion of the common duct. However, there is no strong evidence that routine bilateral stenting confers benefit over unilateral stenting in Bismuth II–IV strictures, and involves potentially more discomfort, cost and hospitalization. There are cases, however, based on the need to drain infected segments or a larger volume of liver, where bilateral stenting is preferable. These decisions are often made based on anatomical considerations, patient factors and individual operator preference and experience.^[6]

Benign disease: Bile duct injuries- The majority of bile duct injuries are due to biliary tract surgery, in particular laparoscopic cholecystectomy, with traumatic bile duct injuries, both blunt and penetrating, accounting for only a small percentage. Anastomotic bile leaks after pancreaticoduodenectomy may also require biliary intervention. Both percutaneous and endoscopic techniques have a role, both as definitive treatments for bile duct injuries and as adjuncts to surgery. If possible, the location and extent of the injury should be characterized using non-invasive imaging such as computed tomography, ultrasonography and magnetic resonance cholangiopancreatography. CT cholangiography using Biliscopin and MR cholangiography using hepatocyte-specific contrast agents have also been successfully used to confirm and locate bile leaks. ERCP and PTC should rarely be required as purely diagnostic tests and are generally reserved for interventions. Prompt percutaneous biloma drainage reduces the incidence of complications such as abscess formation and cholangitis. PTC with biliary drainage is often required in cases where there is complete ductal transection or ligation, proximal duct injury or following injury to an aberrant right hepatic duct. Ideally an internal-external catheter should be placed but if not technically possible then an external catheter allows drainage and serves as a useful landmark for subsequent surgery or allows further radiological intervention. Bilateral drainage is often required for hilar injuries and targeted segmental drainage for transection of an aberrant right hepatic duct. Ultrasound guided bile duct puncture is therefore essential for this type of targeted approach and allows highly accurate punctures to be performed. Although the published literature is limited to a few studies, the use of removable CSEMS in the treatment of complex or persistent bile leaks after laparoscopic cholecystectomy or pancreaticoduodenectomy has shown promising results. In the more specialised orthotopic liver transplant group with persistent bile leak after plastic stent placement, the use of CSEMS has been shown to successfully treat the leak but with high rates of post-stent-removal strictures.^[7] **Benign biliary strictures (BBS)** may be due to postoperative duct injury, primary sclerosing cholangitis, anastomotic strictures, chronic pancreatitis or strictures secondary to biliary calculi. Strictures can lead to a broad spectrum of clinical presentations from mildly abnormal liver function tests to obstructive jaundice or cholangitis. The initial priority is restoration of biliary drainage, usually endoscopically in patients with distal strictures in native ducts or percutaneously

in patients with proximal or biliary-enteric anastomotic strictures. Endoscopic treatment has typically involved balloon dilatation and the placement of 10–12 Fr plastic biliary stents which are replaced every 3–4 months, usually for up to 1 year. In patients who are not suitable for endoscopic therapy, reported percutaneous transhepatic techniques have involved drainage, balloon dilatation and the placement of both uncovered and covered metal stents. Decisions on how best to treat BBS depend on their cause and their anatomical location. The most widely practiced percutaneous transhepatic treatments of BBS have been either sequential balloon dilatations of the stenosis every 2–3 weeks with an access catheter left *in situ* between dilatations or sequential upsizing of an internalexternal biliary drain placed across the stenosis which allows slow tract dilatation. Balloon diameter selection depends on the site of stenosis but typically 10 mm balloons are used for common bile duct stenosis, while 6–8 mm balloons are suitable for intra hepatic ducts stenoses. The balloon size should be guided by the size of the adjacent normal caliber duct. The use of cutting balloons has been described to treat BBS that respond poorly to initial conventional balloon dilatation either due to being markedly fibrotic or demonstrating significant elastic recoil. However the relatively high stricture recurrence rates following balloon dilatation has led to the more widespread use of metal stents. Uncovered metal stents should not be used in benign disease due to their poor long-term patency rates and the inability to remove them. A number of studies have shown excellent results in the use of covered removable metal stents to treat balloon dilatation resistant BBS. In the setting of non-transplant BBS, multiple studies have shown favourable results for the endoscopic placement of CSEMS with 100% success in attempted stent removal and stricture resolution following stent removal in 77–90%. Percutaneous transjejunal biliary intervention is a technique developed to allow repeated percutaneous access to the biliary system for the treatment of benign biliary strictures and calculi. A Roux-en-Y loop created at the time of the biliary enteric anastomosis is surgical fixed to the anterior abdominal wall and

marked with clips to allow subsequent percutaneous fluoroscopic puncture. As post-operative benign biliary stricture recurrence requiring re-intervention ranges between 10–45%, repeated access to the biliary tree is required. The transjejunal procedure avoids the morbidity and discomfort of a percutaneous transhepatic approach and allows access to all segments of the biliary tree which can be repeated over a long period as needed, with high success rates and minimal complication rate. The technique, using ballooning or stenting, can also be used in patients who have tumor recurrence or fibrotic stricturing following resection for malignant Obstruction. Biliary strictures are the most frequent type of late biliary complication following liver transplant with an incidence of up to 15%. Post transplant bile duct strictures are classified as anastomotic strictures (AS) or non-anastomotic strictures (NAS) with the latter showing poor response to treatment and a higher rate of graft loss of up to 50% at 10 years. Historically, the post-orthotopic liver transplant biliary strictures were treated surgically, usually with the formation of a Roux-en-Y hepaticojejunostomy. However, with advances in therapeutic endoscopy and the development of removable endoscopic and percutaneously delivered stents over the past two decades, these non-surgical approaches are now considered the treatment of choice in most centres. When conventional endoscopic treatments have failed to treat AS following orthotopic liver transplant, placement of a removable CSEMS can lead to successful treatment of the stricture but with a significant stent migration rate. One significant advantage of using covered removable stents is a marked reduction in the average duration of treatment. **Biliary calculi** may be located in either the intrahepatic or extrahepatic biliary tree. Intrahepatic calculi, located proximal to the confluence of the right and left hepatic ducts are commonly associated with strictures and have a much higher incidence in far eastern Asian populations where parasitic infections play an important role in etiology. Endoscopic retrograde treatments for intrahepatic stones can be very challenging and therefore percutaneous techniques play a significant role, particularly in the patient who presents with cholangitis. Management usually involves establishing effective percutaneous transhepatic drainage and then subsequent cholangioscopy with stone removal or fragmentation. Endoscopic treatment may be unsuccessful due to challenging access to the bile duct, large or impacted stones or intrahepatic stones. If endoscopic retrograde techniques fail, a good alternative for stone clearance is a complete percutaneous procedure. A variety of percutaneous methods for stone extraction have been described including the use of forceps or Dormia baskets both of which have success rates of nearly 95% but require large transhepatic tract diameters. Alternative percutaneous techniques have also been described, including antegrade papillary balloon dilatation with a reported stone clearance rate of 96%. The transjejunal approach is very useful if there has been a biliary-enteric anastomosis with the jejunal loop surgically fixed. Stone clearance may take more than one session and stones have a tendency to recur so this long-term access approach is particularly appealing, either for stone disease alone or stone disease associated with strictures.^[8]

Future perspective- Stents- Technological advances need to address problems of current stents such as migration, tumor in-growth and stent obstruction. Two recent developments in stent design are the introduction of drug-eluting stents and biodegradable stents. Drug-eluting stents are impregnated with a chemotherapeutic agent to achieve locally high doses of agents whose antitumoral effects are proposed to reduce tumor growth and prolong stent patency. Studies have shown drug eluting metal stents to be safe with acceptable complication rates. Biodegradable biliary stents have been developed to minimize the problems of a long-term foreign body or the need for a further procedure to remove stents. Initial studies in animal models demonstrate that these stents appear safe and do not migrate. Combination biodegradable, drug-eluting stents are also undergoing clinical trials.^[9]

Magnetic compression anastomosis- Magnetic compression anastomosis (MCA) is a nonsurgical technique for luminal recanalization in the digestive or biliary system using a pair of specially designed rare earth metal magnets. These are placed on either side of the obstruction and the magnet attraction and approximation causes tissue compression creating an effective

luminal anastomosis. In the small group of patients in whom conventional percutaneous or endoscopic methods have both failed, this technique has been used as an alternative to either surgery or lifelong external drainage.^[10] In the biliary system MCA has been shown to be both safe and effective in the setting of duct-to-duct anastomotic strictures following liver transplantation. MCA has also been used in the palliative setting to treat obstructive jaundice caused by malignant disease by the creation of a biliaryenteric anastomosis. One magnet is placed transhepatically within the bile duct, above the level of obstruction and the second magnet delivered into the duodenal lumen. Tissue compression and necrosis results in the formation of a biliary-enteric anastomosis with one study showing no procedural complications and a significant fall in bilirubin levels in all patients at 1 week.^[11]

V. Conclusion:-

PTBD with stent implantation offers a safe and effective method in providing palliative treatment for patients with biliary obstruction. At times, it can be considered as an alternative of endoscopic stent placement in a hospital with well equipped IR set up due to its shorter on table time, shorter post operative hospital stay,

ability and effectivity in management of biliary obstruction at different levels. Recent advancements in stent technology will further add to its efficiency in management of these patients.

CONFLICT OF INTEREST: There are no conflicts of interest.

SOURCE OF SUPPORT: Nil

REFERENCES:-

[1]. Pomerantz BJ. Biliary tract interventions. *Tech. Vasc. Interv. Radiol.* 12(2), 162–170(2009).
 [2]. Stoeckel D, Pelton A, Duerig T. Selfexpanding nitinol stents: material and design considerations. *Eur. Radiol.* 14(2), 292–301(2004).
 [3]. Moss AC, Morris E, Leyden J, MacMathuna P. Do the benefits of metal stents justify the costs? A systematic review and meta-analysis of trials comparing endoscopic stents for malignant biliary obstruction. *Eur. J. Gastroenterol. Hepatol.* 19(12), 1119–1124(2007).
 [4]. Krokidis M, Fanelli F, Orgera G et al. Percutaneous palliation of pancreatic head cancer: randomized comparison of ePTFE/FEP-covered versus uncovered nitinol biliary stents. *Cardiovasc. Intervent. Radiol.* 34(2),352–361 (2011).
 [5]. Van der Gaag NA, Rauws EA, van Eijck CH et al. Preoperative biliary drainage for cancer of the head of the pancreas. *New Engl. J. Med.* 362(2),129–137 (2010).
 [6]. Van Delden OM, Lameris JS. Percutaneous drainage and stenting for palliation of malignant bile duct obstruction. *Eur. Radiol.*18(3), 448–456 (2008).
 [7]. Alegre Castellanos A, Molina Granados JF, Escribano Fernandez J, Gallardo Munoz I, Trivino Tarradas Fde A. Early phase detection of bile leak after hepatobiliary surgery: value of Gd-EOB-DTPA-enhanced MR cholangiography. *Abdom. Imaging* 37(5),795–802 (2012).
 [8]. Seehofer D, Eurich D, Veltzke-Schlieker W, Neuhaus P. Biliary complications after liver transplantation: old problems and new challenges. *Am. J. Transplant.* 13(2), 253–265(2013).
 [9]. Shi J, Lv Y, Yu L. Interest of a new biodegradable stent coated with paclitaxel on anastomotic wound healing after biliary reconstruction. *Eur. J. Gastroenterol.Hepatol.*25 (12), 1415 –1423 (2013)
 [10]. Avaliani M, Chigogidze N, Nechipai A, Dolgushin B. Magnetic compression biliary-enteric anastomosis for palliation of obstructive jaundice: initial clinical results. *J. Vasc. Interv. Radiol.* 20(5), 614–623 (2009).
 [11]. K S Madhusudhan et al. Radiological interventions in malignant biliary obstruction *World J Radiol.* 2016 May 28; 8(5): 518–529.

S.No	Indications of PTBD
1.	Adequate biliary drainage or diversion with or without stent placement
2.	Establish biliary access to <ul style="list-style-type: none"> • Dilate biliary strictures • Remove bile duct stones • Stent placement • Brachytherapy/phototherapy • Endoluminal tissue sampling/foreign body retrieval.
3	Manage post-operative complications <ul style="list-style-type: none"> • Failed pancreatico-jejunostomy anastomosis • Failed bilio-enteric anastomosis • Duodenal stump insufficiency • Post-operative leak from extrahepatic bile ducts

Table 1: Incications of PTBD

Type	Description
I	Involving common hepatic duct (CHD)
II	CHD and confluence of right hepatic duct (RHD) and left hepatic duct (LHD)
IIIA	CHD, primary confluence and RHD
IIIB	CHD, primary confluence and LHD
IV	CHD, primary confluence, involving both RHD and LHD






TYPE I	TYPE II	TYPE IIIa	TYPE IIIb	TYPE IV
				

Table 2: Bismuth classification of malignant biliary strictures

S.No.	Features	Right-sided puncture	Left-sided puncture
1	Patient comfort	Painful, restricted patient movement.	Less painful, Increased patient comfort.
2	Technical ease of puncture	Difficult	Easy
3	Associated risk	Pleural transgression, injury to intercostal neurovascular bundle	-
4	Radiation exposure	Less radiation to operator	Higher radiation exposure to operator's hands
5	Preferred duct	Anterior sectoral duct	Segment three duct- antero-inferior to segment two duct.
6	Puncture site	Below 10th rib at mid-axillary line	Subxiphoid or substernal.
7	Imaging guidance for puncture	Blind puncture with fluoroscopic guidance	Ultrasonographic guidance

Table 3: Comparison of Right sided and Left sided puncture in PTBD

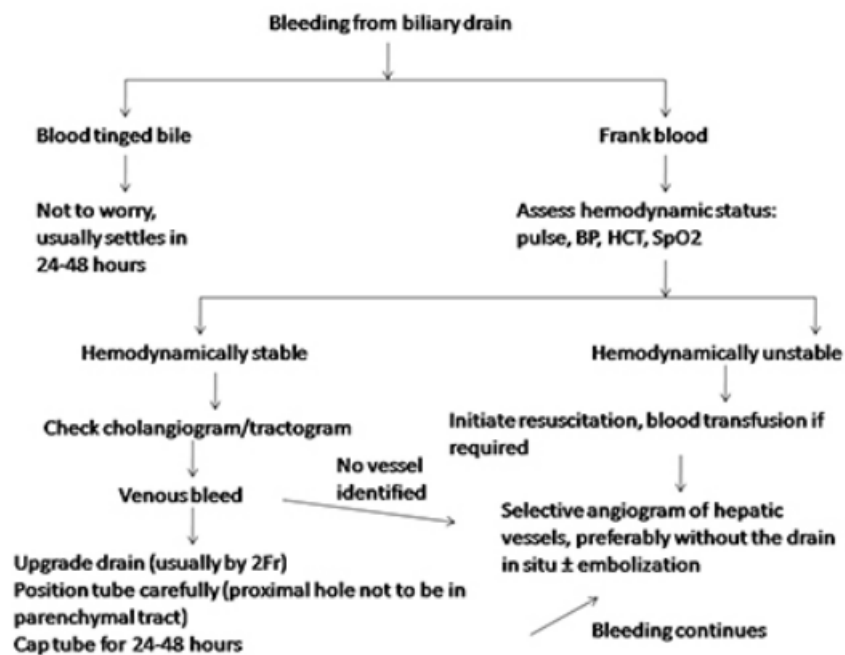


Chart 1: Algorithm for management of bleeding during PTBD

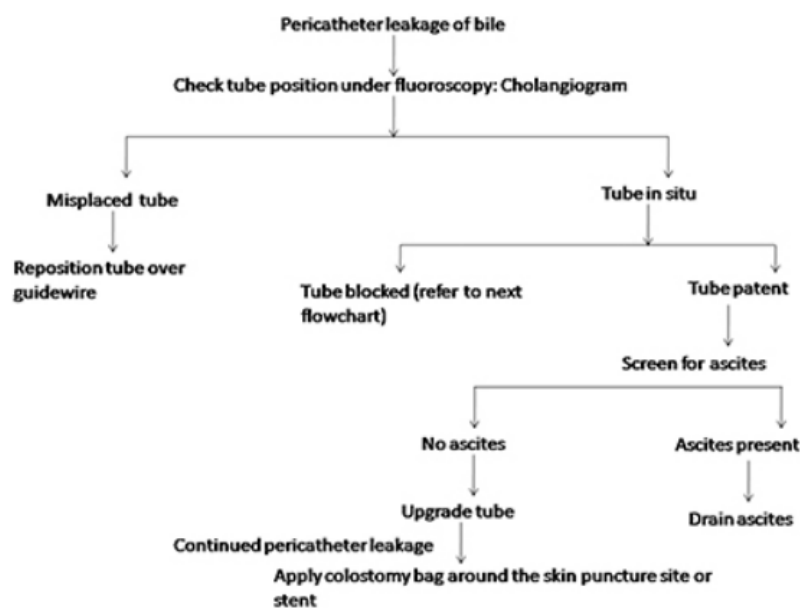


Chart 2: Algorithm for management of pericatheter biliary leakage

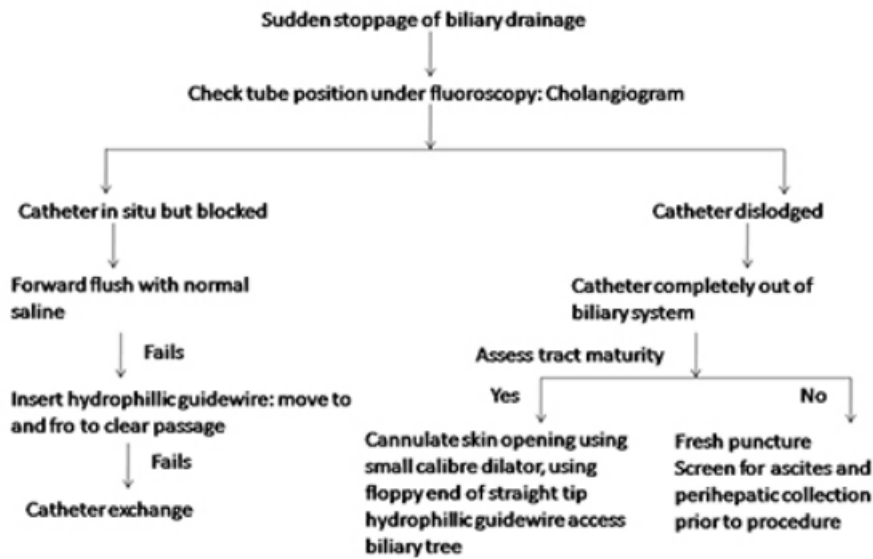


Chart 3: Algorithm for management of sudden stoppage of biliary drainage

Feature	Side-by-side	Stent-in-stent	Side-to-end
Number of percutaneous access	Bilateral	Unilateral (T configuration, obtuse angle between RHD and LHD) ; Bilateral (Y configuration, acute angle between RHD and LHD); Two unilateral or bilateral (criss-cross configuration, RASD separated from RPSD);	Unilateral or bilateral
Placement of stent	Parallel configuration	Second stent inserted via mesh of first stent into CBD	Second stent inserted overlapping with proximal edge of first stent
Advantage	Technically simple	Uniform dilatation of entire stricture within single calibre Overlapping stent prevent displacement	No manipulation through mesh of first stent
Disadvantage	Bilateral skin puncture, Overdistention of CBD, Inadequate stem expansion at hilum	Technically difficult to negotiate with closed-cell design of first stent; Crushing of first stem during deployment of second stent	In unilateral access, dilatation of percutaneous route to accommodate parallel two-stent delivery system. No stent overlap-risk of stent separation

Table 4: Comparison of techniques of multiple biliary stent placement

Characteristic	Suprapapillary	Transpapillary
Level of occlusion	Proximal or mid CBD occlusion Bile duct angulation away from stricture.	Distal CBD occlusion Bile duct angulation below the stricture
Cause of stent blockage	Tumour in-or overgrowth	Sludge incrustation
Risk of pancreatitis	-	+
Other complications	Exaggeration of distal CBD angulation if close to the end of stents leading to poor drainage	Duodenal ulceration/bleeding/perforation Reflux of duodenal contents into bile duct

Table 5: Comparison of suprapapillary and Transpapillary method of Stent placement

Pattern of bile duct involvement among the patients of our study

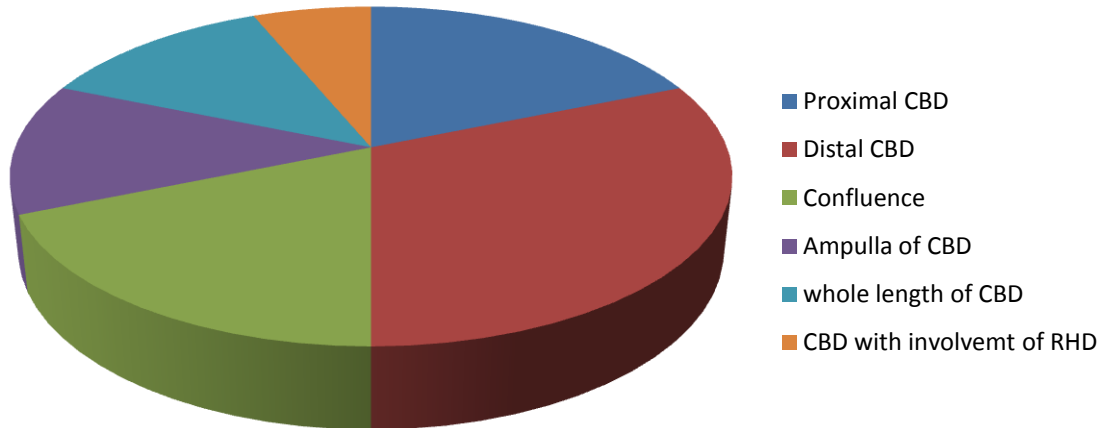


Chart 4: Pattern of bile duct involvement among the patients of our study

Etiological factors of biliary stricture among the patients of our study

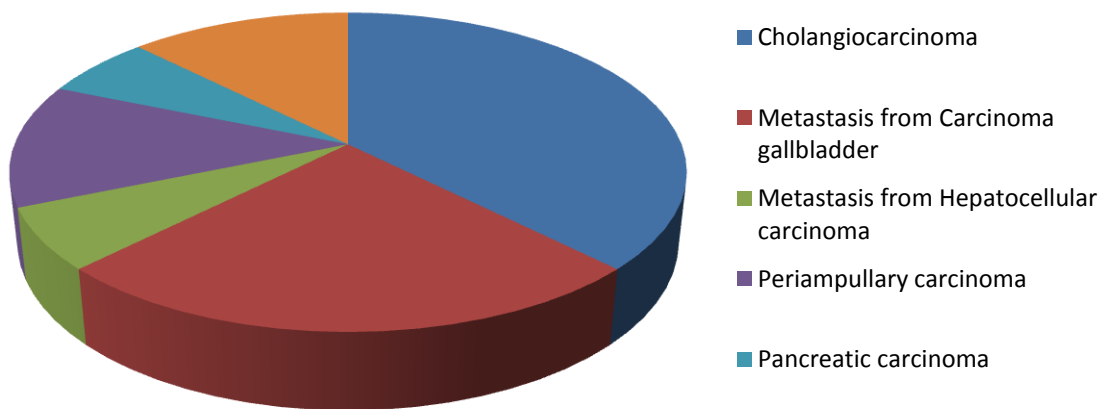


Chart 5: Etiological factors of biliary stricture among the patients of our study

Dr. Prithvijit Chakraborty, et al. "Efficiency of Percutaneous Transhepatic Biliary Stent Implantation in Management of Obstructive Biliary Pathologies: A Study in a Tertiary Care Hospital in Eastern India." *IOSR Journal of Dental and Medical Sciences (IOSR-JDMS)*, 19(4), 2020, pp. 01-10.