

## The Radiological Spectrum of Common Orbital Pathologies with Clinicopathological Correlation

Dr Parveen Chandna<sup>1</sup>, Dr Nithin Narayanan<sup>2</sup>, Dr Aditya Duhan<sup>2</sup>, Dr Rohtas K Yadav<sup>3</sup>, Dr Yogesh Kumar<sup>2</sup>, Dr Ravi N. Karisaiyappanavar<sup>2</sup>,  
Dr Ramneet Kaur<sup>2</sup>, Dr Divya Khichi<sup>4</sup>

Senior Resident<sup>1</sup> Deptt. Of Radio-Diagnosis, Pt.B.D.Sharma PGIMS, Rohtak, Haryana

Junior Resident<sup>2</sup> Deptt. Of Radio-Diagnosis, Pt.B.D.Sharma PGIMS, Rohtak, Haryana

Director<sup>3</sup> Pt.B.D.Sharma Post Graduate Institute Of Medical Sciences, Rohtak, Haryana, India

Junior Resident<sup>4</sup> Deptt. Of Pathology, Pt.B.D.Sharma PGIMS, Rohtak, Haryana

Correspondence: Dr. Parveen Chandna

**Abstract: Background And Objectives :** In Comparison to CT, MRI provides better soft tissue contrast. It also provides superior imaging information of the intracranial structures. MRI is the advanced imaging of choice for evaluation of the optic nerve, other cranial nerves, and intracranial lesions. The choice of imaging of the orbits at the crucial initial stage depends on the clinical derivation. CT is oftenly suggested for trauma, for evaluation of the bony orbits or calcified lesions, especially when MRI is contraindicated.

**Material and Methods:** To demonstrate usefulness of Toshiba lightning aquilion 16 slice multi detector computerized tomography (MDCT) scan in diagnosis of the common orbital pathologies and to assess the severity of the disease.

To demonstrate usefulness of nova gradient 1.5 T philips magnetic resonance imaging (MRI) scan in diagnosis of the common orbital pathologies and assessment of the normal structures of orbit with pathological abnormalities.

After taking a brief note of properly informed written consent and complete history, thorough clinical examination was done and these patients were subjected to CT scan and MRI scan.

**Discussion And Conclusion :** CT imaging can be promptly completed and requires minimal involvement of the patient cooperation. Therefore, found to be logical for imaging orbital trauma. The advances of multidetector CT technology has resulted in high-resolution CT imaging. The source images could be well oriented in different planes, subjugated with high-resolution isotropic imaging.

Date of Submission: 01-01-2020

Date of Acceptance: 16-01-2020

### I. Introduction

It may be helpful to cite some clinical scenarios with regards to their own differential presentation. Air may also exist within a wood fragment. Due to the afore said defect, unusual air pockets should be evaluated meticulously. Histologically the lacrimal gland is analogous to the minor salivary gland in particular spaces of the head and neck. Therefore, these share pathologic processes in particular. Differential diagnosis of an extraconal lesion can be further reaffirmed and determined when found in close association of the lacrimal gland and apparatus. A more characteristic approach for differential diagnosis is associated with a compartmental approach. Most lacrimal gland tumors are epithelial cell tumors, with half of these being benign mixed tumors and half carcinomas. CTA enables good visualisation of the major vascular anatomy in the orbits. Moreover, to the ophthalmic artery and superior ophthalmic vein, their branches, tributaries, and many other smaller vessels are generally detected and visualised. A common type of orbital fracture is "blowout" fracture, due to increase in intraorbital pressure transmitted to the orbital walls secondary to blunt trauma. Wood reflects in the form of hypodense, isodense, or hyperdense.

Evaluation for foreign bodies is best judged with thin-section CT. Wood fragments pose a serious threat to CT evaluation due to their variable densities subject to variations in hydration. The first established is lesions of the lacrimal gland and apparatus. Lacrimal lesions are benign inflammatory processes in general, with tumors being least common. Under compelling abnormal circumstances wooden and organic foreign bodies may be better evaluated with MRI.

Exophthalmos is abnormal prominence of the globe while Proptosis is an abnormal protrusion of the globe. Orbital diseases can be best recognised on the basis of their pathophysiology: trauma, vascular lesions,

infection, degenerative conditions, noninfectious inflammation, congenital and developmental abnormalities and neoplasm.

When it is quite pertinent to assess intracranial abnormalities, in the form of direct extension of orbital lesions or in association with lesions in peculiar diseases, MRI gives better details as compared to CT. Intravenous contrast is generally employed in the evaluation of neoplastic, inflammatory, infectious, and vascular orbital diseases. For determination of vascular lesions, a bolus injection is the basic need for better visualization of its arterial blood supply. A large number of disease processes persistently invade the orbits, and get associated with orbital complaints such as orbital pain, ophthalmoplegia, proptosis and visual loss are nonspecific. Complementary role has now been established jointly with CT and MRI in orbital imaging. For certain applications, MRI is more preferred due to absence of radiation risks and its unique quality of soft tissue contrast. MRI of the orbits should be executed with the help of head coil. Intravenous gadolinium (Gd) contrast is oftenly used.

These screening examinations are oftenly carried out as per the standard head or maxillofacial CT protocols. When orbital varix is to be involved, the CT study should be devised with or without the Valsalva maneuver. Enlargement of a lesion with the Valsalva maneuver is further indicative of an orbital varix. Least concerned, cavernous hemangiomas get enlarge with the Valsalva maneuver. In non cooperative patients, similar results can be achieved by positioning the patient prone during scanning.<sup>1</sup>

When orbital CT is done with more devotion, then thin sections (usually < 3 mm and preferably < 1.5 mm) have to be obtained. To differentiate diagnosis, localization of a lesion in the extraconal space versus the intraconal space can also be achieved through management implications. In particular, intraconal lesions may require surgical attention, whilst extraconal lesions may ensure medical management.

This plane is quite necessary to pin point for assessing spread of unwanted accessories from adjoining structures. As a usual practice, imaging can be done in the plane parallel to the infraorbital-meatal line. Coronal images should not be excluded from the routine protocol and the same can be achieved by multiplanar reformation. This can be well executed in the exact plane perpendicular to the axial plane. Parasagittal reformation in the exact plane parallel to the long axis of the optic nerve can also be included. Fat suppression is generally required and exercised with standard frequency selective presaturation radiofrequency (RF) pulses. Alternative advanced fat-suppression techniques yield abundant fat suppression in detrimental conditions due to magnetic field inhomogeneity.

For high-spatial-resolution imaging of the anterior orbital structures, special orbital surface coils have been found to be quite useful. However, the sensitivity of routine imaging, the field of view should not exclude the optic chiasm, optic tracts, cavernous sinus, and radiations, and the nuclei of the oculomotor, trochlear and abducens nerves in the midbrain and pons. The fat suppression for fluid-sensitive imaging can also be carried out in an effective manner with employment of inversion recovery.<sup>4,5</sup>

To get assured with the exact procedure, a line connecting the most distal tips of the lateral orbital walls is drawn. The distance from the anterior margin of the globe to this line should be less than 21 mm.<sup>8</sup>

Orbital MRI is more prone to image artifacts due to crucial factors. The protocol should not exclude T1- and T2-weighted imaging in axial and coronal planes. First, chemical shift artifacts can be visualized at the interface of the orbital fat and the globe. Similar artifacts may appear due to persistent use of silicone oil to fill the globe while treating the retinal detachment. For dedicated orbital imaging, fat suppression is generally done for T2-weighted imaging and post-Gd imaging to avoid obscuration of enhancing lesions by the high intraorbital fat signal. These chemical shift artifacts can also be curtailed by using fat or silicone saturation, using a higher gradient strength, or diminishing the bandwidth. Second, the proximity of orbital structures to the air cavities of paranasal sinuses envisages orbital imaging highly prone to image artifacts. To reduce motion of the globe, a patient is required to fix his or her vision at an illustrative object when the eyes are kept open. Temporal averaging can also be streamlined. The most prevalent traumatic injury is fracture of the orbital walls. Least concerned, perforation and penetrating injury, globe rupture, hemorrhage in the globe and contusion or avulsion of the optic nerve sheath may occur.

MR dacryocystography can be executed in a similar fashion as done in CT dacryocystography, by cannulation and instillation of Gd contrast material into the nasolacrimal duct. Thus comparable sensitivity to CT dacryocystography is finally established.<sup>6,7</sup>

Exogenous metallic materials (e.g., cosmetics) may also generate susceptibility artifacts. Third, motion artifacts can also be well visualised. Axial images at the level of lens are best for evaluating proptosis on imaging. Unique distinguishing characteristics of an orbital lesion can be implemented to assess and review a differential diagnosis. These include its location, anatomic structure, and imaging features and the clinical presentation of the patient. Employing a compartmental wise source a lesion is first established in one of the four compartments: optic nerve-sheath complex, globe, extraconal space or intraconal space. Inferior blowout fracture explicitly involves the infraorbital foramen, which is the most feeble site of the orbital floor. Viral adenitis is the most prevalent acute process. Some chronic inflammatory processes include Wegener's

granulomatosis, sarcoidosis, and Sjögren's syndrome. Lymphoma pervades commonly at the lacrimal gland fossa. The study is also based on a CT angiographic study of the head and neck bolus injection of iodinated contrast is essential to achieve the desired result. It is more pertinent to employ a view field wide enough to include extraocular pathology that may be consonance with the vascular orbital lesions, such as carotid-cavernous fistula.<sup>2</sup>

Intraorbital soft tissue contents may escape and extrude through the fracture. Muscle entrapment is the most common complication of orbital fractures. Due to obvious reasons a few lesions may spread their tentacles in more than one compartment. To the best concerned this compartmental approach assists to simplify the diagnostic skill. Frankly speaking the optic nerve-sheath complex is also an intraconal structure. Blowout fractures generally involve the inferior and medial walls due to lack of specified thickening. Once the primary location of a lesion is established then other distinguished imaging features (e.g., characteristics of margin, enhancement patterns and associated bony changes), age of presentation, pathophysiologic basis, and chronicity can be well visualised to further curtail the differential diagnosis. The presence of calcification may eventually help in reaffirming the differential diagnosis, with regards to globe lesions.<sup>9,10,11,12,13</sup>

## II. Material and Methods:

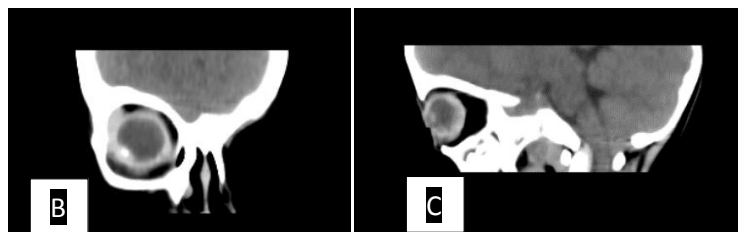
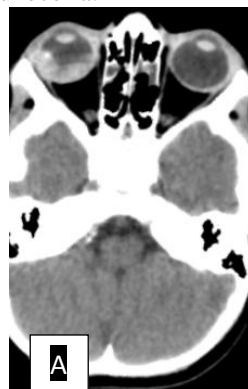The study had been carried out in the Department of Radiodiagnosis, PGIMS , Rohtak for a period of 6 months from July 2019 to December 2019. In this method potential possibility has been explored confirming through cumulative observational study in which we evaluated 100 patients suspected of having common orbital pathologies based on clinical findings.

- To demonstrate usefulness of Toshiba lightning aquilion 16 slice multi detector computerized tomography (MDCT) scan in diagnosis of the common orbital pathologies and to assess the severity of the disease.
- To demonstrate usefulness of nova gradient 1.5 T philips magnetic resonance imaging (MRI) scan in diagnosis of the common orbital pathologies and assessment of the normal structures of orbit with pathological abnormalities.
- After taking a brief note of properly informed written consent and complete history, thorough clinical examination was done and these patients were subjected to CT scan and MRI scan.

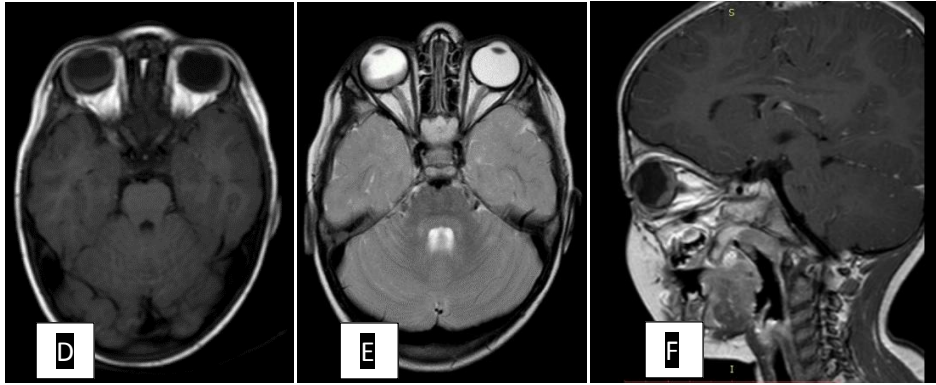
## III. Results

### Case Report 1

A 3 years old female child presented with leukocoria.



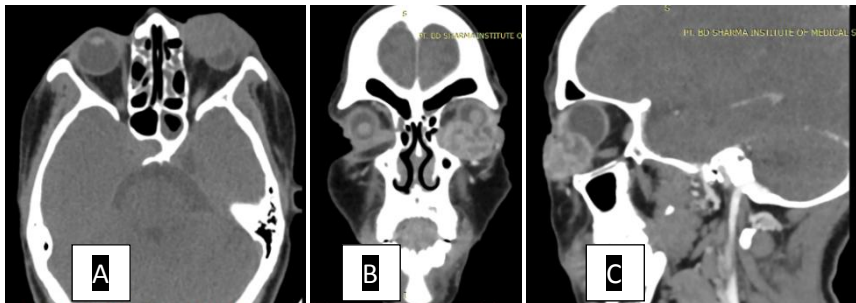
**FIG. 1 (A), (B) and (C)** shows CT images reveal hyperdense lesion with calcification inside the globe.



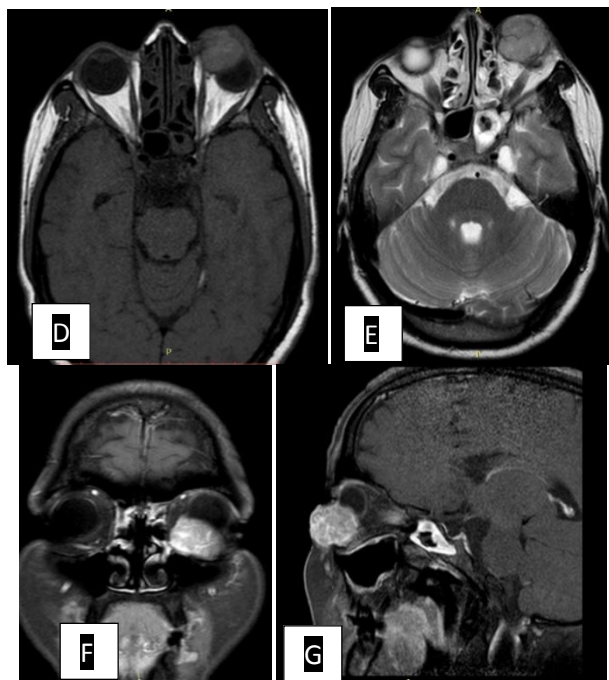
**RETINOBLASTOMA** :FIG. 1 (D), (E) & (F) MRI Images demonstrate that the lesion is hyperintense on T1W images, hypointense on T2W images with homogeneous enhancement on gadolinium administration. Enucleation of the patient was done and the lesion was histopathologically proven as retinoblastoma.

**Case Report 2**

A 45 years old female patient who was previously operated for left-sided conjunctival melanosis presented with growth over the left lower lid.

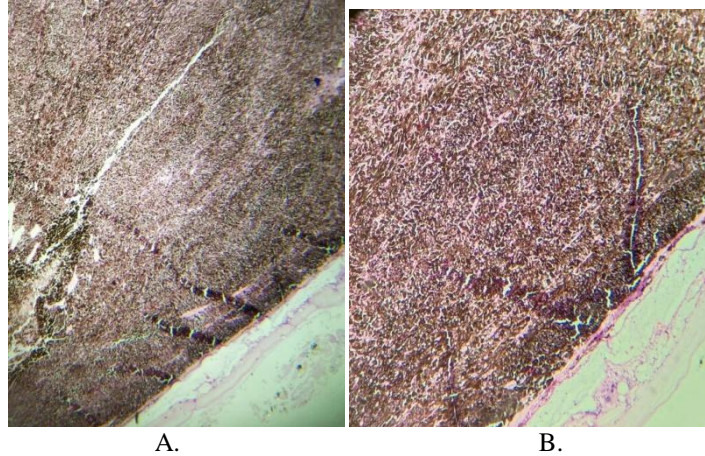


**FIG. 2** (A), (B) & (C) shows an ill-defined heterogeneously enhancing soft tissue lesion in the left lower eyelid with extraconal and globe involvement with loss of interface.



**MALIGNANT MELANOMA** :FIG. 2 (D-G) MRI Images demonstrate iso to hyperintense lobulated mass lesion on T1W and slightly hyperintense on T2W imaging with intense contrast enhancement on post gadolinium.

On excision biopsy, histopathologically proven to be malignant melanoma.



PHOTOMICROGRAPH :( HEMATOXYLIN AND EOSIN STAIN )

Case Report 3

A 65 years old male patient presented with complaints of bilateral sided proptosis.

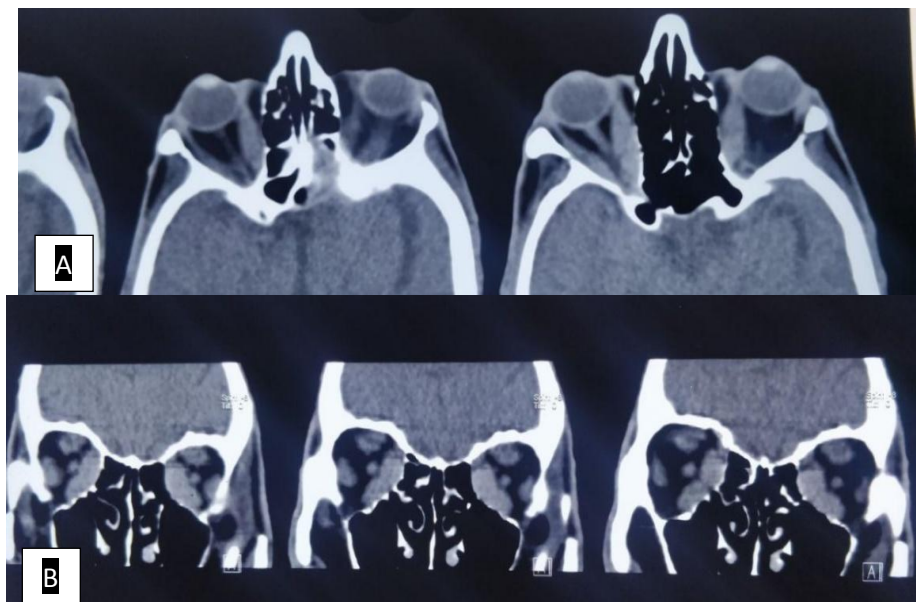
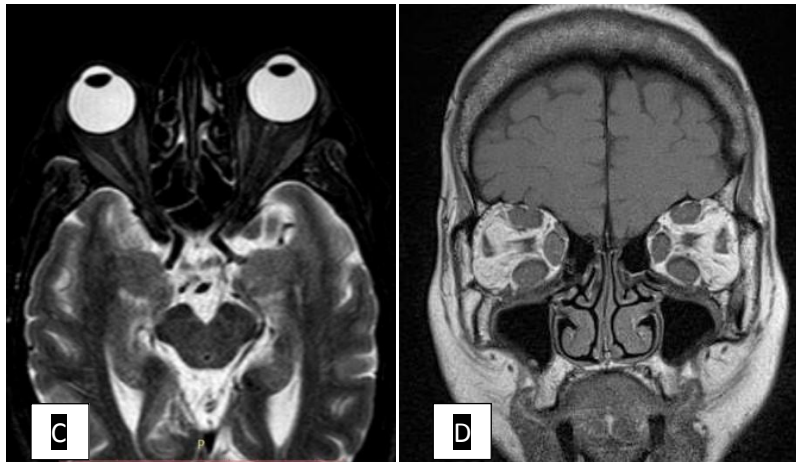


FIG. 3 (A) and (B) shows axial and coronal CT images demonstrating enlargement of the bilateral medial and inferior rectus muscle.

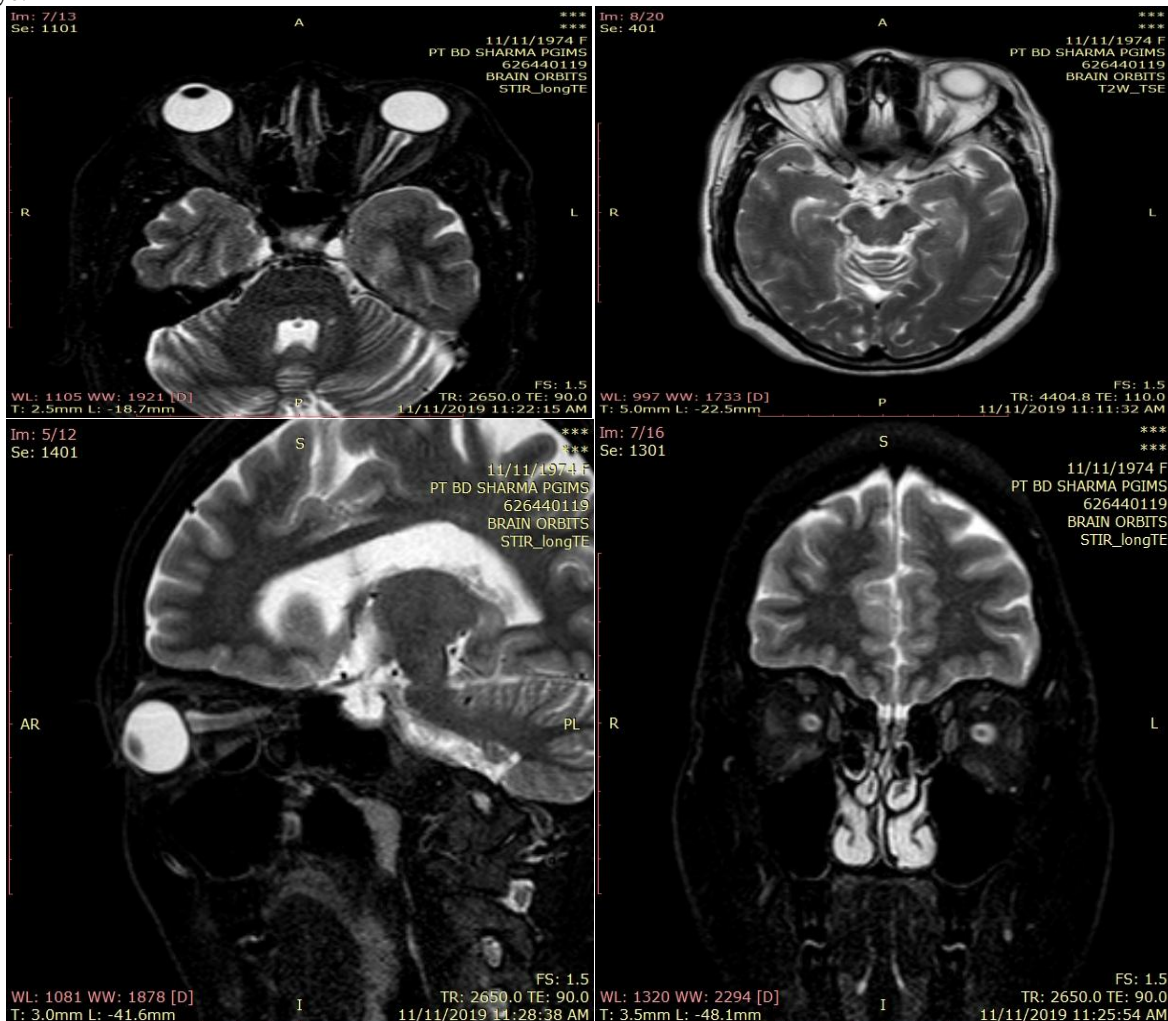


**THYROID ORBITOPATHY :**FIG.3 (C) & (D) reveals axial T2W image showing sparing of anterior tendon insertion and coronal T1W showing bulky medial and inferior rectus muscle.

The patient was given corticosteroid therapy and was on follow-up.

Case Report 4

A 45 year old female patient presented to eye OPD complaining of severe headache, nausea and vomiting since 16 days. Fundoscopy examination revealed optic disc edema. She had been overweight with BMI(Body Mass Index) of 33 kg/m<sup>2</sup>. Snellan visual acuity had curtailed to 6/18 in the left eye 6/12 in the right eye.



**PAPILLOEDEMA**- MRI images reveal mild bulging of optic discs with flattening of posterior part of globe. B/L perioptic CSF sheath appears prominent.  
When measuring 8mm from the globe on CT ( Normal maximum optic nerve sheath diameter is 5.8mm)

#### **IV. Discussion and Conclusion**

The major modalities for imaging the orbits have been described CT and MRI. The advances of multidetector CT technology has resulted in high-resolution CT imaging. The orbits have been generally included in routine CT head or maxillofacial CT examinations. A typical orbital CT protocol can be achieved with scanning in the axial plane. This plane is oftenly taken into consideration to be parallel to the orbital long axis. CT is the imaging method of choice for assessing and determining of orbital trauma.

More quantities of intraorbital fat yields exact intrinsic soft tissue contrast on CT for most clinical derivations. The source images could be well oriented in different planes, subjugated with high-resolution isotropic imaging. This technique has an advantage over multiplanar capability of MRI obsolete. Therefore, CT has an edge over MRI due to unique characteristic of high resolution isotropic imaging. It requires minimum imaging time and is therefore not much sensitive to movement of the globe and eyelid. As a matter of fact CT dacryocystograms can be employed by administration of contrast material into the nasolacrimal duct to determine the patency accurately. This requires cannulation of the lacrimal duct, for this purpose an ophthalmologist needs cannulation of the lacrimal duct.<sup>3</sup>

#### **Acknowledgement:**

No words can ever express my deep sense of gratitude for my parents & my younger brother, for their affections, endurance, inspiration, support, unending blessings, innumerable sacrifices and unceasing encouragement that has moulded me into the person i am today. The expression of my gratitude's will remain incomplete if i fail to register my deep sense of indebtness to my family members without whose perseverance and affection it would have not been possible for me to undertake this arduous assignment.

Funding : No funding sources.

Conflict of interest: None declared.

Ethical approval: The study was approved by the Institutional Ethics Committee.

#### **Bibliography:**

- [1]. Font RL, Patipa M, Rosenbaum PS, et al: Correlation of computed tomographic and histopathologic features in malignant transformation of benign mixed tumor of lacrimal gland. *Surv Ophthalmol* 34(6):449–452, 1990.
- [2]. Valvassori GE: Imaging of orbital lymphoproliferative disorders. *Radiol Clin North Am* 37:135–150, 1999.
- [3]. Ansari SA, Pak J, Shields M: Pathology and imaging of the lacrimal drainage system. *Neuroimaging Clin N Am* 15:221–237, 2005.
- [4]. Del Grande F, Santini F, Herzka DA, et al: Fat suppression techniques for 3-T MR imaging of the musculoskeletal system. *Radiographics* 34(1):217–233, 2014.
- [5]. Johnson G, Miller DM, MacManus D, et al: STIR sequences in NMR imaging of the optic nerve. *Neuroradiology* 29:238–245, 1987.
- [6]. Herrick RC, Hayman LA, Taber KH, et al: Artifacts and pitfalls in MR imaging of the orbit: A clinical review. *Radiographics* 17:707–724, 1997.
- [7]. 617. Manfre L, de Maria M, Mangiameli A, et al: MR dacrocystography: Comparison with dacrocystography and CT dacrocystography. *AJNR Am J Neuroradiol* 21(6):1145–1150, 2000.
- [8]. Hilal SK, Trokel SL: Computerized tomography of the orbit using thin sections. *Semin Roentgenol* 12:137–147, 1977.
- [9]. Harnsberger HR: Handbook of head and neck imaging, ed 2, St. Louis, 1995, Mosby.
- [10]. Koeller KK, Smirniotopoulos G: Orbital masses. *Semin Ultrasound CT MR* 19:272–291, 1998.
- [11]. Koornneef L, Zonneveld F: The role of direct multiplanar high resolution CT in the assessment and management of orbital trauma. *Radiol Clin North Am* 25:753–766, 1987.
- [12]. Kubal WS: The pathological globe: Clinical and imaging analysis. *Semin Ultrasound CT MR* 18:423–436, 1997.
- [13]. Rothfus WE, Kapoor V: Orbital masses, schemata for differential diagnosis. In Latchaw RE, Kucharczyk J, Moseley ME, editors: *Imaging of the nervous system—Diagnostic and therapeutic applications*, St. Louis, 2005, Mosby, pp 1007–1031.

Dr. Parveen Chandna, et al. "The Radiological Spectrum of Common Orbital Pathologies with Clinicopathological Correlation". *IOSR Journal of Dental and Medical Sciences (IOSR-JDMS)*, 19(1), 2020, pp. 53-59.