

Hemisection: A Conservative Approach for Treatment of Grossly Decayed Tooth

Nimmy S Mukundan¹, Prasanth Balan², Jayasree S³, Muhammed Abdul Rahman TV⁴, Sruthi Poornima E⁵, Rinku B⁶

¹⁻⁶(Department of Conservative Dentistry and Endodontics, Govt. Dental College, Calicut)

Corresponding Author: Nimmy S Mukundan

Abstract: Untreated dental caries or periodontal disease eventually leads to loss of tooth. Hemisection helps in retaining grossly decayed or periodontally involved tooth which otherwise should be extracted. In this paper we describe a case of grossly decayed mandibular molar managed conservatively with hemisection and prosthetic rehabilitation.

Key Word: Hemisection, Dental caries, Periodontal disease, Root canal therapy

Date of Submission: 06-01-2020

Date of Acceptance: 21-01-2020

I. Introduction

Attempts to save existing natural tooth dates back to more than a century and now the dentistry has advanced enough to retain a well functioning dentition for a lifetime¹. Although loss of anterior tooth is more of patient concern on an aesthetic view point, loss of posterior tooth is eventful often leading to drifting of adjacent tooth, loss of arch length and loss of masticatory function. This often necessitates subsequent preventive and corrective measures.

Advanced periodontal disease and gross destruction of tooth structure due to caries are the most common reason for extraction. High predictability and success rate of endodontic therapy and periodontal treatment now gave us the means to save more of such teeth or atleast a part of it. Hemisection followed by prosthetic rehabilitation may be considered as an alternative to extraction for mandibular molars with furcation involvement or gross destruction of one root. Hemisection refers to vertically cutting the tooth into half and removing the pathologically involved root and associated crown². This helps in retaining healthy portion of tooth along with restoration of function.

This paper describes a case of grossly decayed distal root of mandibular first molar which was successfully treated by hemisection. Root canal therapy of involved tooth was done initially followed by hemisection of distal root. After healing of the surgical site, fixed prosthesis was given to restore the function.

II. Case Report

A 30 years old female patient reported to department of conservative dentistry and endodontics with complains of pain on lower right back tooth region. On examination right mandibular first molar was grossly decayed and it was sensitive to percussion. Gross destruction of distal root with furcation involvement and periapical radiolucency was evident in the radiograph (fig.1). A comprehensive treatment planning was made which consist of endodontic treatment with hemisection of distal root and fixed partial denture involving mandibular second molar and retained mesial half of first molar. The treatment plan was discussed with the patient and consent was obtained. After local anesthesia (2% lignocaine with adrenalin 1:80000), access opening was done with endo access bur (Dentsply maillifer). Working length was determined with electronic apex locator (Apex Id SybronEndo) and confirmed with radiograph (fig.2). Biomechanical preparation was done with protaper next file (Dentsply maillifer) and obturated with lateral condensation of gutta percha and calcium hydroxide sealer (Sealapex, SybronEndo)(fig.3). Post endodontic restoration was done with silver amalgam. Intentional root canal treatment of mandibular second molar also done in the same appointment. Patient recalled for hemisection after one week.

In the next appointment, after local anesthesia, an envelope type flap was reflected to facilitate easy extraction of distal root. A long fissure bur was used to cut the tooth through furcation area upto the level of alveolar bone with copious saline irrigation. The distal root was extracted with root forceps (fig.4) and the flap closed with simple interrupted suture. The overhanging restoration and dentin were contoured with fine diamond points. (fig.5)

At the next appointment after 2 weeks, crown preparation was done for fixed partial denture involving mandibular second molar and retained mesial half of first molar. A poly vinyl siloxane putty light body

impression was made for metal ceramic restoration and teeth were temporized. Later after 3 days, prosthesis was cemented with glass ionomer cement (fig.6). On recall after 6 months, patient was symptom free and radiograph showed complete healing of the site (fig.7).

III. Discussion

Conventional treatment option for grossly decayed teeth is mainly extraction and prosthetic rehabilitation or root canal treatment with post and core. When one root is not salvageable due to extensive tooth structure loss or due to periodontal reason, hemisection can be considered as a viable option^{3,4,5}. The term hemisection is derived from Greek word hemi, which means half and a Latin word sect, denotes cut¹. Hemisection refers to vertically cutting the tooth into half and removing the pathologically involved root and associated crown. Hemisection helps the mandibular molar to retain as a premolar which occludes with maxillary molar and prevent its supraeruption².

Mesial root of mandibular molar has more surface area and so more stable periodontally⁶, but distal concavity makes it difficult to restore and maintain hygiene by brushing and flossing². So usually distal root is retained as it is broader and straighter which can better act as an abutment⁶. But in this case, the mesial root of mandibular first molar was retained and the distal root was resected as it was grossly destroyed by caries.

Nowadays implant has been a predictable choice to treat non restorable tooth⁷. But patient was in favor of hemisection because of higher cost of implant and her desire to retain existing natural tooth as much as possible. The prognosis of root resection procedures ranges from 62% to 100 % with an overall success of 88%². Eventhough Buhler found 32% failures in hemisection procedures, other studies have shown higher success rate in a long term observation⁸⁻¹¹.

IV. Conclusion

Hemisection may be considered as an alternative to extraction of periodontally or endodontically compromised tooth to retain its function. However the success of hemisection depends on many factors including oral hygiene of the patient, bone support and restorative treatment.

References

- [1]. Kost WJ, Stakiw JE. Root amputation and hemisection. *J Can Dent Assoc* 1991; 57(1):42-5.
- [2]. Ingle, J. I., Bakland, L. K., Baumgartner, J. C., & Ingle, J. I. (2008). *Ingle's endodontics 6*. Hamilton, Ontario: BC Decker
- [3]. Saad MN, Moreno J, Crawford C. Hemisection as an alternative treatment for decayed multirooted terminal abutment: A case report. *J Can Dent Assoc* 2009;75:387-90.
- [4]. Shafiq MK, Javaid A, Asaad S. Hemisection: An option to treat apically fractured and dislodged part of a mesial root of a molar. *J Pak Dent Assoc* 2011;20:183-6.
- [5]. Shah S, Modi B, Desai K, Duseja S. Hemisection – A conservative approach for a periodontally compromised tooth – A case report. *J Adv Oral Res* 2012;3:31-5.
- [6]. Anderson, Ronald & McGarrah, Helen & Lamb, Robert & Eick, J.. (1983). Root Surface Measurements of Mandibular Molars Using Stereophotogrammetry. *Journal of the American Dental Association* (1939). 107. 613-5. 10.14219/jada.archive.1983.0294.
- [7]. Bashutski JD, Wang HL. Common implant esthetic complications. *Implant Dent* 2007; 16(4):340-8.8
- [8]. Weine FS. Root amputation. In: *Endodontic Therapy*. 6th ed. Osaka: Mosby- Year Book, Inc.; 2004. p. 606-39
- [9]. Shah S, Modi B, Desai K, Duseja S. Hemisection – A conservative approach for a periodontally compromised tooth – A case report. *J Adv Oral Res* 2012;3:31-5.
- [10]. Mishra P, Sharma A, Mishra SK. Hemisection: A conservative approach of tooth preservation. *J Curr Res Sci Med* 2016;2:46-8.
- [11]. Park JB. Hemisection of teeth with questionable prognosis. Report of a case with seven-year results. *J Int Acad Periodontol* 2009;11:214-9.

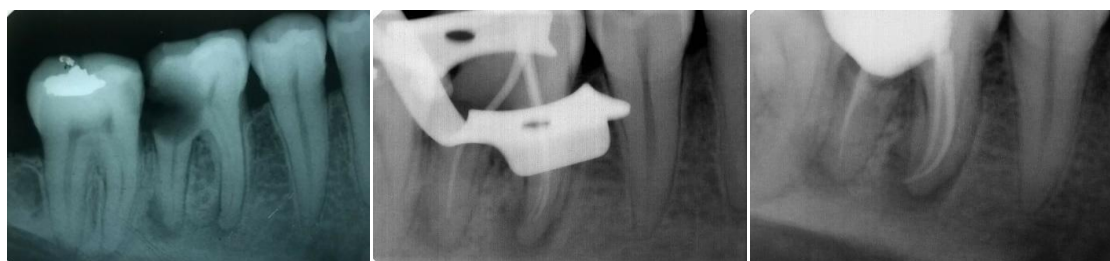

Figure 1: Pre operative radiograph **Figure 2:** Master cone radiograph **Figure 3:** Post obturation radiograph

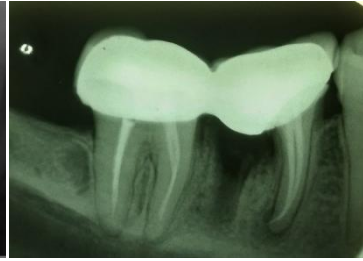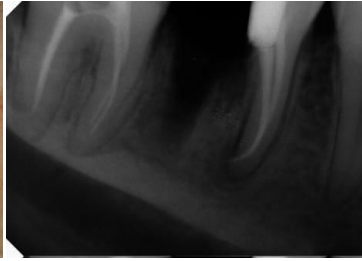

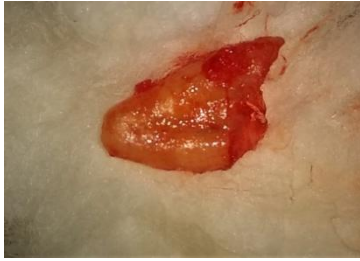
Figure 4: Extracted distal root **Figure 5:** Radiograph after hemisection ceramic bridge cementation **Figure 6:** Radiograph after metal

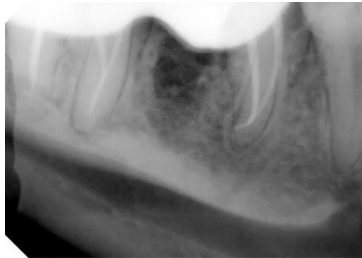


Figure 7: radiograph after 6 months showing complete healing

Nimmy S Mukundan, et.al. "Hemisection: A Conservative Approach for Treatment of Grossly Decayed Tooth" *IOSR Journal of Dental and Medical Sciences (IOSR-JDMS)*, 19(1), 2020, pp. 38-40.