

Foreign Bodies In Aerodigestive Tract: An Experience At A Tertiary-Care Hospital

Dr Sumeet Mahajan¹, Dr Amit Manhas², Dr Sachin Gupta³,
Dr Parmod Kalsotra⁴.

^{1.} Senior Resident, Department of ENT&HNS, Govt. Medical College, Jammu.

^{2.} Lecturer, Department of Anaesthesia, Govt Medical College, Jammu

^{3.} Asstt. Professor, Department of ENT&HNS, ASCOMS Jammu.

^{4.} Professor, Department of ENT&HNS, Govt. Medical College, Jammu.

Corresponding author: Dr Sumeet Mahajan

Abstract: Aerodigestive tract foreign bodies are commonly seen in children or in elderly age group, making its management a challenge for the otolaryngologist. In our study, a review of 160 patients was done who presented with history of accidental ingestion/inhalation of foreign body to the Department of ENT, Govt. Medical College Jammu. The aim of the study was to find the age and sex distribution of aerodigestive tract foreign bodies, their site of impaction, nature and different procedures done for their removal. In our study, it was found that out of 160 aerodigestive tract foreign bodies, 120(75%) were in digestive tract and 40(25%) were in the airway. Majority of the digestive tract foreign bodies (72 cases, 60%) were in the age group of 0 – 10 years while majority of the airway foreign bodies (30 cases, 75%) were in the age group of 0 – 5 years. Coin (63 cases, 52.5%) was the commonest foreign body ingested where as Out of 40 airway foreign bodies, 30 (75%) were of organic nature and 10(25%) were inorganic. Peanut(9,30%) was the most common organic foreign body inhaled. Cricopharynx (80 cases,66.6%) was the most common site of foreign body lodgement in the digestive tract while Right main bronchus (26 cases, 65%) was the commonest site of lodgement of inhaled foreign body. All the aerodigestive tract foreign bodies were successfully removed by hypopharyngoscopy/ esophagoscopy/ rigid bronchoscopy depending on the site of lodgement under general anesthesia.

Keywords: foreign body, rigid, esophagoscopy, bronchoscopy

Date Of Submission: 20-09-2018

Date of acceptance: 08-10-2018

I. Introduction

Aerodigestive tract foreign bodies pose a significant challenge to the otolaryngologist. Commonest type of foreign body varies from region to region, however coin ingestion seems to be the commonest worldwide problem(1,2,3) while seeds and nuts are frequent causes of tracheobronchial obstruction worldwide. Foreign bodies in air passage are commonly seen in younger children while foreign bodies in food passage are encountered in children and adults alike. Children younger than 5 years of age represent the highest risk group. Both sites share a common feature of increased morbidity and mortality but foreign bodies in tracheobronchial area poses additional diagnostic problem which is all the more so in radiolucent foreign bodies. It is important to develop a comprehensive approach to the early recognition and timely management of aspirated and ingested foreign bodies, as complications from delayed diagnosis can have significant health implications. Serious complications from aspirated foreign bodies such as severe airway obstruction and death, tend to occur in infants and younger children due to the small size of their airways.

Chevalier Jackson's initial description of endoscopic removal of foreign bodies in 1936 revolutionised the treatment options for management of aerodigestive foreign bodies(4,5). Associated developments in radiology have played an important role in the rationalized and safe management of these cases.

Aims and Objectives:

- 1.To study the age and sex distribution of aerodigestive tract foreign bodies.
2. To study the nature and site of lodgement of aerodigestive tract foreign bodies
3. To study the procedures done for removal of aerodigestive tract foreign bodies.

II. Materials and Methods

This retrospective study was conducted in the Department of Otorhinolaryngology, Govt. Medical college, Jammu for a period of one year from August 2017 to August 2018 on 160 patients diagnosed as a case of foreign body in digestive or airway tract on the basis of detailed history, physical examination and necessary

investigations. X-Ray chest A/P and lateral view were resorted for confirming foreign body in air passage and X-Ray Neck A/P and lateral view was done in all patients of foreign body in food passage. In no patient, CT Scan was required to be done. Faucial (oropharyngeal) foreign bodies were removed as an OPD procedure while depending on the site of foreign body, we resorted to various procedures like hypopharyngoscopy, esophagoscopy and bronchoscopy for retrieval of foreign body. Patients were observed for 24 hours postoperative for any complications.

III. Results

Age and sex distribution

A total of 160 patients were studied. The youngest patient was 9 months old while the oldest was 64 years. 99 (61.87%) were males and 61(38.13%) were females. Out of 160 patients, 120(75%) were having foreign bodies in the digestive tract while 40 patients (25%) were having airway foreign bodies. The maximum patients with digestive tract foreign bodies (72, 60%) were in the age group of 0 – 10 years and the maximum patients with foreign bodies in the airways (30, 75%) were in the age group of 0 – 5 years. Out of 120 cases of foreign bodies in the digestive tract, 75(62.5%) were males and 45(37.5%) were females and out of 40 cases of foreign bodies in the airway, 24(60%) were males and 16(40%) were females. The age and sex distribution of these aerodigestive tract foreign bodies are shown in table 1 and 2.

Age group	Number of cases(%)	Males (%)	Females (%)
0 – 10	72(60)	46(61.3)	26(57.8)
10-20	17(14.2)	10(13.3)	7 (15.5)
20-30	11(9.2)	6 (8)	5 (11.1)
30-40	10(8.3)	6 (8)	4 (8.9)
40-50	5 (4.2)	3 (4)	2 (4.4)
50-60	3 (2.5)	3 (4)	
60-70	2 (1.6)	1 (1.3)	1 (2.2)
Total	120 (100)	75	45

Table 1 showing the age and sex distribution of digestive tract foreign bodies.

Age group	Number of cases(%)	Males (%)	Females(%)
0 – 5	30(75)	18(75)	12 (75)
5-10	5(12.5)	3(12.5)	2 (12.5)
10-15	3(7.5)	1(4.2)	2 (12.5)
15-20			
>20	2(5%)	2(8.3)	
Total	40(100)	24(100)	16(100)

Table 2 showing the age and sex distribution of Airway foreign bodies.

Nature of Aerodigestive tract foreign bodies

Coin was the most common foreign body ingested seen in 63 patients (52.5%) followed by bonechip in 20 (16.7%), meat bolus in 10(8.3%), dentures in 8(6.6%), fish bone in 6(5%), alkaline batteries in 5(4.2%), lockets in 3(2.5%),Stainless steel Nuts in 2(1.6%), safety pin in 2(1.6%) and magnet in 1 (0.8%) patient.

out of 40 airway foreign bodies, 30(75%) were organic foreign bodies and 10(25%) were of inorganic nature. Out of 30 organic foreign bodies , peanut was the commonest inhaled foreign body (9 cases, 30%) followed by beans (7, 23.3%), peas (5, 16.7%) almond (3, 10%), maize seed (2, 6.6%), coconut piece (2, 6.6%) and walnut (2, 6.6%). The nature of aerodigestive tract foreign bodies is shown in table 3 and 4.

Nature of foreign body	Number of cases	Percentage(%)
Coin	63	52.5
Bone chip	20	16.7
Meat bolus	10	8.3
Dentures	8	6.6
Fish bone	6	5
Alkaline batteries	5	4.2
Lockets	3	2.5
Steel Nuts	2	1.6
Safety pin	2	1.6
Magnet	1	0.8
Total	120	100

Table 3 showing the nature of various digestive tract foreign bodies

Organic FB	Number of cases (%)	Inorganic FB	Number of cases(%)
Peanuts	9(30)	Pin	3(30%)
Beans	7(23.3)	Whistle	3(30%)
Peas	5(16.7)	Plastic Pen cap	2(20%)
Almond	3(10)	Bead	1(10)
Maize	2(6.6)	Denture	1(10)
Coconut piece	2(6.6)		
Walnut	2(6.6)		
Total	30(100)		10(100)

Table 4 showing the nature of various airway foreign bodies.

Site of impaction : Out of 120 digestive tract foreign bodies, 80 (66.7%) were observed in cricopharynx followed by upper esophagus 22 (18.3%), mid esophagus 7 (5.8%), lower esophagus 5 (4.2%), tonsillar pillars and fossa 3 (2.5%), pyriform fossa 2 (1.7%) and base of tongue (1,0.8%).

Out of 40 patients with airway foreign bodies, 26 (65%) were having foreign body in right main bronchus followed by 8 (20%) in the left main bronchus, 2 (5%) in trachea, 2 (5%) in larynx and 2 (5%) in right secondary bronchus. The various sites of impaction of aerodigestive tract foreign bodies is shown in table 5 and 6.

Site of impaction	Number of cases	Percentage (%)
Base of Tongue	1	0.8
Tonsillar pillar / fossa	3	2.5
Pyriform fossa	2	1.7
Posterior Pharyngeal wall		
Cricopharynx	80	66.7
Esophagus	34	28.3
Total	120	100

Table 5 showing the site of impaction of various digestive tract foreign bodies

Site of impaction	Number of cases	Percentage (%)
Larynx	2	5
Trachea	2	5
Right main bronchus	26	65
Left main bronchus	8	20
Right sec. bronchus	2	5
Left sec. bronchus		
Total	40	100

Table 6 showing site of impaction of various airway foreign bodies.

Operative procedures : Out of 120 digestive tract foreign bodies, 82 were removed by hypopharyngoscopy, 34 by rigid esophagoscopy and 4 foreign bodies were removed as an OPD procedure. There was no intra/postoperative complication.

Out of 40 airway foreign bodies, 36 foreign bodies were removed by rigid bronchoscopy and in 4 patients, tracheostomy was done along with rigid bronchoscopy. out of 40 patients who underwent bronchoscopy, 2 patients develop postoperative bronchospasm which was managed with nebulization and steroids and shifted to pediatric ICU and recovered after 2-3 days. Various operative procedures done and their outcome is shown in table 7.

Procedure	No. of cases	FB removed	Complication
Hypopharyngoscopy	82	82	0
Esophagoscopy	34	34	0
Bronchoscopy	36	36	1
Bronchoscopy + Tracheostomy	4	4	1
Total Operative cases.	156	156	2

Table7 showing various procedures done for the removal of aerodigestive foreign bodies and their complications.

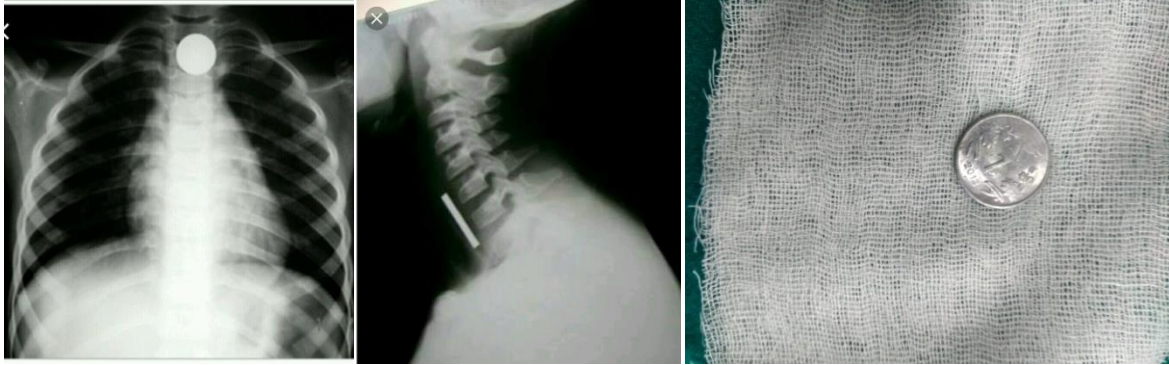


Figure 1 shows Xray Neck /chest A/P and Lateral view showing coin at the level of cricopharynx along with removed coin.

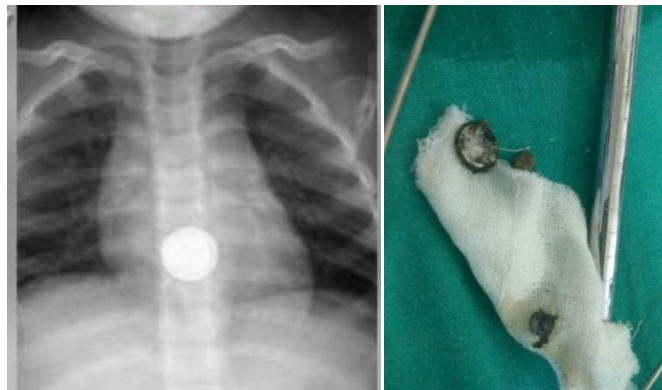

Figure 2 : Xray chest A/P view showing alkaline battery cell in mid oesophagus along with removed foreign body.

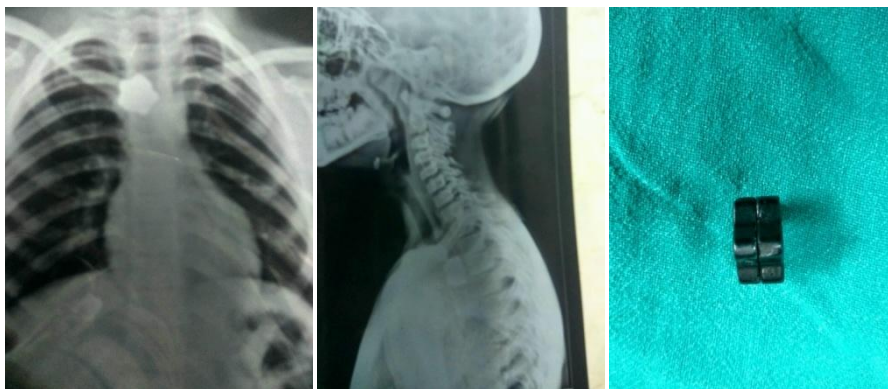

Figure 3: Xray Neck and chest A/P and lateral view showing magnet in upper esophagus along with the removed magnet.

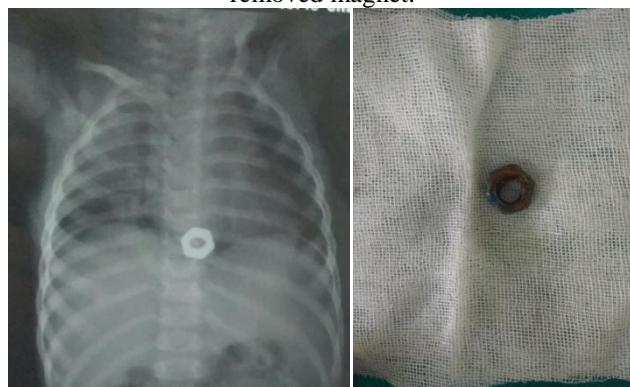

Figure 4: Xray Neck/chest and abdomen A/P view showing stainless steel Nut in the lower esophagus along with the removed Nut.

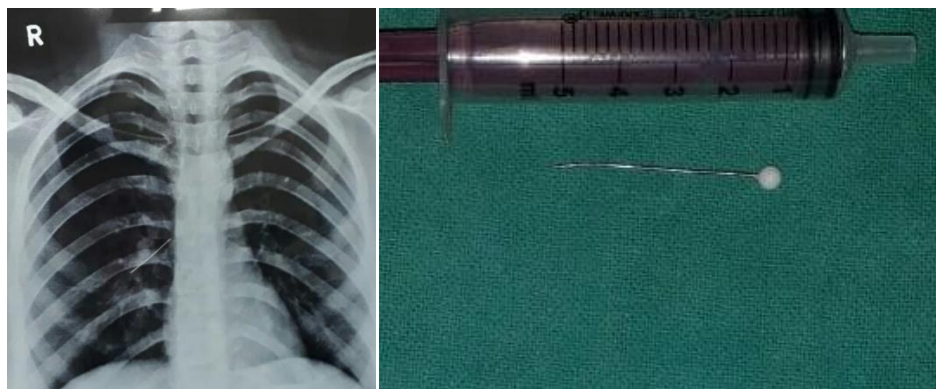


Figure 5 : Xray chest P/A view showing Pin in the right bronchus along with the removed pin

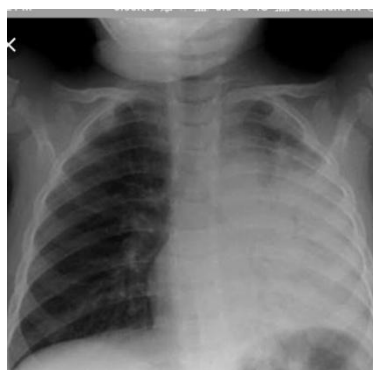

Figure 6 : Xray chest P/A view showing left middle and lower lobe atelectasis due to impacted groundnut in the left bronchus.

IV. Discussion

Management of aerodigestive tract foreign body patients was revolutionized by the technique and instruments developed by Chevalier Jackson in 1904. The mortality decreased from more than 20% to 2% (6). Out of 160 patients with aerodigestive tract foreign bodies , 120(75%) had digestive tract foreign bodies while 40(25%) had foreign body in the airways. In their study, Hung and Lin (7) found 76% and 24% foreign bodies in food passage and air passage while Brooks (8) found them to be 80% and 20% respectively.

Among the cases of foreign bodies in the food passage, the age ranged from 1 to 70 years. The most common age group in our study was 1 – 10 years with 60% of patients. Most foreign bodies in food passage are ingested by children younger than 5 years with the peak incidence between 6 months to 3 years as a sequel to natural proclivity to put things in their mouth (9,10,11). Banerjee et al (12) and Rothman et al (13) also found that the highest incidences of foreign body ingestion and aspiration were in children below 3 years of age. Since these children lack molar teeth, edibles placed in the mouth are usually broken up but not chewed which they easily ingest aspirate, especially if the child is running, playing or talking. This age group may also be involved due to immature coordination in the swallowing mechanism. In the study done by Steven C (14), the average age of patients with aerodigestive tract foreign body was 3 years. Out of 160 patients with aerodigestive tract foreign bodies, 99 were males and 61 were females and the male-female ratio (M:F)=1.6:1 which was in accordance with other studies(15).

Digestive tract foreign bodies were located at cricopharynx in 80 (66.6%) out of 120 patients. This is owing to poor peristalsis, sphincteric action and narrow diameter of cricopharynx. In one large series(6), 50.5% of foreign bodies in food passage were seen in cricopharynx, thus supporting our observation. Similarly in yet another study (16) , 83.5% of foreign bodies were located at cricopharynx. We observed coins (63,52.5%) to be the commonest type of foreign body in the food passage. This was in accordance with the study done by Khan MA et al (17) who found that coin was the most common foreign body in aerodigestive tract.

Out of 40 patients with airway foreign bodies, 26(65%) were having foreign body in the right main bronchus while 8 (20%) were having foreign body in the left main bronchus. This was in accordance with the study done by Murthy PSN(18) and Zerella et al (19) who found the most common site of impaction of foreign body in the airway is right bronchus. This right sided predominance can be explained by the vertical alignment of the right main bronchus, its large diameter, the greater airflow through it and the localization of the carina to the left of the midline of trachea.(20) In our study, majority of the airway foreign bodies were vegetable

foreign bodies (30, 75%) with peanut, being the most common. This was in accordance with the study done by Bhalodiya et al (21) who found vegetable foreign bodies, mostly groundnut in 38 of 42 patients.

In our study, all the digestive tract foreign bodies were removed successfully with hypopharyngoscopy and rigid esophagoscopy without any complications. All the airway foreign bodies were removed with rigid bronchoscopy. Tracheostomy was done in 4(10%) patients. Most of these tracheostomies were emergencies as patients presented with severe respiratory distress with foreign bodies in glottis/subglottis area.

V. Conclusion

Foreign bodies in the digestive tract can be seen at any age while tracheobronchial foreign bodies are mainly seen in children. Rigid endoscopy with forceps removal under general anesthesia is the treatment of choice for these foreign bodies. Hypopharyngoscopy is the most common procedure done to remove digestive foreign bodies as cricopharynx is the most common site of lodgement of such foreign bodies. A definitive or suspicious history of foreign body inhalation should be the most important factor in deciding for rigid bronchoscopy in patients with normal auscultatory and/ X ray chest findings at the time of presentation. Delay in diagnosis and management can lead to life threatening complications.

References

- [1]. Uba AF, Adeyemo AO, Adejuyigbe O. Management of esophageal foreign body in children. East African Medical Journal 2002; 79(6):334-8
- [2]. Diaz GA, Valledo L, Seda F. Foreign bodies from the upper aerodigestive tract of children in Puerto Rico. Bol Asoc Med PR, 2000;92(9-12):124-9
- [3]. Mahafza TM. Extracting coins from the upper end of the esophagus using a Magill forceps technique. Int J Pediatr Otorhinolaryngology 2002;62(1):37-9
- [4]. Jackson C, Jackson CL. Diseases of the air and food passages of foreign body origin. 1st ed. Philadelphia: Saunders, 1936:1-635.
- [5]. Boyd AD. Chevalier Jackson: the father of American bronchoesophagoscopy. Ann Thorac Surg 1994; 57(2):502-5
- [6]. Kamat P, Bhojwani KM, Prasannaraj T, Abhijith K. Foreign bodies in aerodigestive tract- A clinical study of cases in the coastal area. Am J Otolaryngol 2006;27(6):373-7
- [7]. Hung W, Lin PJ. Foreign bodies in the air and food passages. Am Arch Otolaryngol 1953;67:603-12
- [8]. Brooks JW. Foreign bodies in the air and food passages. Ann Surg 1972;175(5):720-32
- [9]. Bizakis JG, Prokopakis EP, Papadakis CE, Skoulakis CE, Velegrakis GA, Heledonis ES. The challenge of esophagoscopy in infants with open safety pin in the esophagus. Report of two cases. Am J Otolaryngol 2000;21(4):255-8
- [10]. Karaman A, Cavusoglu YH, Karaman I, Erdogan D, Aslan MK, Cakmak O. Magill forceps technique for removal of safety pins in upper esophagus. A preliminary report. Int J Pediatr Otorhinolaryngol 2004;68(9):1189-91
- [11]. Sarihan H, Kaklikkaya I, Ozcan F. Pediatric safety pin ingestion. J Cardiovasc Surg (Torino) 1998;39:515-18
- [12]. Banerjee A, Rao KS, Khanna SK, Narayanan PS, Gupta BK, Sehar JC, et al. Laryngotracheobronchial foreign bodies in children. J Laryngol Otol 1988;102:1029-32
- [13]. Rothman BF, Boeckmann CR. Foreign bodies in the larynx and tracheobronchial tree in children: a review of 225 cases. Ann Otol Rhinol Laryngol 1980; 89:434-6
- [14]. Stevens C, Ardagh M, Abbott GD. Aerodigestive tract foreign bodies in children. One years experience at Christ church hospital emergency department. N Z Med J 1996;109(1024):232-3
- [15]. Sehgal A, Singh V, Chandra J, Mathur NN. Foreign body aspirations. Indian Pediatr J 2002;39:1006-10
- [16]. Shivkumar AM, Naik AS, Prashanth KB, Hongal GF, Chaturvedi G. Foreign body in upper digestive tract. Indian J Otolaryngol Head Neck Surg 2006;58:163-8
- [17]. Khan MA, Hameed A, Choudhary AJ. Management of foreign bodies in the esophagus. J Coll Physicians Surg Pak. 2004 Apr;14(4):213-20
- [18]. Murthy PSN, Vijendra S, Ramakrishna S, Fahim A Shah, Varghese Philip. Foreign bodies in the upper aerodigestive tract. SQU J Scient Res Med Sci. 2001;3(2):117-20
- [19]. Zerella JT, Dimler M, Mc Gill LC, Pippus KJ. Foreign body aspiration in children: value of radiology and complications of bronchoscopy. Pediatr Surg 1998;33:1651-4
- [20]. Ramos MB, Fernandez-Villar, Fivo JE, Leiro V, Garcifontan E, Bontana MI, et al. Extraction of airway foreign bodies in adults: experience from 1987-2008. Interact Cardiovasc Thorac Surg 2009; 9(3):402-5
- [21]. Bhalodiya N, Supriya M, Patel S. Foreign body inhalation in children: Decisive factors for carrying out bronchoscopy. Indian J Otolaryngol Head Neck Surg 2006;58(4):337-9.

Dr Sumeet Mahajan, " Foreign Bodies In Aerodigestive Tract: An Experience At A Tertiary-Care Hospital.. "IOSR Journal of Dental and Medical Sciences (IOSR-JDMS), vol. 17, no. 10, 2018, pp 82-87.