

A Case Report of Protein Kinase Amp Activated Non Catalytic Subunit Gamma 2 Syndrome (Prkag2 Syndrome)

¹Henry A Mayala, ²Gowreesunkur B Hrkeshsing, ³Deq M Shire, ⁴Pedro Pallangyo, ⁵Khamis Bakari, ⁶Semvua Kilonzo, ⁷Wahida Shokat Kara, ⁸Wang Zhao Hui

Tongji Medical College Of Huazhong University Of Science And Technology, Department Of Cardiology, Wuhan Union Hospital

Abstract

Background: PRKAG2 syndrome is a rare, early onset autosomal dominant inherited disease, characterized by ventricular pre-excitation, supraventricular arrhythmias, and cardiac hypertrophy. In cardiomyocytes the enzyme regulates the glucose and fatty acids uptake, storage and utilization.¹

Case report: We present a 44years old female patient, who came to Wuhan Union hospital with the following presenting complains, chest pain, awareness of heart beat and dizziness for 3 weeks, she denies history of hypertension and diabetes mellitus, she has a strong family history of heart diseases where two nephews were diagnosed of Hypertrophic Cardiomyopathy and one niece was diagnosed of having PSVT-WPW and a cousin with bradycardia. Clinical history and ECG and ECHO findings are suggestive of PRKAG2.

Conclusion: Even though PRKAG2 syndrome has an early onset, our patient presented with symptoms at 44 years making it important because even though its rare may also present at late stage of life.

Keywords: PRKAG2- protein kinase amp activated non catalytic subunit gamma 2, HCM- hypertrophic Cardiomyopathy, ECG-electrocardiogram, ECHO-Echocardiogram, PSVT-paroxysmal Supraventricular tachycardia, WPW- wolf Parkinson white syndrome, RBBB-right bundle branch block

I. Introduction

PRKAG2 syndrome is a rare, early onset autosomal dominant inherited disease, characterized by ventricular pre-excitation, supraventricular arrhythmias, and cardiac hypertrophy. It is frequently accompanied by chronotropic incompetence and advanced heart blocks, leading to premature pacemaker implantation.¹ The prevalence of PS is currently unknown. AMPK is a highly conserved serine/threonine protein kinase responsible for cellular energetic homeostasis control. Stimulated by high AMP concentration and AMPK kinase activity, the enzyme counterbalances ATP depletion. It is composed of a catalytic α subunit and 2 non catalytic, but regulatory subunits β and γ . γ_2 regulatory subunit of AMPK (PRKAG2) binds AMP, enhancing the activation of α -subunit. AMPK is highly expressed in Cardiac tissue, skeletal muscle, brain, placenta, liver, kidneys and pancreas. In cardiomyocytes the enzyme regulates the glucose and fatty acids uptake, storage and utilization.^{1,2}

³The most common electrocardiographic features of PRKAG2 syndrome are; short PR interval, bundle branch block mainly RBBB, sometimes CBBB, high voltage QRS complexes with secondary repolarization abnormalities frequently developed even without echocardiographic evidence of LVH. Furthermore the other feature of cardiac hypertrophy mainly involves the left ventricle and it is often progressive and associated with both diastolic and systolic heart failure. The maximal ventricular wall thickness varies widely from normal values to a mean of 24mm. The PRKAG2 syndrome clinical manifestations include; supraventricular tachyarrhythmias (SVT) which are mainly presented by atrial fibrillation and atrial flutter. SVT have been frequently the first clinical sign in patients with PRKAG2 syndrome. The other clinical manifestations are; conduction system dysfunction and chronotropic incompetence, heart failure and sudden cardiac death.^{1,2}

II. Case Presentation

We present a 44years old female patient, who came to Wuhan Union hospital with the following presenting complains, chest pain, awareness of heart beat and dizziness for 3 weeks, she denies history of hypertension and diabetes mellitus, she has a strong family history of heart diseases(4 family members) where two nephews were diagnosed of Hypertrophic Cardiomyopathy and one niece was diagnosed of having PSVT,WPW-had a radio frequency ablation and a cousin with bradycardia on physical examination she was conscious, not pale, not jaundiced, not dyspneic, vital signs BP=115/80mmhg, HR= 200b/min regular, full volume, strong character. Several investigations were done, Thyroid function test, renal function test, liver function test, CBC, cardiac profile, PT, PT, INR lipid profile were normal, BNP is slightly elevated 107.8pg/ml.

Chest X-ray was normal, Echo revealed interventricular septum thickening. ECG revealed atrial flutter with Right bundle branch block and high voltage QRS, genetic testing was done and confirmed the diagnosis.

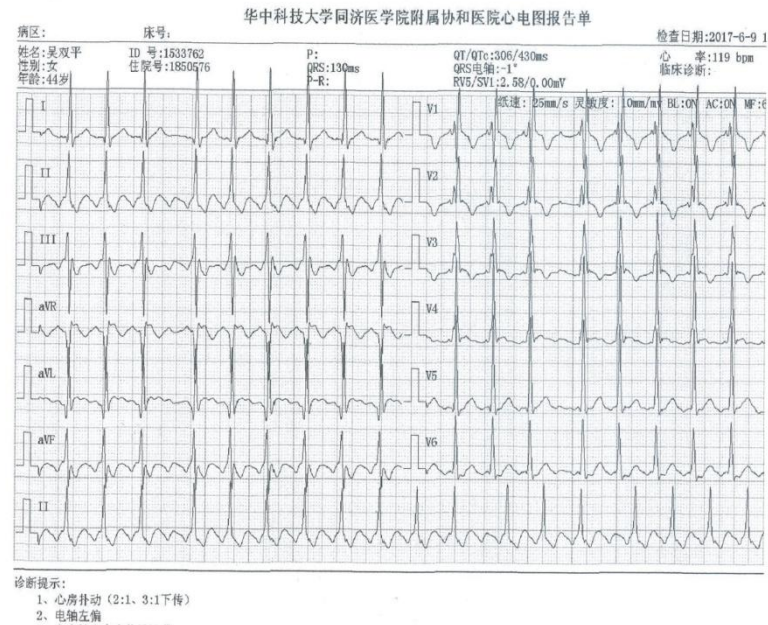


Figure: 1 ECG showing atrial flutter with Right bundle branch block and high voltage QRS

III. Discussion

According to our patient she presented with ECG characteristics of atrial flutter and RBBB , echo revealing Thickened IVS also with a positive family history and positive genetic testing for PRKAG2 syndrome, even though PRKAG2 has early onset but our patient was asymptomatic for most of her life but did present with all classical features of PRKAG2, whereby our patient presented with ECG characteristics of atrial flutter, RBBB and high voltage QRS complexes, Thickened IVS on Echo and a strong family history of heart diseases with 2 nephews with HCM, a niece with PSVT and a cousin with bradycardia. Our patient had EPS and radiofrequency ablation was done to cardiovert and was successful, and kept on Diltiazem and Metoprolol currently our patient has no complains.

References

- [1]. Andrea G Porto, et al. Clinical Spectrum of PRKAG2 syndrome. *Circulation Arrhythmia Electrophysiology*. 2016;9:c003121.DOI:10.1161/CIRCEP.115.003121
- [2]. Lev M, et al. Anatomic findings in a case of ventricular pre-excitation terminating in complete AV block. *Circulation*. 1966;34:718-733
- [3]. Zaha V YL. Amp-activated protein kinase regulation and biological actions in the heart. *Circulation Research*. 2012;111:800-814
- [4]. Gulotta SJ et al. Familial occurrence of sinus bradycardia, short PR interval, intraventricular conduction defects, recurrent supraventricular tachycardia, and cardiomegaly. *American Heart Journal*. 1977;93:19-29
- [5]. Laforet P, et al. A new mutation in PRKAG2 gene causing hypertrophic Cardiomyopathy with conduction system disease and muscular glycogenosis. *Neuromuscular disorder* 2006;16:178-182.doi:10.1016/j.nmd.2005.12.004
- [6]. Enrinco Fabris, et al. Cardiac hypertrophy, accessory pathway, and conduction system disease in an adolescent (The PRKAG2 cardiac syndrome). *Journal of American college of cardiology*. Vol.62, No.9, 2013
- [7]. Ntobeko Ntusi, et al. Clinical features spectrum of causal genetic mutations and outcome of hypertrophic Cardiomyopathy in South Africans. *Cardiovascular journal of Africa* 2016;27:152-158
- [8]. Kun-Qi Yang, et al. A novel PRKAG2 mutation in a Chinese family with cardiac hypertrophy and ventricular pre-excitation. www.nature.com/scientificreports
- [9]. J. Travis Hinson, et al. integrative analysis of PRKAG2 Cardiomyopathy iPSC microtissue models identifies AMPK as a regulator of metabolism, survival and fibrosis. *Cell Report journal* 2016; 17(12):3292-3304. doi:10.1016/j.celrep.2016.11.066.
- [10]. Krikler DM, et al. Sudden death in hypertrophic Cardiomyopathy: associated accessory atrioventricular pathways. *British heart journal*.1980;43:245-251
- [11]. Weidemann F, et al. The Fabry Cardiomyopathy: models for the cardiologist. *Annual Review Medicine*.2011;62:59-67