

## Tubo Ovarian Mass in Reproductive Age Group-Chronic Ectopic Pregnancy –Late Presentation, a Case Report

Dr. Nasiya Mohamad Ac<sup>1</sup>, Dr. Neeraja .S<sup>2</sup>, Dr .K .Saraswathi<sup>3</sup>

<sup>1</sup>Postgraduate, Dept of Obstetrics and Gynecology, Sree Balaji Medical College & Hospital, Chennai, India.

<sup>2</sup>Assistant Professor Sree Balaji Medical College & Hospital, Chennai, India.

<sup>3</sup>Head of the department, SBMCH

**Abstract:** This is an unusual case of chronic ectopic pregnancy which presented very late. A 35-year old South Indian woman presented to our OPD in SBMCH with lower abdominal pain and irregular menstrual cycles for 1 year . Her clinical findings and supportive investigations favoured Left sided complex Tubo-Ovarian mass. She had normal beta HCG levels and CA 125 was normal. Diagnostic laparoscopy was proceeded and excision of Tubo-Ovarian mass done. The other tube and ovary were normal. Histopathology report was suggestive of Chronic Ectopic Pregnancy. Chronic Ectopic pregnancy presents diagnostic dilemmas due to lack of classic symptoms or signs and also the varied timing of presentation. A very high index of suspicion is required in all cases of Tubo-Ovarian masses

**Keywords:** chronic ectopic, Tubo ovarian mass, laparoscopy

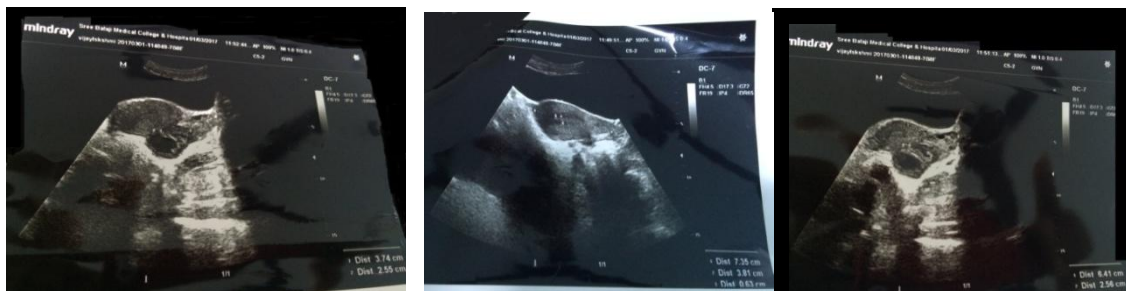### I. Introduction

Chronic ectopic pregnancy is a rare entity and as it usually presents as Tubo ovarian mass, it is never suspected clinically. The<sup>1</sup> Tubo ovarian mass in chronic ectopic pregnancy is due to the extrusion of the products of conception through the fimbria along with recurrent but small intra peritoneal bleeds which ultimately seals off resulting in an adnexal mass involving, tube, ovaries, and clots. Diagnosis is usually by histo pathology.. Just as we are taught to be ectopic minded for acute ectopic pregnancy presentations, we should also “Think Ectopic” in all complex Tubo- ovarian masses.

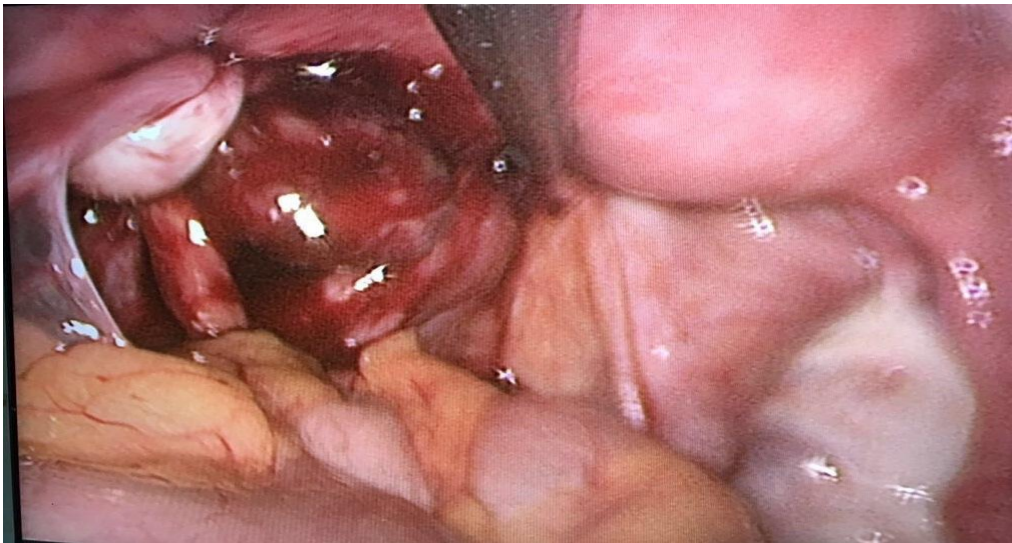
### II. Case Report

35yrs old Mrs Vijayalakshmi, married for 17 years presented to the OPD in SBMCH with complaints with irregular of left sided abdominal pain. She is a parous woman with two living children delivered normally and had one spontaneous miscarriage. Not sterilized, Last child birth was 10 years back, She presented to us with irregular menstrual cycles for about a year. LMP was two weeks ago Her detailed Obstetric history included two full term normal vaginal delivery of a female and a male child; followed by a spontaneous miscarriage. Past medical and surgical history not significant. On General examination :patient moderately built and well nourished ,hemodynamically stable, with BP;120/80mmhg, PR:80/min temp: normal, mild pallor ,nopedaledema,CVS:S1,S2+,RS::NVBS+, P/A- soft on palpation, no lump /mass palpable, P/S :cervix and vagina healthy P/V : uterus normal size ,tender mass in the left adnexal measuring 5\*6cms

Our provisional diagnosis was Tubo ovarian mass probably due to PID . Her investigations included urine beta human chorionic gonadotropin which was negative ,haemogram normal,Ca125 was normal, U/S showed Tubo ovarian mass , a thick walled tubular lesion seen adjacent to the left side measuring 4\*3 cm ,irregular mass with internal echos no septations,



Diagnostic laparoscopy was performed reddish brown mass of size 6\*3 cm size identified on the left side ,it was adherent to posterior uterine wall and pouch of douglas with minimal omental adhesion ,mass cut with bipolar ,mass removed through endobag , Complex Tubo ovarian mass removed send to histopathology .histopathology report shows chronic ectopic pregnancy



Picture shows reddish brown mass of size 6\*3cm size identified on the left side, it was adherent to posterior uterine wall and pouch of Douglas with minimal omental adhesion, mass cut with bipolar, mass removed through the endobag other side tube and ovary normal and specimen sent to histopathology, histopathology report shows chronic ectopic pregnancy

### **III. Discussion**

<sup>2</sup>Ectopic pregnancy usually has an acute presentation, which is not unusually dramatic. Acute ectopic pregnancy presents with sudden massive intra peritoneal hemorrhage due to tubal rupture rather than tubal abortion

<sup>3</sup>Chronic ectopic pregnancy usually has no classical symptoms and signs. Age risk of ectopic is 3 fold greater in women of 35-44 years as compared to 18-24 years. It is associated with pelvic inflammatory disease. When the intraperitoneal bleeding from the tube is small in amount but recurrent, as in tubal abortion, escape of blood into the peritoneal cavity leads to pelvic hematocele

<sup>4</sup>In chronic ectopic pregnancy the adnexal mass includes the products of conception which are partially extruded through the fimbria and through a partial rupture of the tube which leads to mild to moderate bleeding. The haemorrhage may get arrested and may result in an adnexal mass involving the tube, ovaries, and clots.

<sup>5</sup>Tubo ovarian mass involving the fallopian tube are related primarily to inflammatory causes like pelvic inflammatory disease. Complex inflammatory mass consists of bowel, tube and ovary and may be present without a large abscess cavity. Management should be based on the primary symptoms and may include observation with close follow up, temporizing surgical therapies and definitive surgical procedures like laparotomy or laparoscopy. For presumed benign ovarian mass operative laparoscopy is now common although complication rates are higher with complicated operative laparoscopy procedures such as those required for extensive endometriosis.

### **IV. Conclusion**

The dictum to early diagnosis and successful management in acute abdominal condition should be ectopic minded but also not to "OVER THINK ECTOPIC". Chronic ectopic pregnancy is difficult to diagnose due to its varied presentations, therefore requires a low threshold of suspicion for all Tubo ovarian (Adnexal) masses (apart from the usual differential diagnosis.)

### **References**

- [1]. jeffcoate's principles of gynecology, 7th edition jaypee brothers publishers, by prataplaumer, narendramalhotra (1,2,3,4)
- [2]. berek and novaks gynecology, 14th edition, jonathan s. berek (5)
- [3]. Williams gynecology 2<sup>nd</sup> edition, Hoffman, schorge, schaffer, hallvorson, bradshan, cunningham