

Penetrating Thigh Trauma Resulting In the Profunda Femoris Artery Pseudoaneurysm - A Case Report.

Jakub Kaczynski¹, Martin Hennessy², Emma Beveridge², Michael Yapanis¹

¹(Department of Vascular Surgery, Forth Valley Royal Hospital, Larbert, United Kingdom)

²(Department of Interventional Radiology, Forth Valley Royal Hospital, Larbert, United Kingdom)

Abstract: Pseudoaneurysms of the Profunda Femoris Artery are rare, and their clinical assessment can be challenging due to the deep anatomical location of the vessel. Thus, computed tomography angiography imaging plays a vital role in establishing the diagnosis. However, in the presented case of a young man with the Profunda Femoris Artery branch pseudoaneurysm following a penetrating lower limb trauma, computed tomographic angiography findings were unremarkable. The diagnosis was confirmed by a digital subtraction angiography. Subsequent endovascular treatment was successful, and the patient has made a satisfactory recovery. Therefore, we feel it is important to report this case that highlights key aspects regarding management of the described pseudoaneurysm.

Keywords: Profunda Femoris Artery, pseudoaneurysm, trauma, computed tomography angiography, embolisation

I. Introduction

Profunda Femoris Artery (PFA) pseudoaneurysms are rare, and their true incidence remains unknown, as the only available information comes from either small case series (femoral fractures in elderly population) or a hand full of isolated case reports [1-8]. Etiology includes traumatic (gunshot, stab, femoral fractures) or iatrogenic perforations (orthopaedic and percutaneous transluminal procedures) [1,5]. Clinical assessment of such pseudoaneurysms can be challenging as the deep anatomical location of the PFA does not produce absent distal pulses. Furthermore, in the presented case computed tomography angiography did not detect the arterial injury. Therefore, we feel it is important to report this case that highlights key aspects regarding management of the PFA pseudoaneurysm.

II. Case Report

A 22-year-old male presented to the emergency department with the right thigh swelling following a stab injury (knife). On admission, haemodynamic parameters were normal. Examination of the cardiovascular and respiratory systems was unremarkable. Abdominal examination revealed soft and non-tender abdomen. On inspection, 3cm laceration was noted on the lateral aspect of the patient's mid thigh. The wound looked clean, and there was no obvious bleeding. The anterolateral aspect of the thigh was significantly swollen and tender on palpation. All infrainguinal pulses were present. There was a full range of movement in the hip, knee and ankle joints with no sensory deficit. Blood results and chest radiograph were normal. The patient was admitted for observations and 24 hours later he developed a tense thigh swelling and was unable to perform a straight leg raise test. A plain radiograph demonstrated the presence of air within the thigh soft tissues consistent with a sustained injury. Computed tomography angiography (CTA) confirmed an extensive soft tissue gas and an intramuscular haematoma within the anterolateral thigh muscles (Fig.1). There was no evidence of any contrast extravasation. An ongoing thigh swelling prompted an urgent digital subtraction angiography (DSA), which showed pseudoaneurysm arising from the PFA branch (Fig. 2). A 5 French Destination sheath (Terumo) was placed over the aortic bifurcation via the retrograde left common femoral artery, and DSA showed pseudoaneurysm arising from the distal right PFA branch (Fig. 2). The right PFA main stem was selected using 5 French Cobra catheter, and Progreat microcatheter was used to deploy Boston Scientific VortX Diamond coils (6x 3mm and 5x 4mm) distal and proximal to the pseudoaneurysm's neck. DSA demonstrated successful exclusion of the pseudoaneurysm (Fig. 3). Unfortunately, 48 hours later the patient continued to have increasing thigh pain. Therefore, he was taken to theatre for an exploration of the thigh wound. At operation, he was found to have a large haematoma which was evacuated. There was no active bleeding, and after lavage, the wound was closed. The operation led to a resolution of the patient's symptoms. There were no complications related to the endovascular and open surgical treatments. The patient was discharged from an out-patient follow-up after a period of physiotherapy.

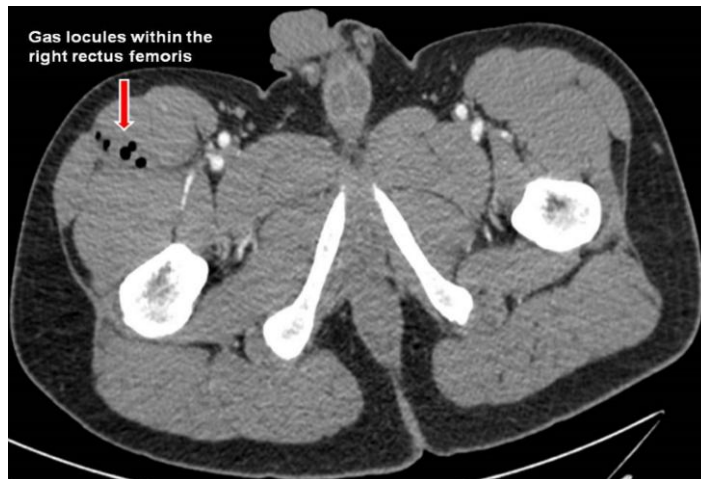


Fig 1: Gas locules within the right thigh muscles.

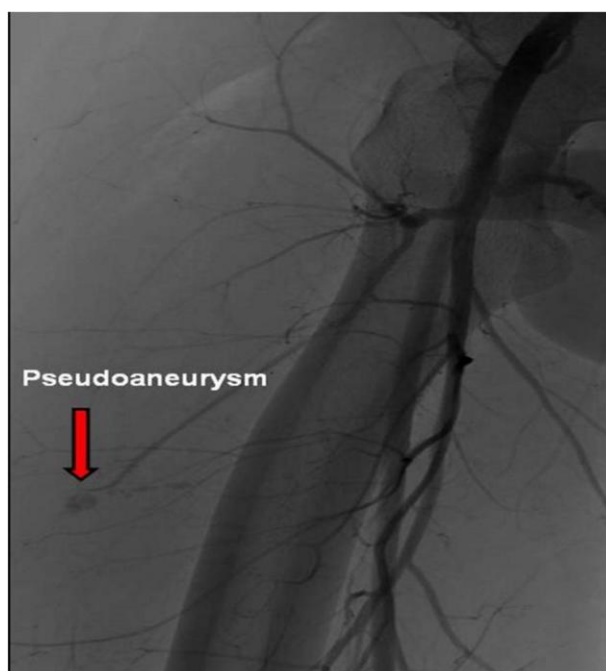


Fig 2: DSA demonstrating a pseudoaneurysm of the PFA branch.

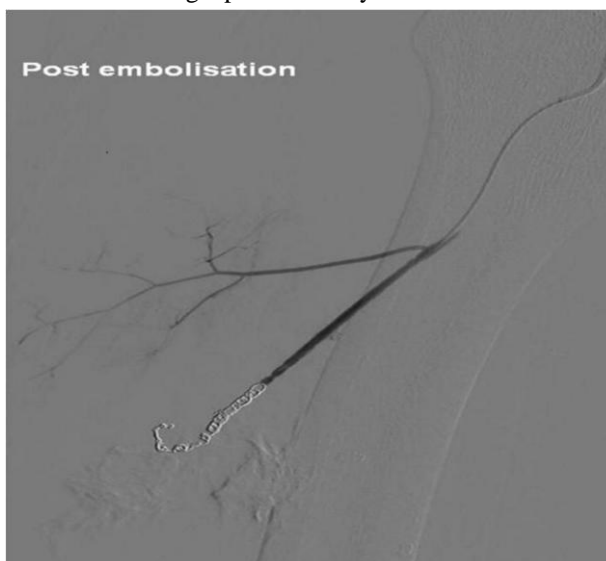

Fig 3: Successful embolisation of the PFA branch pseudoaneurysm.

III. Discussion

Pseudoaneurysms of the PFA are a rare entity that can pose diagnostic challenges owing to the deep anatomical location of the PFA. The vast majority of reported cases have traumatic etiology [1-8]. Their presentation depends on the degree of an arterial damage; therefore it can vary from hours to even years after trauma [1,6]. If a bone fragment or metal work gradually erodes an arterial wall, it allows for a slow growth of a false aneurysm and subsequent late presentation [5,9]. Clinical signs include thigh swelling, hip pain (pressure effect), anaemia, fracture non-union, neurological compromise, infection, microembolisation, arterio-venous fistulae, venous obstruction and thrombosis [1,2,5,9]. Whereas, an acute presentation caused by a rupture of the PFA false aneurysm, manifests as a haemorrhagic shock (life or limb threatening), an acute compartment syndrome, skin necrosis and distal limb embolisation [3,6,9]. However, the above mentioned reported clinical presentations may lack any ischaemic signs or symptoms unless a concomitant occlusive disease of an ipsilateral superficial femoral artery (SFA) is present [5]. Furthermore, ankle brachial pressure index is unreliable in such scenario, because of the lack of distal arterial extension of the PFA [3]. For that reason, imaging plays a vital role in establishing the diagnosis and anatomical assessment of a false aneurysm. CTA has a high sensitivity (90-95%) and specificity (98-100%) for detecting an arterial injury. However, if the flow to pseudoaneurysm is intermittent, no contrast extravasation can be detected [6]. Hence, CTA may fail to identify injured vessel as in the presented case. In such scenario, DSA is recommended, which confirms the site of an aneurysm, feeding vessels, patency of the SFA and distal arterial circulation [5,9]. A duplex ultrasound scan (DUS) is primarily used with non-invasive treatment techniques such as compression or thrombin injection.

The treatment algorithm depends on the patient's haemodynamic status, size and location of the pseudoaneurysm. Small false aneurysms can be treated with a DUS guided compression, which aims at occlusion of the neck of pseudoaneurysm [9]. However, thigh haematoma can significantly impair the accuracy of compression. In effect, a success rate of only 63% has been reported [9]. More promising results were reported with a DUS guided thrombin injection which induces thrombosis within the sac and therefore leads to the seal of the arterial wall defect [9]. This method is safe and effective with a reported success rate up to 93% [9]. Unfortunately, this treatment is suitable for superficial lesions only. Again, the presence of a large haematoma makes identification of a feeding vessel very difficult, and subsequent cannulation of deep-seated and small pseudoaneurysm is often impossible [9]. Larger pseudoaneurysms (>3cm) require an invasive treatment by either open surgery or endovascular means using coils or stent-graft insertion [6]. Open surgery techniques depend on the exact site of PFA damage, patient's age and patency of an ipsilateral SFA [5]. In haemodynamically stable patient the proximal PFA false aneurysm should be repaired whenever possible because of the PFA collateral supply to the lower limb [10]. Ligation of the proximal PFA may increase the future risk of limb ischaemia and amputation [11]. The open approach involves aneurysmectomy with an arterial reconstruction by primary arterial repair (if the defect is small), patch angioplasty, and the interposition Great Saphenous Vein or prosthetic graft [11]. On the other hand, if an ipsilateral SFA is patent and the patient is haemodynamically compromised the PFA can be ligated [9]. Moreover, an open repair can be challenging because the PFA with branches penetrates deeply into other muscular compartments and tissues making identification and exploration of these injuries often impossible [2]. Hence, if false aneurysm involves the distal PFA branches, embolisation may be the only alternative [11].

Endovascular treatment in the form of percutaneous embolisation effectively deals with the deep-seated PFA pseudoaneurysms and aims at the exclusion of the pseudoaneurysm from the circulation. Therefore, it is essential to occlude the parent branch both proximal and distal to the pseudoaneurysm neck. Nevertheless, this approach is not advised when the main PFA stem is affected [9]. Some authors also report the successful use of covered stent grafts to provide a complete exclusion of the PFA false aneurysm [12]. However, data is limited, and it should be interpreted with caution. Therefore, the decision regarding an appropriate treatment method with or without revascularisation needs to be tailored accordingly to the patient's clinical status and needs.

IV. Conclusion

The case highlights that even detailed imaging techniques can fail to identify penetrating arterial lower extremity trauma. This can potentially lead to a significant patient's morbidity. In the presented case, the patient was not haemodynamically compromised, but one must remember that this young and healthy group of adults can compensate the haemorrhagic shock with no change in haemodynamic parameters for a considerable time. Substantive evidence shows that following a trauma even up to 88% of patients arrive in the emergency department with a normal SBP and 44% presents with relative bradycardia [13,14]. In contrast, elderly patients that often lack the physiological reserve to combat the haemorrhage can deteriorate rapidly. Therefore, understanding of the mechanism of injury is vital in the safe management of this infrequent vascular trauma. Hence, there is a need to increase awareness among medical staff about the arterial trauma and its potentially serious consequences.

References

- [1]. N [Patelis](#), A Koutsoumpelis, K [Papoutsis](#), G [Kouvelos](#), C [Vergadis](#), A Mourikis, SE [Georgopoulos](#).
- [2]. Iatrogenic injury of profunda femoris artery branches after intertrochanteric hip screw fixation for intertrochanteric femoral fracture: a case report and literature review, *Case Reports in Vascular Medicine*, 2014, doi: 10.1155/2014/694235.
- [3]. EH [Sims](#), M [Yamaguchi](#), MA Lou, AW [Fleming](#). Injuries to the profunda femoris artery and its branches, *Journal of National Medical Association*, 76(4), 1984, 359-61.
- [4]. HT-P Pilson, J Halvorson, RD Teasdall, AC Eben. Missed profunda artery injuries in two patients with penetrating lower extremity trauma, A case report, *Injury Extra*, 43(1), 2012, 6-8.
- [5]. K Unay, O Poyanli, K Akan, A Poyanii. Profunda femoris artery pseudoaneurysm after surgery and trauma, *Strategies Trauma Limb Reconstruction*, 3(3), 2008, 127-9.
- [6]. GB Hanna, RJ Holdsworth, PT McCollum. Profunda femoris artery pseudoaneurysm following orthopaedic procedures, *Injury*, 25(7), 1994, 477-9.
- [7]. F Valli, MG Teli, M Innocenti, R Vercelli, D Prestamburgo. Profunda femoris artery pseudoaneurysm following revision for femoral shaft fracture nonunion, *World Journal of Orthopaedics*, 4(3), 2013, 154-6.
- [8]. S Keskin, O Koc, Z Keskin, S Erol. Radiological findings and endovascular treatment in giant deep femoral artery aneurysms, *BMJ Case Reports*, 2014, doi: 10.1136/bcr-2013-201201.
- [9]. F Cingoz, G Arslan, E Kaya, BS Oz. Very bad clinical aspect towards diagnosis of deep femoral artery injury: Hypovolemic shock, *Journal of Emergencies Trauma and Shock*, 6(4), 2013, 310-1.
- [10]. J Chandrasenan, JP Garner, PD Meiring, K Kumar. Coil embolisation of an iatrogenic profunda femoris pseudoaneurysm, *Injury Extra*, 37(7), 2006, 249-52.
- [11]. RW Franz, KJ Shah, D Halaharvi, ET Franz, JF Hartman, ML Wright. A 5-year review of management of lower extremity arterial injuries at an urban level I trauma center, *Journal of Vascular Surgery*, 53(6), 2011, 1604-10.
- [12]. JL Cronenwett, KW Johnston, *Rutherford's Vascular Surgery* (Saunders Elsevier, Philadelphia, 2010).
- [13]. V Dorrucchi, L Spinamano, G Petralia, F Griselli, N Cibi, R Adornetto. Endovascular repair of a large deep femoral artery branch pseudoaneurysm following a femur fracture: a case report, *European Journal of Vascular and Endovascular Surgery Extra*, 15(3), 2008, 21-23.
- [14]. AM Lipsky, M Gausche-Hill, PL Henneman, AJ Loffredo, [Eckhardt](#), [HG Cryer](#) [HG](#), C de Virgilio, SL [Klein](#), [FS Bongard](#), [RJ Lewis](#). Prehospital hypotension is a predictor of the need for an emergent, therapeutic operation in trauma patients with normal systolic blood pressure in the emergency department, *Journal of Trauma-Injury & Critical Care*, 61(5), 2006, 1228-33.
- [15]. EJ Ley, A Salim, S Kohanzadeh, J [Mirocha](#), [DR Margulies](#). Relative bradycardia in hypotensive trauma patients: a reappraisal, *Journal of Trauma-Injury & Critical Care*, 67(5), 2009, 1051-54.