

## Self Instructed Adaptation of Oral Mucosa-Review

Dr. S. Anitha Devi, Dr. Venkata Srikanth, Dr. Sivaranjani, Dr. R. Dhivya,  
Dr Indhumathi

---

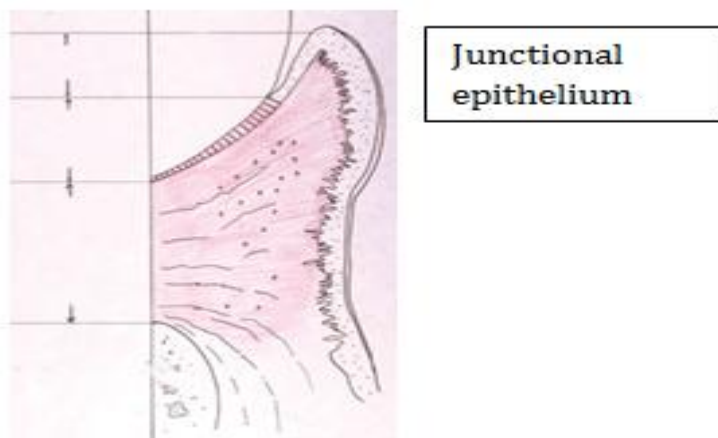
**Abstract:** Gingival epithelium consists of three regions: oral gingival epithelium (OGE), sulcular epithelium (SE) and Junctional epithelium (JE). JE is a specialized gingival epithelium and it is located at a strategically important interface between the gingival sulcus, populated with bacteria, and the periodontal soft and mineralized connective tissues that need protection from becoming exposed to bacteria and their products. Its unique structural and functional adaptation enables the junctional epithelium to control the constant microbiological challenge. The antimicrobial defense mechanisms of the junctional epithelium, however, do not preclude the development of gingival and periodontal lesions. The aim of the review focus on the unique structural organization of the junctional epithelium, on the nature and functions of the various molecules expressed by its cells.

**Keywords:** Junctional epithelium, periodontal diseases, antimicrobial defense

---

### Introduction

The periodontium is a complex organ comprising of four mesenchymal tissue components that act as a functional unit providing the tooth with an attachment apparatus capable of with-standing masticatory forces.<sup>1</sup> The principal components are gingiva, periodontal ligament, alveolar bone and cementum<sup>2</sup>. The periodontium provides the support necessary to maintain teeth in adequate function, which is defined as those tissues supporting and investing the tooth<sup>3</sup>. The physiologic function of periodontium is achieved through the maintenance of structural integrity and a complex interplay between its three varied components of gingival epithelium are oral gingival epithelium (OGE), Sulcular epithelium (SE), Junctional epithelium (JE)<sup>4</sup>, Together constitute the gingival epithelium



**Fig 1:** Diagram showing the varied components of gingival epithelium namely of crevicular epithelium oral epithelium, and junctional epithelium

Among this junctional epithelium exhibits several unique structural and functional specializations, hence junctional epithelium is also known as “self instructed adaptation of oral mucosa”<sup>3</sup> It is the most interesting structure of the gingiva and its inter-poised between the underlying soft and mineralized connective tissue of the periodontium Junctional epithelium is constituted of a collar like band of stratified squamous non keratinizing epithelium and it tapers from its coronal end, which may be 15 to 30 cell layer wide to 1 to 3 cells at its apical termination, located at the cement enamel junction in healthy tissue. These cells can be grouped in two strata: the basal layer facing the connective tissue and the supra basal layer extending to the tooth surface.

They also prevent the pathogenic bacterial flora from colonizing the sub gingival tooth surface and it provides a vehicle for the bidirectional movement of substances between the gingival connective tissue and the oral cavity thus acting as defensive barrier.

But on the contrary junctional epithelium always had been considered as “**weak link**” allowing permeation of bacteria products into gingival connective tissue and initiating an inflammatory response. Being a unique specialized tissue, junctional epithelium still provides a wide area of research to explore the etiology of periodontal disease. The aim of this review is to discuss the structural and functional characteristics of this unique and specialized epithelial seal around teeth and its role in pathogenesis of periodontal disease.

### **Histogenesis Of Junctional Epithelium<sup>5</sup>**

Junctional epithelium is constituted of a collar like band of stratified squamous non-keratinizing epithelium and it tapers from its coronal end, which may be 15 to 30 cell layer wide to 1 to 3 cells at its apical termination, located at the cement-enamel junction in healthy tissue. These cells can be grouped in two strata: the basal layer facing the connective tissue and the supra basal layer extending to the tooth surface. The origin of the JE is provided by Lindhe (1989) which was adapted from the work of Engler et al. (1965) in Rhesus monkeys. Following enamel formation, the height of the ameloblasts is reduced, combining with the outer enamel epithelium to form a flat cuboidal layer called the reduced enamel epithelium (REE). The cells of the REE produce a basal lamina that is joined to the enamel by hemi-desmosomes. As the erupting tooth nears the oral epithelium (OE), the cells of the outer layer of the REE and the basal layer of the OE manifest increased mitotic activity while the former ameloblasts do not divide. When the tooth has penetrated the tissue, the REE and OE fuse at the incisal edge of the tooth. Immediately apical to the incisal edge, the enamel is covered by JE; the REE covers the enamel surface apical to the JE. As the tooth becomes fully erupted, all cells of the REE are gradually replaced by cells of the JE.

### **Developmental Concepts Of Junctional Epithelium<sup>5</sup>**

In 1915, G.V. Black suggested that the oral and odontogenic epithelium fuse into a continuous lining as the tooth erupts. According to Black, only the apical end of the sulcular epithelium was attached to the tooth (at the CEJ), creating a sub gingival space which extended to the CEJ adjacent to the loosely adapted gingiva.

**Gottlieb's theory:** He first coined the term epithelial attachment and proposed that the oral epithelium (OE) fused with the outer enamel epithelium (OEE) of the erupting tooth at the base of the sulcus and suggested that the OEE cells were joined to the tooth by a primary cuticle formed by the degenerating ameloblasts.

The cells of the OEE immediately adjacent to the primary cuticle became keratinized, forming a secondary cuticle, meanwhile the epithelial attachment migrated over the cementum with a corresponding apical displacement of the base of the sulcus. The width of the epithelial attachment remained constant even as the attachment migrated apically, thus resulting in formation of junctional epithelium (JE).

**Modification of Gottlieb's theory: Becks** (1929) proposed a modified version of Gottlieb's theory. He felt that the OE migrated over the connective tissue surface of the OEE. By age 30, the OEE was lost and the OE formed the new attachment.

**Waerhaug** (1952) suggested that the tooth/epithelial interface which extends to the CEJ was a potential space maintained tightly against the tooth by vascular pressure. This concept was known as the epithelial cuff theory.

**Orban** (1960) inserted steel blades into the sulci of dogs and monkeys and demonstrated a firm attachment of epithelial cells to the teeth. The author agreed with Gottlieb's concept of a firm epithelial attachment.

On the contrary, **Listgarten** (1996) felt that epithelial cells, whether derived from reduced ameloblasts or oral epithelium, attached to the tooth by means of hemidesmosomes and a basement membrane (basal lamina). This attachment was not static since cells move along the tooth surface from the apical portion of the epithelial attachment to the base of the sulcus. He observed a Type A cuticle covering areas of the tooth where there was no reduced enamel epithelium. This cuticle was similar to cementum but contained no fibrillar collagen. Interposed between the tooth and the basal lamina is a non-mineralized, electron-dense Type B cuticle. The author indicated that the origin of both cuticles was unknown but postulated that cuticle B was similar to the acquired pellicle and was of salivary origin.

### **Current Concepts**

**Kobayashi et al.** (1976) studied the JE of monkeys, reported a highly variable relationship between the Junctional epithelium and the tooth surface coronal to the CEJ. When present, a homogeneous, electron-dense dental cuticle occurred between the fibrillar cementum and JE. When the dental cuticle was absent, a thin, dense linear border was noticed in the same position. While the origin and function of the dental cuticle are unknown, the linear border was determined to consist of serum proteins from tissue fluids. The authors described a unit of adhesion consisting of the following zones (from tooth to JE): sub-lamina lucida (95 Å), lamina densa (400 Å), lamina lucida (140 Å), and the hemidesmosome. The special components integrating this unit consisted of pyramidal particles on the inner surface of the peripheral density and fine filaments penetrating the lamina

densa, lamina lucida, and the peripheral density. The 140 Å lamina lucida described by the author extended from the peripheral density of the hemidesmosome to the lamina densa. Evidence regarding the origin of the dental cuticle is not yet available. Some investigators consider it is a product of the Junctional epithelium but the JE may attach to teeth without an intervening cuticle.

**Friedman et al.** (1993) suggested that it represents an accumulation of material from plaque metabolites and inflammatory infiltrates. The recent molecular evidence states that the formation of junctional epithelium occur as programmed histologic process in which outer enamel epithelium fuses with oral epithelium resulting in specialized adaptive epithelium.<sup>[24]</sup>

### **Structure Of Junctional Epithelium**

The junctional epithelium arises from the reduced enamel epithelium as the tooth erupts into the oral cavity and it is part of marginal 'free' margin. The attachment of junctional epithelium is originally on the cervical enamel of newly erupted teeth then it shifts to cementum. In older persons the junctional epithelium is mostly attached to cementum and the coronal termination of the junctional epithelium corresponds usually to the bottom of gingival sulcus. Its apical and lateral aspect of the junctional epithelium is bordered by soft connective tissue. Sulcular epithelium border its coronal aspect. In the inter-proximal area, the junctional epithelia adjacent to neighboring teeth fuse to form the epithelial lining of the inter-dental col. The coronal termination of the junctional epithelium is a free surface and is located either at the bottom of the sulcus, at the gingival margin, or at the inter-dental col area. Normal gingiva, however, expresses sub-clinical signs of slight inflammation.

Therefore, the coronal termination of the junctional epithelium corresponds usually to the bottom of the gingival sulcus. At its apical and lateral aspects, the junctional epithelium is bordered by soft connective tissue and, at its coronal-most portion by the sulcular epithelium. The epithelium-connective tissue interface is smooth, showing an only mild undulation coronally. Normal gingiva however, expresses sub-clinical signs of slight inflammation, therefore the coronal termination of the junctional epithelium corresponds usually to the bottom of the gingival sulcus. Hence junctional epithelium is not visible intraorally in the interproximal area the junctional epithelium adjacent to neighboring teeth fuse to form the epithelial lining of the interdental col.

### **Turn Over Rate Of Junctional Epithelium<sup>7</sup>**

The junctional epithelium which is stratified epithelium comprising of the basal layer facing the connective tissue and the supra basal layer extending to the tooth surface is multilayered at its coronal aspect and becomes bi-layered or tri-layered as it moves apically. Junctional epithelium is unique since it is estimated to have a very high turnover rate which is about 6 days approximately in humans.

The turnover of the junctional epithelium exhibits a faster rate than the gingival epithelium. Cell division occurs in the basal cell layer and all the daughters cells migrate in the direction of gingival sulcus, where they are rapidly sloughed. As a result of this there is a constant flow of junctional epithelium cells, active migration of granulocytes into the sulcus. This effectively clears the invading bacteria and their metabolic products thus acting as strong barrier against infection. Previously it was thought that only epithelial cells facing the external basal lamina were rapidly dividing, however recent evidence indicates that a significant number of the Directly attach to tooth (DAT) cells are like the basal cells along the connective tissue, capable of synthesizing DNA, which also demonstrates the mitotic activity. At the coronal part of the junctional epithelium, the DAT cells typically express a high density of transferrin receptors, which supports the idea of their active metabolism and high turnover. The findings suggest that the DAT cells have a more important role in tissue dynamics and reparative capacity of the junctional epithelium than has previously been thought. Based on these data, alternative models for the turnover of DAT cells can be proposed. The existence of a dividing population of epithelial cells (DAT cells) in a supra basal location, several layers from the connective tissue, is a unique feature of the junctional epithelium.

### **Mechanism Of Cells Turnover<sup>[7]</sup>**

The daughters cells are produced by dividing DAT cells and replace degenerating cells on the tooth surface. The daughter cells enter the exfoliation pathway and gradually migrate coronally between the basal cells and the DAT cells to eventually break off into the sulcus or the epithelial cells migrate in the coronal direction along the tooth surface and are replaced by basal cells migrating round the apical termination of junctional epithelium.

### **Permeability Of Junctional Epithelium<sup>7</sup>**

The junctional epithelium is the most permeable portion of the gingival epithelia. Because of its permeability to bacterial products and other assorted antigens, the connective tissue adjacent to the junctional epithelium tends to become infiltrated with chronic inflammatory cells, primarily lymphocytes and plasma cells.

The permeability of the junctional epithelium with respect to egress of sulcular fluid and ingress of foreign particles is reasonably well established. However, how material enters and permeates (passively) through this tissue into the gingival connective tissue is unclear. Furthermore, with the continual passage of leukocytes and the rapid turnover of this tissue, the logistics of permeation of substances inwards is difficult to understand. Nonetheless, such permeability has been considered to be one of the principal events associated with the establishment of disease. Indeed, the so called "wider" intercellular spaces of the junctional epithelium have always been considered a "weak link" allowing permeation of bacterial products into the gingival connective tissue and initiating an inflammatory response.

### **Function Of Junctional Epithelium<sup>6</sup>**

Gingival epithelium performs a number of very important protective and also defense functions, it is more or less a by stander that provides a barrier function or curtain separating the biofilm from the connective tissue of the junctional epithelium is not only from the epithelial attachments apparatus to tooth surface, it is also provide a vehicle for the bidirectional movements of substance between the gingival connective tissue and the oral cavity and also it plays both an instructive and communication role in the host defense against bacterial infection. The attachment of the junctional epithelium to the tooth is reinforced by the gingival fibers, which brace the margin against the tooth surface. This is the reason junctional epithelium and gingival fibers is considered as a functional unit and it exhibits several unique structural and functional features that contribute to preventing pathogenic bacterial flora from colonizing the sub gingival tooth surface. Healthy junctional epithelium is infiltrated by neutrophils and numbers greatly increase in response of plaque and gingival inflammation and it is also highly permeable to bacterial products and other antigen originating from oral cavity due to keratinization and low density of intercellular junction.

### **Regeneration Of The Junctional Epithelium<sup>6</sup>**

Injury of the junctional epithelium may occur through accidental or intentional trauma, tooth brushing, flossing, or clinical probing. Since the junctional epithelium is located at a strategically important but also delicate site, it may be expected that it should be very well-adapted to cope with mechanical insults. The removal of any soft tissue adhering all along the tooth surfaces, but the groove cut into the cementum and dentin surfaces, according to the technique of Cross and Morris brings undisputable evidence of the epithelial reattachment. Oral hygiene practices may be accompanied by undesired trauma to the junctional epithelium but it is overcome by excellent healing capacity of JE. During repair detachment of cells persists for 24 hours, and new attachment of junctional epithelial cells starts after 3 days. After 2 weeks, the cell populations will be indistinguishable from normal. The junctional epithelium can never be completely removed from the tooth mechanically except for gingival surgical techniques such as gingivectomy.

Subsequently, the formation of a new junctional epithelium occurs from basal cells of the oral gingival epithelium. Under the electron microscope, the newly formed epithelial attachment, as well as the connective tissues appears normal, without any signs of inflammation. No infiltration of leukocytes were visible. The intercellular spaces of the epithelial attachment were of normal width, with typical intercellular junctions. Clinical probing results in a mild mechanical disruption of the junctional epithelial cells from the tooth. Following probing, a new indistinguishable attachment will be established within 5 days. The re-establishment of the epithelial seal around implants after clinical probing also occurs within the same time period. Hence probing around teeth and implants for clinical evaluation does not seem to cause irreversible damage to the soft tissue components.

### **Connective Tissue Compartment<sup>8</sup>**

The connective tissue components of junctional epithelium differ from the other oral epithelium. Even in clinically normal circumstances, it shows an inflammatory cell infiltrate. The gingival connective tissue adjacent to the junctional epithelium contains an extensive vascular plexus. Inflammatory cells such as polymorphonuclear leukocytes and T-lymphocytes continually extravasate from this dense capillary and post capillary venule network, and migrate across the junctional epithelium into the gingival sulcus and eventually the oral fluid. One point of view considers the junctional epithelium as an incompletely developed stratified squamous epithelium. Alternatively, it may be viewed as a structure that evolves along a different pathway and produces the components of the epithelial attachment instead of progressing further into a keratinized epithelium. The special nature of the junctional epithelium is believed to reflect the fact that the connective tissue supporting it is functionally different than that of the sulcular epithelium, a difference with important implications for understanding the progression of periodontal disease and the regeneration of the dentogingival junction after periodontal surgery.

### Clinical Significance Of Junctional Epithelium Junctional Epithelium Adjacent To Oral Implants<sup>9</sup>

Junctional epithelium around implants always originates from epithelial cells of the oral mucosa, epithelial tissue have the capacity to proliferate and to move on surface ,following implants or abutment placement ,epithelial migration from adjacent soft tissue. The epithelium moves in apico-coronal directions as soon as it reaches the implant surface, it give rise to junctional epithelium about 2 mm long. The formation of junctional epithelium in implants interface can be considered as the first barrier of defense against oral microflora. The interface between the gingival and tooth enamel is characterized by the presence of an attachment apparatus composed of well developed hemidesmosomes at the basal surface of the junctional epithelium and internal basal lamina

The Peri-implant Epithelium is divided to 3 regions, the upper, middle and lower regions ,equivalent to the three regions of the junctional epithelium: the coronal ,middle and apical regions .The upper region of PIE is closes to peri implant sulcus, when lower region connected to the sub PIE tissue, the middle regions is intercalated between the upper and lower region .the PIE expresses a unique distribution of epithelial attachments compared to junctional epithelium. Some studies indicate that junctional epithelium was almost fully restored to the normal condition after 4 week of replantation.

### Biological Width<sup>10</sup>

The biological width is defined as the dimension of the soft tissue, which is attached to the portion of the tooth coronal to the alveolar bone, it includes both connective tissue attachment and junctional epithelium This term was based on the work of Gargiulo *et al* (1961).

### Summary And Conclusions

The junctional epithelium is located at a strategically important interface between the gingival sulcus, populated with bacteria, and the periodontal soft and mineralized connective tissues that need protection from becoming exposed to bacteria and their products. Its unique structural and functional adaptation enables the junctional epithelium to control the constant microbiological challenge. The antimicrobial defense mechanisms of the junctional epithelium, however, do not preclude the development of gingival and periodontal lesions. The conversion of the junctional to pocket epithelium, which is regarded as a hallmark in disease initiation, has been the focus of intense research in recent years. Research has shown that the junctional epithelial cells may play a much more active role in the innate defense mechanisms than previously assumed. They synthesize a variety of molecules directly involved in the combat against bacteria and their products. In addition, they express molecules that mediate the migration of polymorphonuclear leukocytes toward the bottom of the gingival sulcus there by functioning as barrier to periodontal disease.

To conclude junctional epithelium is a unique tissue that fulfills a challenging function at the border between the oral cavity, colonized by bacteria, and the tooth attachment apparatus. It is structurally and functionally very well-adapted to control the constant presence of bacteria and their products. However, its antimicrobial defense mechanisms do not preclude the development of inflammatory lesions in the gingiva. These defense mechanisms may be overwhelmed by bacterial virulence factors, and the gingival lesion could progress to periodontitis. Hence proving that periodontal disease as persisting challenge to clinicians .Further research is needed about junctional epithelium and various molecules expressed by it to unravel many key points in pathogenesis of periodontal disease.

### References

- [1]. Nunez J, Sanz-blasco S, Vignoletti F, Munoz F, Arzate H, Villalobos C, Nunez , Caffesse RG et al. Periodontal regeneration following implantation of cement and periodontal ligament-derived cells. J periodontal 2012;47:33-44.
- [2]. Mark bartold P, Laurence J. Walsh, Sampath Narayanan A. Molecular and cell biology of the gingiva. Periodontology 2000 2000;24:28-55.
- [3]. Marja Pollanen T ,Jukka Salonen.I, Veli-jukka Uitto. Structure and function of the tooth-epithelial interface in health and disease. Periodontology 2000 2003;31:12-31.
- [4]. Mark bartold P. Periodontal tissues in health and disease: introduction. Periodontology 2000 2006;40:7-10.
- [5]. America academy of Periodontology, "Chapter 1 Periodontium Histology," J Periodontol 1996: 1-11.
- [6]. Bosshardt DD and Lang N P. The Junctional Epithelium: from Health to Disease. J Dent Res 2005; 84(1):9-20.
- [7]. Marja T. Pollanen. Structure and function of the tooth-epithelial interface in health and disease. Periodontology 2000 2003; (31):12-31.
- [8]. nanci A & Dieter D. Bosshardt. Structure of periodontal tissues in health and disease. Periodontology 2000 2006;(40):11-28.
- [9]. Rodrigo F, Neiva, Kathleen, Neiva G, Tae-Ju. Clinical and morphological aspect of the implants/soft tissue interface. Int chin j dent 2002;151-61
- [10]. Khuller N, Sharma N. Biologic Width:Evaluation and Correction of its Violation.J Oral Health Comm Dent 2009;3(1):20-25.