

## Unusual bilateral communication between the various branches of posterior division of mandibular nerve: its clinical significance

Shobha kumari<sup>1</sup>, Atulya prasad<sup>1</sup>, Subratanag<sup>2</sup>, Jacques Britto<sup>1</sup>, Rita kumari<sup>1</sup>

<sup>1</sup> Department of Anatomy, All India Institute Of Medical Sciences, Patna, Bihar, India

<sup>2</sup> Department of Anaesthesia, Narayan Medical College and Hospital, Jamuhar, Rohtas (Sasaram)

---

**Abstract:** Lots of variations as well as unusual communications between the various branches of mandibular nerve is frequently found on dissection. But these anatomical variations have not been conclusively described in the anatomical & surgical literature. These communications and variations frequently accounts for the failure to obtain adequate anesthetic effect in routine oral and dental procedure and also for unexpected injury to the branches of the nerve during surgery, it may cause refractory neuralgia also. During our routine dissection we found the presence of a communicating branch between inferior alveolar nerve and auriculotemporal nerve and also bilateral communicating branch between mylohyoid nerve and lingual nerve in a middle aged male cadaver. We have also discussed its clinical and surgical implications in this report.

**Key words:** Mandibular nerve, Auriculotemporal nerve, Inferior alveolar nerve, Lingual nerve, Mylohyoid nerve.

---

### I. Introduction

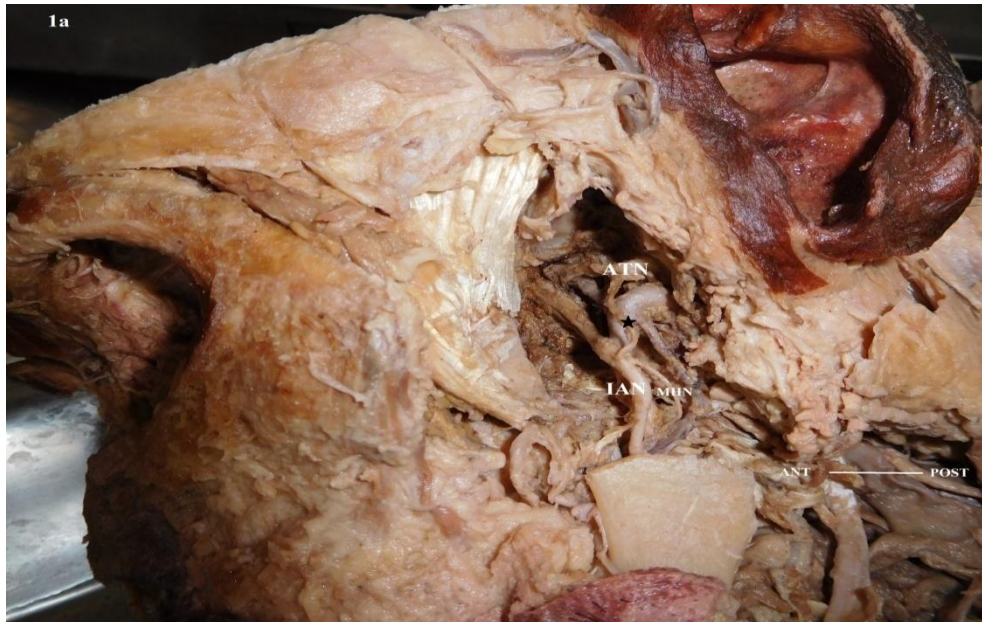Trigeminal nerve is the largest and mixed cranial nerve. It gives rise to ophthalmic, maxillary and mandibular nerve in middle cranial fossa. The ophthalmic and maxillary nerves are purely sensory while the mandibular nerve contains motor and sensory fibres.

The Mandibular nerve emerges from the skull through foramen ovale, descends downwards and divides into anterior and posterior divisions. Anterior division give rise to muscular branches. Posterior division gives rise to three large branches –Inferior alveolar nerve (IAN), Auriculotemporal nerve (ATN) and Lingual nerve (LN). The IAN descends downwards then enters into mandibular foramen, travels in inferior alveolar canal and innervates the teeth and gums of lower jaw. The ATN usually arise from two roots around middle meningeal artery and innervates the temporal region, external acoustic meatus and Temporomandibular joint.(1,2) The LN innervates tongue and salivary glands. The MHN arise from IAN before it enters into mandibular foramen, It innervates mylohyoid and anterior belly of digastric muscle. The mylohyoid muscle plays important role in chewing, swallowing, respiration and phonation.(5)

Various studies have revealed anomalous communications between branches of posterior division of mandibular nerve(2-4). In present case an unusual bilateral communication between IAN & ATN as well as LN & MHN have been found in the middle aged male cadaver.

### II. Case Report

During our routine dissection of a middle aged male cadaver in the department of anatomy, AIIMS, PATNA, rare bilateral communication were noted between IAN & ATN as well as between LN & MHN. Dissection of Infratemporal region on both the side were done carefully as per dissection norms. All the branches of mandibular nerve were traced meticulously. We found bilateral communication between ATN & IAN. ATN originated from one root rather than forming a loop around middle meningeal artery and then followed its normal course. A thin communicating branch arise from ATN and joined IAN at acute angle from posterior aspect. Just after receiving communicating branch IAN gave rise to MHN before entering into mandibular foramen. MHN & LN were following their normal course and in the digastrics triangle a communicating branch was arising from MHN and it is going forward to join LN.



**Fig 1a:** Lateral view of the left infratemporal region showing a communicating branch (marked ☆) between the inferior alveolar nerve & auriculotemporal nerve. Both nerves are following its normal course.

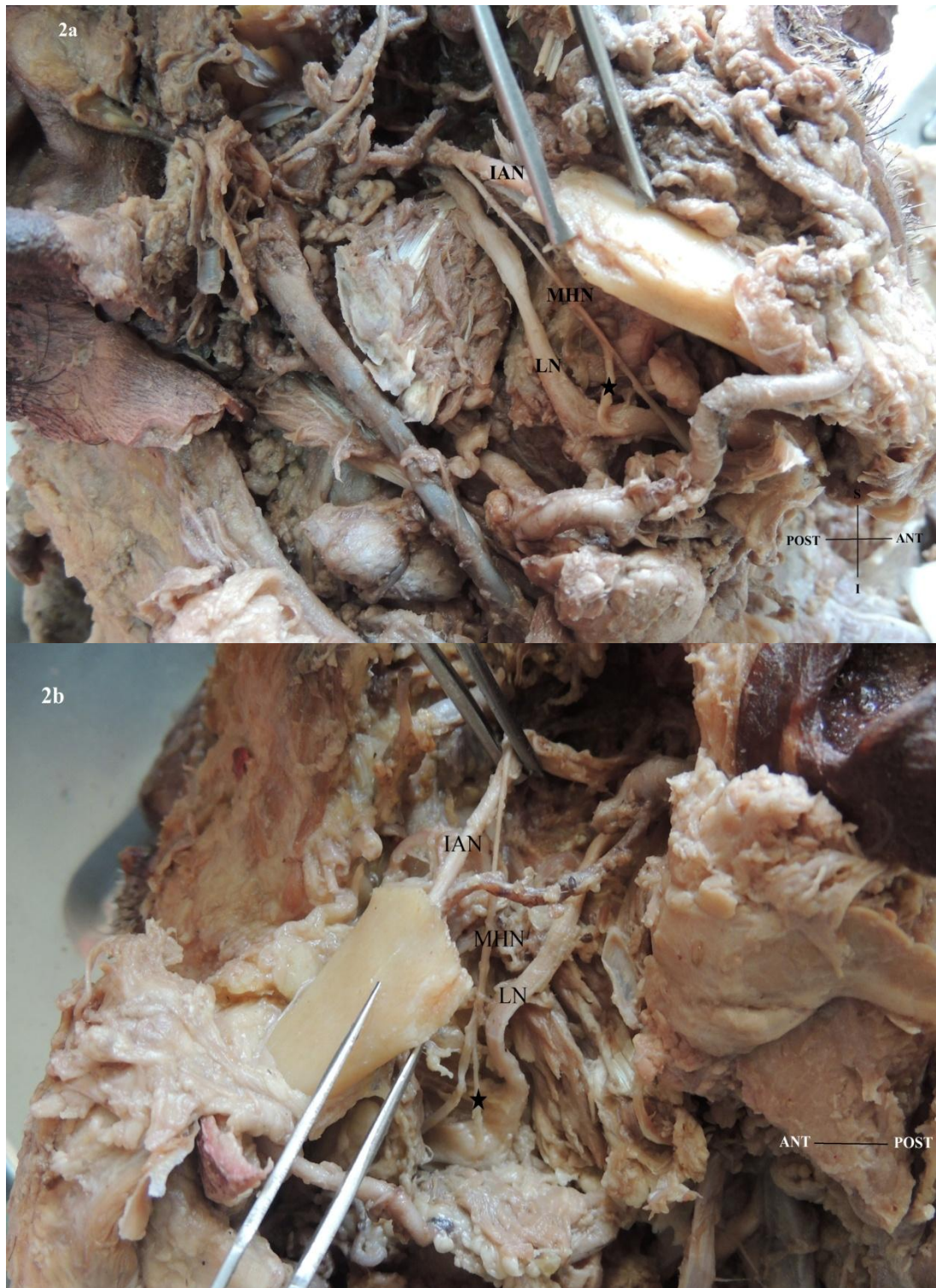
**ATN:** Auriculotemporal nerve, **IAN:** Inferior alveolar nerve, **MHN:** Mylohyoid nerve.

Asterisks (☆) showing the communication between the two nerves.



**Fig 1b:** Lateral view of the right infratemporal region showing a communicating branch (marked ☆) between the inferior alveolar nerve & auriculotemporal nerve. Both nerves are following its normal course. Mylohyoid nerve is arising from inferior alveolar nerve and it lies posterior to it.

**ATN:** Auriculotemporal nerve, **IAN:** Inferior alveolar nerve, **MHN:** Mylohyoid nerve, **LN:** Lingual nerve.



**Fig 2:** Lateral view of the (a) right and (b) left infratemporal region showing a communicating branch (marked ☆) between the mylohyoid nerve & Lingual nerve on both sides in a middle aged male cadaver. Both nerves are following its normal course.

**IAN:** Inferior alveolar nerve, **MHN:** Mylohyoid nerve, **LN:** Lingual nerve

### III. Discussion

So many studies have revealed that there are lots of variations and communications between the branches of posterior division of mandibular nerve. But these variations are not regularly mentioned in the anatomical and surgical text books. In this case we have reported a rare bilateral communication between ATN & IAN and also between MHN & LN.

These anatomical variations can be explained on developmental basis. Mandibular nerve develops from first arch by neural crest cells of cephalic region (6). F- spondin and T-cadherin liberated from caudal somites are thought to be responsible for neural development(7,8). Abnormal expression of these proteins may be the cause of delayed regression of the first arch vessels and be responsible for anomalous communication between the nerves. Nikha bhardwaj et al (4) studied 30 specimens for anomalous communication between the branches of posterior division of mandibular nerve, in one body they observed bilateral communication between ATN & IAN. They considered that these type of communication may be due to delayed regression of 1<sup>st</sup> arch vessels. Balaji Thotakura et al (3) studied 36 specimens, in two specimens they found abnormal communication between mylohyoid & lingual nerve; In one case communication between ATN & IAN was observed and in one case the communicating nerve was forming a buttonhole for passage of mylohyoid nerve.

Har simarjit kaur et al (11) has also reported bilateral communication between the MHN and LN , they studied its clinical implications during oral surgery and dental procedures.

Communications between MHN and LN were well described in literature (9,10). These communication have been identified as possible explanation for the inefficiency of mandibular anaesthesia. LN lies in close relation to 3<sup>rd</sup> molar teeth, so makes it susceptible to injury during the 3<sup>rd</sup> molar extraction(14).

Communication between MHN and LN as described in this case can innervate the tongue and surgeons should be aware of this variation to avoid unexpected complications after oral surgeries. In case of LN injury these communications would help in the LN functional recovery by contributing additional sensory innervations to the tongue. This communicating branch might be involved in the coordination of tongue movements with suprahyoid muscles via proprioceptive impulses. One of the explanation for such communication is likely the hitchhiking of fibres during the developmental process.

Conclusively it can be said that variations are not uncommon and knowledge regarding such communications and its functional perspectives are absolutely necessary for various surgical and anaesthetic procedures.

### References

- [1]. Berkovitz BK. Infratemporal region and temporomandibular joint. In: Standring S, editor. Gray's Anatomy: The Anatomical basis of Clinical practice. 39<sup>th</sup> ed. Edinburgh: Elsevier Churchill Livingstone, 2005:526-530.
- [2]. Siessere S, Hallak Regalo SC, Semprini M, et al. Anatomical variations of the mandibular nerve and its branches correlated to clinical situations. *Minerva Stomatol* 2009;58:209-15.
- [3]. Thotakura B, Rajendran SS, Gnanasundaram V, Subramaniam A. Variations in the posterior division branches of the mandibular nerve in human cadavers. *Singapore Med J*. 2013;54(3):149-151. Doi: 10.11622/smedj.2013051
- [4]. Bhardwaj N, Sahni P, Singhvi A, Nayak M, Tiwari V. Anomalous bilateral communication between the inferior alveolar nerve and the auriculotemporal nerve. *Malays J Med Sci*. sep-oct 2014;21(5):71-74.
- [5]. REN M, MU L, Intrinsic properties of the adult human mylohyoid muscle: neural organization, fibre-type distribution, and myosin heavy chain expression, *Dysphagia*, 2005, 20(3): 182-194.
- [6]. Bronner-Freser M. Environmental influences on neural crest cell migration. *J Neurobiol*. 1993;24(2):233-247. doi:10.1002/neu.480240209.
- [7]. Debby-Brafman A, Burstyn-Cohen T, Klar A, Kalcheim C. F-Spondin, expressed in somite regions avoided by neural crest cells, mediates inhibition of distinct somite domains to neural crest migration. *Neuron*. 1999;22(3):475-488. Doi: 10.1016/so896-6273(00)80703-5.
- [8]. Ranscht B, Bronner-Fraser M. T-cadherin expression alternates with migrating neural crest cells in the trunk of the avian embryo. *Development*. 1991;111:15-22.
- [9]. Sassoli Fazan V.P, Rodrigues Filho OA, Matamala F. Communication between the mylohyoid and lingual nerves: clinical implications. *Int J Morphol* 2007;25:561-4
- [10]. Potu BK, Pulakunta T, Ray B, et al. Unusual communication between the lingual nerve and mylohyoid nerves in a South Indian male cadaver: its clinical significance. *Rom J Morphol Embryol* 2009;50:145-6.
- [11]. Kaur H.S, Upasana, Bajwa SJS, Kalyan GS, Singh M. Bilateral communication between mylohyoid nerve and Lingual nerve: Clinical implications. *Archives of Medicine & Health Sciences*. Jul-Dec 2014;2(2): 217-219.
- [12]. Soni S, Rath G, Suri R, Vollala V R. Unusual Organization of Auriculotemporal nerve and its clinical implications. *J Oral Maxillofac Surg*. 2009;67(2):448-450. Doi: 10.1016/j.joms.2008.09.012.
- [13]. Anil A, Peker T, Turgut HB, Gulekon IN, Liman F. Variations in the anatomy of the inferior alveolar nerve. *Br J Oral Maxillofac Surg*. 2003;41(4):236-239. doi:10.1016/so266-4356(03)00113-x.
- [14]. Behnia H, Kheradvar A, Shahrokhi M. An anatomic study of the lingual nerve in the third molar region. *J Oral Maxillofacial Surg*. 2000, 58(6):649-651: discussion 652-653.