

Case Report on Prolapsed Lumbar Intervertebral Disease (PLID) Treatment Through Acupuncture: In Suo Xi Acupuncture Hospital in Bangladesh

Dr. S.M. Shahidul Islam¹, Sabina Yasmin², Dr. Boxu Lang³

¹PhD fellow in pain management, specially trained in Acupuncture

Suo Xi Hospital, Shaan Tower, Chamelibagh, Santinagar, Dhaka, Bangladesh

²CEO, Suo Xi Hospital, Shaan Tower, Chamelibagh, Santinagar, Dhaka, Bangladesh

³Chief Chinese Medicine Practitioner, Taizhou Municipal Hospital, Zhejiang, China

Corresponding Author: Dr. SM Shahidul Islam

Abstract

Two of the most common health problems are low back pain and sciatica. The number of hours worked and the amount of money lost by both employees and the nation as a whole are both drastically reduced. It's critical to do a full physical assessment on these patients before beginning any treatment. It is feasible that symptoms might worsen as a result of receiving insufficient medical or surgical therapy. The aim of the case study was to see the effects of acupuncture in the treatment of PLID. Suo Xi Hospital in Shantinagar, Dhaka, Bangladesh, was the site of this investigation. For two years, a 36-year-old male patient has been complaining of low back pain. X-Ray of the lumbosacral spine of both views was used to confirm the diagnosis. The results of the follow-up study were excellent. The patient's lower back pain, which he had been suffering for two years, was no longer present. Patients with PLID may benefit from acupuncture, according to this research.

Keywords: PLID, Acupuncture, Acupuncture, Physiotherapy, Mobilization, Manipulation, Active-Passive Movement, Low Back-pain, lumbar disc, Lumbar Intervertebral Disc, Disc dehydration

Date of Submission: 29-05-2022

Date of Acceptance: 10-06-2022

I. Introduction

The prolapsed lumbar intervertebral disc is one of the most common causes of low back and/or leg discomfort (PLID). The prevalence of PLID in men worldwide ranges from 1.9 to 7.6 percent, whereas in women, it is between 2.2% and 5.0%.^[1] Patients who have PLID are more likely to suffer from back pain, lower back pain (including sciatica), and quadra-equines syndromes as well as radicular pain and neurological deficiency owing to nerve root compression.^[2-5] This results in radiating pain up to the whole lower leg. Lumbar intervertebral discs are composed of collagen, proteoglycan, and glycosaminoglycan. They help to alleviate the strain on the spine. Fatty acid syntheses are reduced as fibro chondrocytes age, which is a typical aspect of the degenerative process that occurs in the disc. Due to the disc becoming dry and eventually collapsing, there is greater stress on the surrounding fibers of the annulus fibrosus. There may be rips and fissures that make it easier for disc material to herniate if a disc is under a lot of strain. In the event of a catastrophic collapse of the annular fibers in a healthy, normal disc, large biomechanical loads may cause the outflow of the disc material. When the outer rings of an intervertebral disc are ruptured, a condition known as PLID or a slipping disc occurs because of a medical condition known as condyververtebral dissection. It is quite uncommon to have a loss of control over one's bowels or bladder, thus immediate medical attention should be sought.^[6-9] A herniated or ruptured disc in the lumbar spine may cause lower back and leg discomfort. A herniated disc may cause pain, numbness, or tingling in the legs, as well as all of the symptoms listed above. Coughing, sneezing, or leaning over seems to exacerbate the pain. The intervertebral disc matrix dries out, resulting in prolapsed disc disease. A wide range of back and sciatica pain concerns, including lumbar disc degeneration, is referred to as lumbar disc disease. A lumbar herniated disc is shown in this article. One-third of all cases of back pain are considered to be caused by lumbar disc degeneration. This herniation may cause pain, muscular weakness, and a loss of tactile sensation if it compresses the nerve fibers closest to the skin. Pain runs down one leg, down the side of the calf, and into the foot when a nerve is damaged (sciatica). The fourth and fifth lumbar vertebrae, or the fifth lumbar vertebra and the first sacral segment, are the most typical locations for nerve root impingement. When it came to PLID risk factors, jobs such as those involving building or remodeling; manufacturing; food preparation; or transportation all showed a connection to the study's findings. PLID increases the risk of an accident among drivers of all skill levels, including those who are not

professionals. Female domestic servants, private sector service workers, and seamstresses all work in high-risk jobs. These women work alongside their male counterparts in the same industries. Hospitalization rates are higher among workers in various occupations who have PLID, according to medical data.

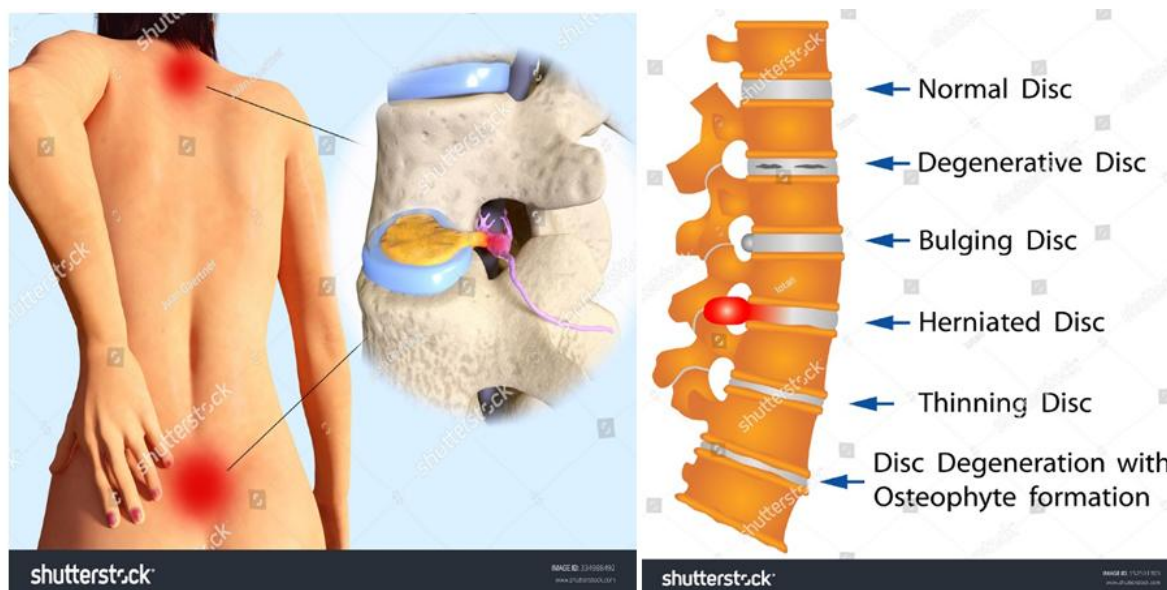
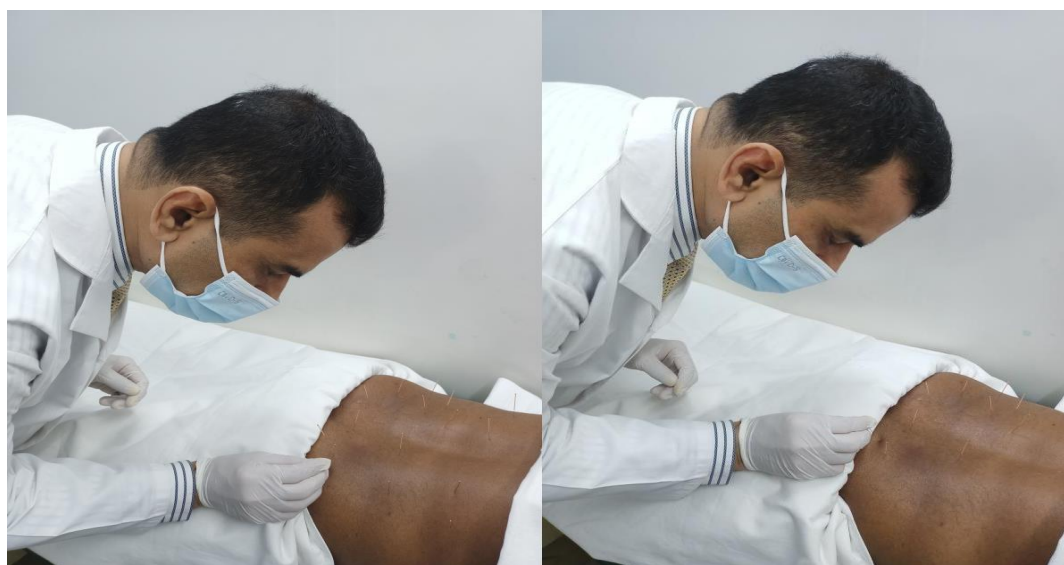
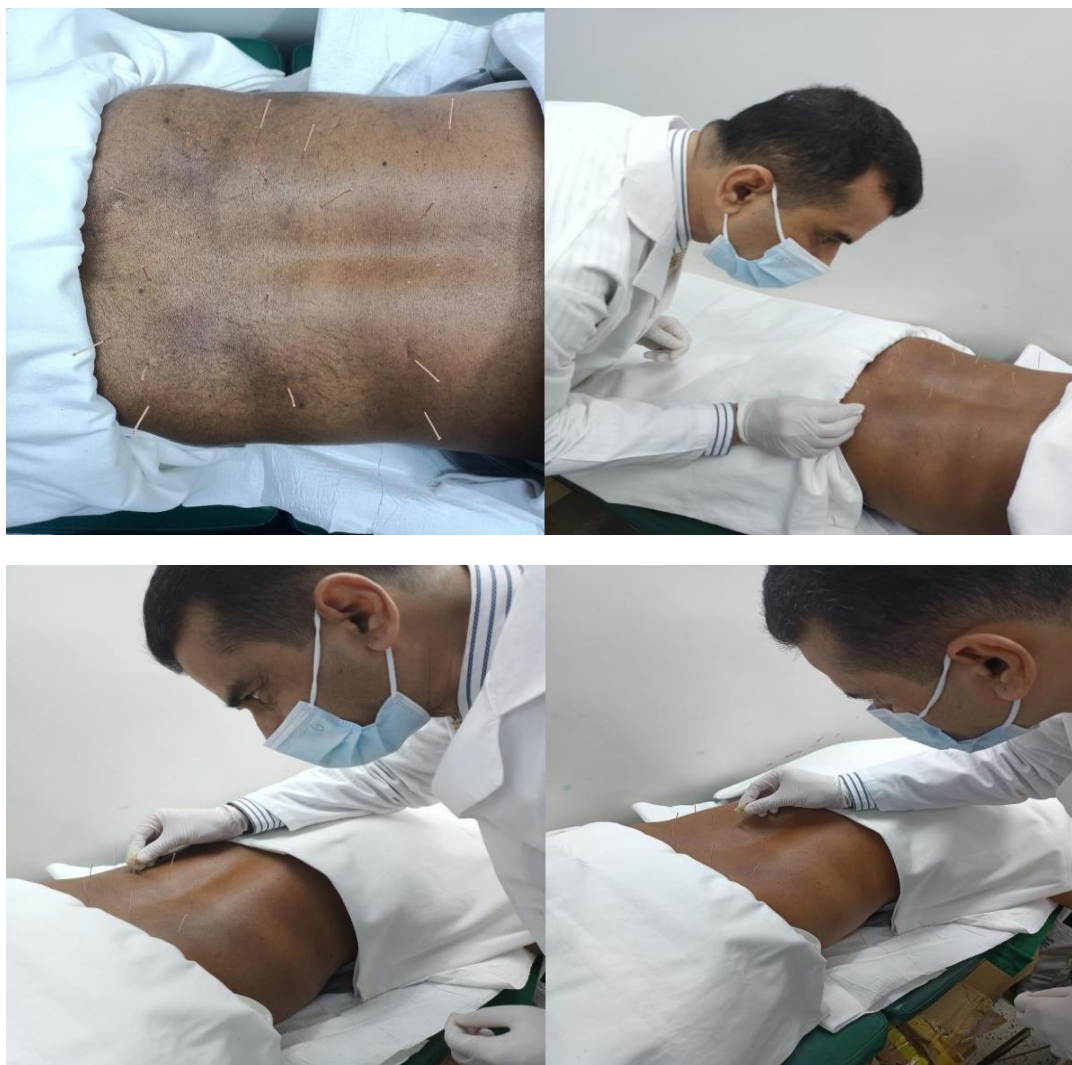
Figure 1: Prolapsed Lumbar Intervertebral Disease (PLID)

II. Case Report

A 36-year-old male patient came to our clinic with complaints of low back pain that he had been experiencing for the preceding two years and that had become intolerable for him. The X-Ray of the lumbosacral spine (both views) was used in this investigation, which was conducted in the laboratory. The report of the X-Ray reveals mild degenerative osteoarthritic changes of L2-L4 vertebral. Also, mild bilateral degenerative Sacro ileitis with reduced S1 joint spaces was seen in the X-Ray report. In this particular instance, it was revealed that the patient's symptoms were caused by a prolapsed Lumbar Intervertebral





Picture: A, B, C, D, E, F: Giving Acupuncture at the Lumbar Region

Disc. Physiotherapy (Lumber mobilization, Manipulation, isometric back muscle strengthening exercise) and acupuncture in the lumbar area are all methods utilized by practitioners to get patients started on their treatment. Working with the patient, we use lumber mobilization, Manipulation, isometric back muscle strengthening exercise approaches to assist him to move more freely and comfortably. The findings of the follow-up research were overwhelmingly good and promising, as was the overall conclusion. A significant improvement in the patient's condition was seen after his second acupuncture treatment in the lumbar region. After suffering from lower back discomfort for an extended period of time, the patient had an unexpected relief.

III. Discussion

A prolapsed intervertebral disc is the most prevalent cause of lower back discomfort, making it the most common kind of orthopedic illness (lower back pain). The fenestration of the vertebral lamina is a common surgical procedure for treating lumbar intervertebral disc prolapse. ^[10,11] Practicing acupuncture and moxibustion requires an understanding of the concepts of channels and collaterals, which are explained in further detail below. Current research suggests that the nervous and muscular systems work together to create channels and collaterals that are then used by other organs and systems. ^[12,13] The patient, a 36-year-old patient, presented to our clinic with symptoms of low back pain that had been present for one and a half years at this point. It was excruciating to be in such discomfort. We carried out a large number of experiments on our own. When using an X-Ray of the lumbosacral spine (both views) to examine the lumbar spine at the L2-L4 and S1 level, it is discovered that there is disc dehydration at the S1 level. In addition, mild degenerative osteoarthritic changes of L2-L4 vertebral were seen in the X-Ray report. Also, mild bilateral degenerative Sacro ileitis with reduced S1 joint spaces was seen in the report. As shown by this sign, the person in question is PLID. Acupuncture and physiotherapy were used in conjunction with each other to treat the patient's ailment. In the

end, everything worked out just great. The discomfort in the patient's lower back has decreased significantly after the third acupuncture treatment. In the end, however, the treatment worked.

IV. Conclusion

The follow-up research yielded stunning findings. Pain in the patient's low back started to lessen after the third acupuncture treatment. The patient's lower back pain has vanished. With PLID patients, acupuncture has been demonstrated to aid their recovery.

References

- [1]. Wu JP, Qiu FZ, Huang JS. Surgery. Beijing: Public health publishing house 2000; 2216-2221.
- [2]. Tang, S., Qian, X., Zhang, Y., & Liu, Y. (2016). Treating low back pain resulting from lumbar degenerative instability using Chinese Tuina combined with core stability exercises: A randomized controlled trial. *Complementary Therapies in Medicine*, 25, 45–50. <https://doi.org/10.1016/j.ctim.2016.01.001>
- [3]. Zhang, Y., Tang, S., Chen, G., & Liu, Y. (2015). Chinese massage combined with core stability exercises for nonspecific low back pain: a randomized controlled trial. *Complementary Therapies in Medicine*, 23(1), 1–6. <https://doi.org/10.1016/j.ctim.2014.12.005>
- [4]. Karamouzian, S., Ebrahimi-Nejad, A., Shahsavarani, S., Keikhosravi, E., Shahba, M., & Ebrahimi, F. (2014). Comparison of two methods of epidural steroid injection in the treatment of recurrent lumbar disc herniation. *Asian Spine Journal*, 8(5), 646–652. <https://doi.org/10.4184/asj.2014.8.5.646>
- [5]. Wang, Y., Yuan, H., Xu, D., & Wy, W. (2009). Balance acupuncture: An experimental study on the effectiveness of treating radicular pain in a lumbar disc herniation rat model. *Deutsche ZeitschriftFürAkupunktur*, 52(4), 24–32. <https://doi.org/10.1016/j.dza.2009.10.017>
- [6]. Shin, B.-J. (2014). Risk factors for recurrent lumbar disc herniations. *Asian Spine Journal*, 8(2), 211–215. <https://doi.org/10.4184/asj.2014.8.2.211>
- [7]. Glazov, G., Yelland, M., & Emery, J. (2016). Low-level laser therapy for chronic non-specific low back pain: a meta-analysis of randomised controlled trials. *Acupuncture in Medicine: Journal of the British Medical Acupuncture Society*, 34(5), 328–341. <https://doi.org/10.1136/acupmed-2015-011036>
- [8]. Li, H., Shang, X.-J., & Dong, Q.-R. (2015). Effects of transcutaneous electrical nerve stimulation on rats with the third lumbar vertebrae transverse process syndrome. *Acupuncture in Medicine: Journal of the British Medical Acupuncture Society*, 33(5), 400–405. <https://doi.org/10.1136/acupmed-2014-010752>
- [9]. Su G, Zhou Z, Luo J. The clinical observation of treating lumbar disc herniation resulted from stagnancy of both blood and qi using acupuncture. *CJTTCM* 2011; 23:320-2.
- [10]. Kim, K. H., Kim, Y. R., Baik, S. K., Noh, S. H., Kim, D. H., Lee, S. W., & Yang, G. Y. (2016). Acupuncture for patients with lumbar spinal stenosis: a randomised pilot trial. *Acupuncture in Medicine: Journal of the British Medical Acupuncture Society*, 34(4), 267–274. <https://doi.org/10.1136/acupmed-2015-010962>
- [11]. Qi, Z., & Xiao-gang, Y. (2005). Clinical observations on the treatment of lumbar intervertebral disc protrusion by acupuncture and Tuina. *Journal of Acupuncture and Tuina Science*, 3(6), 39–41. <https://doi.org/10.1007/bf02851668>
- [12]. Zhang, C. (2003). Protrusion of lumbar intervertebral disc treated by ultra-short wave and the point injection in 40 cases. *Chung iTsaChih Ying Wen Pan [Journal of Traditional Chinese Medicine]*, 23(1), 43–44. <https://pubmed.ncbi.nlm.nih.gov/12747198/>
- [13]. al., D. Z. P. (2009). Clinical observation on 32 cases of lumbar intervertebral disc herniation treated by electro-acupuncture on HuatuoJiaji points. *Journal of Traditional Chinese Medicine*. https://en.cnki.com.cn/Article_en/CJFDTotat-ZZYZ200907016.htm

Dr. SM Shahidul Islam, et. al. "Case Report on Prolapsed Lumbar Intervertebral Disease (PLID) Treatment Through Acupuncture: In Suo Xi Acupuncture Hospital in Bangladesh." *IOSR Journal of Sports and Physical Education (IOSR-JSPE)*, 9(03) (2022): 39-42.