

# Prevalence of Infraspinatus Muscle Atrophy in Professional Badminton Players

I. Sulaiman<sup>1</sup>

Associate professor, Department of Physiotherapy, Dr. B.R. Ambedkar Medical College and Hospital, Bangalore, Karnataka, India

Amir Fazil<sup>2</sup>

BPT Intern, Department of Physiotherapy, Dr. B.R. Ambedkar Medical College and Hospital, Bangalore, Karnataka, India

A.K.Vijay Krishna Kumar<sup>3</sup>

Principal, Department of Physiotherapy, Dr. B.R. Ambedkar Medical College and Hospital, Bangalore, Karnataka, India

---

## ABSTRACT

### BACKGROUND

Badminton is a sport that has been around since the 16th century. The sport is played indoors and the pinnacle comes from its Olympic events. Isolated infraspinatus muscle atrophy is common in overhead athletes, who play significant and repetitive stresses across their dominant shoulders. Several mechanisms have been proposed as etiological factors, including eccentric overload, compressive spinoglenoid notch, paralabral cysts, and cumulative tensile suprascapular neurapraxia. Studies on volleyball, baseball and tennis players report infraspinatus atrophy in 4% to 60% of players; however, the prevalence of infraspinatus atrophy in professional badminton players has not been reported.

### OBJECTIVES

To report the prevalence of infraspinatus muscle atrophy in professional badminton players.

### METHODOLOGY

A cross-sectional study will be conducted among 108 male professional badminton players in the badminton academy, Bangalore. The assessment is done through musculoskeletal screening examination that included visual inspection of the infraspinous fossa. Infraspinatus atrophy was defined as the hollowing or loss of soft tissue bulk inferior to the scapular spine in the infraspinatus fossa of one extremity that was visibly different from the contralateral extremity. Also assessed manual muscle testing for shoulder external rotators and glenohumeral joint range of motion for internal and external rotation.

**RESULT:** The result shows that there is a high prevalence of dominant arm infraspinatus muscle atrophy (53.7%) in male professional badminton players.

**CONCLUSION:** This study concluded that there is high prevalence of infraspinatus muscle atrophy. Players with infraspinatus muscle atrophy have lesser muscle strength and greater external rotation range of motion on their dominant arm comparatively to players without atrophy.

### KEYWORDS

Infraspinatus muscle atrophy, Badminton, overhead athletes, dominant Shoulder.

---

Date of Submission: 20-02-2023

Date of Acceptance: 03-03-2023

---

## I. INTRODUCTION

Badminton is a very popular sport in the world, especially in Asia. It is a sport that combines speed, agility, strength and balance with high accuracy. It requires quick reactions to shots, with the ability to adjust your strategy based on opponent's speed and strength.<sup>(1)</sup>

The infraspinatus muscle is the main rotator cuff muscle in the shoulder. It helps to externally rotate the arm, which allows the elbow joint to move in an upward and outward direction. Infraspinatus muscle injury is a common shoulder injury. It may be caused by sports or other physical activities that involve pulling at the shoulder. This can lead to either a tear or strain of the infraspinatus muscle in the rotator cuff tendons, which connect to the shoulder joint. An injured infraspinatus muscle does not allow for full range of motion of the shoulder joint, which may result in chronic pain, weakness and deformity.<sup>(2)</sup>

Isolated Infraspinatus muscle atrophy is a typical finding in professional overhead athletes, who subject their dominant shoulders to significant and repetitive stress. Infraspinatus function could be compromised by an injury to the suprascapular nerve. As a result of loss of infraspinatus muscle function, scapulothoracic muscle activity and shoulder motion will likely be altered.<sup>(3,4)</sup>

The prevalence of dominant-arm infraspinatus atrophy in the overhead athlete has ranged between 4% and 60% in volleyball, baseball, and tennis players. The pathogenesis of infraspinatus muscle atrophy is multifactorial with eccentric overload, compressive spinoglenoid notch and irritation of the suprascapular nerve at the spinoglenoid notch, however isolated atrophy of the infraspinatus muscle due to an insertional tear of the infraspinatus tendon may also occur.<sup>(2,5)</sup>

The suprascapular and infraspinatus muscles are the most commonly atrophied muscles in suprascapular neuropathy however only Isolated infraspinatus muscle atrophy occurs with isolated suprascapular nerve entrapment occurring distal to the spinoglenoid notch. Compression is defined as primary when it is caused by dynamic entrapment of the nerve whereas it is called secondary when it is provoked by space-occupying lesions, traumatic conditions and systemic conditions.<sup>(5,6)</sup>

To the best of our knowledge, there is no study to determine the prevalence of infraspinatus muscle atrophy in badminton players. This study information may help to report the prevalence of muscle atrophy and guide them to mark the importance of strengthening the shoulder external rotator muscle during training session.

## **II. METHODOLOGY**

**STUDY DESIGN:** Observational study.

**STUDY SETTING:** Badminton academy , Bangalore.

A cross-sectional study will be conducted among 108 male professional badminton players in the badminton academy, Bangalore. The assessment is done through a musculoskeletal screening examination that included visual inspection of the infraspinous fossa. Infraspinatus atrophy was defined as the hollowing or loss of soft tissue bulk inferior to the scapular spine in the infraspinous fossa of one extremity that was visibly different from the contralateral extremity. Also assessed manual muscle testing for shoulder external rotators and glenohumeral joint range of motion for internal and external rotation.

### **INCLUSION CRITERIA**

- Male badminton players
- Age - 18-25years

### **EXCLUSION CRITERIA**

- Any systemic diseases
- Any surgeries in the upper extremities
- Any fracture
- Female badminton players

**SAMPLE SIZE:** 108 badminton players

**SAMPLING METHOD:** Convenient sampling

### **PROCEDURE**

- A cross sectional study will be conducted among 108 male professional badminton players in badminton academy, Bangalore.
- The assessment is done through musculoskeletal screening examination that included visual inspection of the infraspinous fossa.
- Also assessed manual muscle testing for shoulder external rotators and glenohumeral joint range of motion for internal and external rotation.

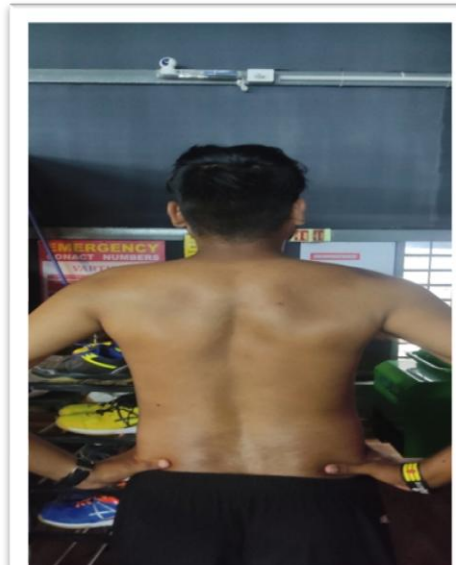
### **VISUAL INSPECTION OF INFRASPINOUS FOSSA**

- Infraspinatus atrophy was defined as a loss of soft tissue mass in the infraspinous fossa of the scapula compared to the contralateral shoulder.
- Each player scapula was evaluated from the rear view in the standing position, with the players feet together for standardization
- The assessment was conducted with players hands on their hip with thumb pointing backwards
- A present/absent classification for infraspinatus atrophy was used to record the findings.

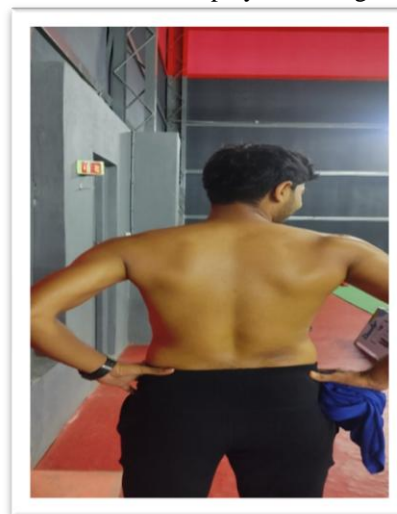
**FIGURE 1:**Posterior view of a professional badminton player with right unilateral infraspinatus atrophy



**FIGURE 2:** Posterior view of a professional badminton player with right unilateral infraspinatus atrophy



**FIGURE 3:** Posterior view of a professional badminton player with right unilateral infraspinatus atrophy



**MANUAL MUSCLE TESTING**

- Instrument assisted manual muscle testing will be performed bilaterally for shoulder external rotators
- Hand held dynamometer is the widely used instrument for MMT as Hand held dynamometer is not cost efficient it has been replaced by a crane scale
- Previous studies have shown that the crane scale is a valid, reliable and affordable alternative to the Hand-held dynamometer
- Crane scale is quick and easy to setup, requiring a ratchet strap, crane scale and pulling handle
- Test was performed with the players in side lying position, side lying wiper external rotation is a novel and effective position for selectively activating the infraspinatus muscle while minimizing the use of posterior deltoid and middle trapezius muscle
- Side lying wiper external rotation, which is performed with the shoulder flexed to 90 degree and supported with opposite hand
- Crane scale pulling handle was aligned at a point 2cm proximal to the ulnar styloid process and placed on the dorsal side of the forearm and the crane scale was stabilized by the examiner
- For each test participant was asked to perform glenohumeral ER against resistance of crane scale
- A “make contraction” was used rather than a “break contraction”, participants were asked gradually build their strength over a 2 second period to maximum voluntary effort and maintain maximum voluntary effort for 5 seconds.
- Recording the best of three trials, by keeping one minute of time period between each of the trials, measurement was recorded in kilogram force(kgf)

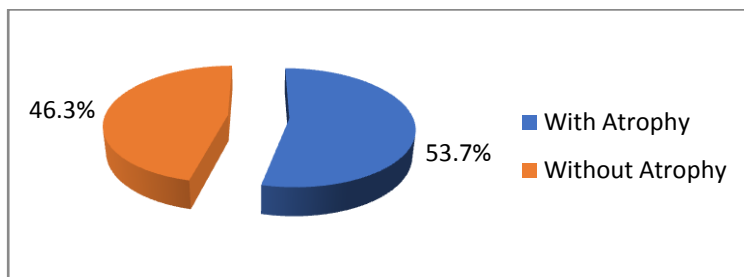
**Range of Motion**

- A standard plastic universal goniometer was used for measurement.
- All measures were performed with the participant in the supine position.
- Bilateral internal and external rotation ROM was measured in 90° of coronal plane abduction with no overpressure used at end ROM. Gravity served as the standard endpoint force.
- The universal goniometer axis was aligned with the long axis of the humerus, with the distal most tip of the olecranon being the superficial landmark for alignment. The stationary arm of the goniometer was placed in a vertical position with the moving arm aligned with the lateral aspect of the ulna.
- From the anatomical zero rotation position in 90" of abduction, the subject were asked to maximally externally rotate their shoulder. Stabilization of the scapulothoracic joint was provided by the examiner via a posteriorly directed containment force by the examiner hand on the coracoid and anterior aspect of the acromion. No allowance for scapular protraction or elevation was permitted. Once the subject achieved a stable endpoint position, the angle was recorded.
- Internal rotation was then measured using identical landmarks for goniometer alignment and stabilization.

**DATA ANALYSIS AND INTERPRETATION**

Statistical analysis of the data was done using SPSS 20.0. Descriptive statistics were calculated and summarized. which includes mean and standard deviation. Inferential statistics had been carried out in the study. Dominant and non-dominant hand comparison with in the group was done using paired t test /Wilcoxon signed rank test and between group comparison was done using unpaired t test/Mann Whitney U test. Level of significance was set at 5%.

**Figure 1:** Representation of sample population with and without infraspinatus muscle atrophy



**Table 1:** showing sample population with and without infraspinatus muscle atrophy

INFRA SPINATUS MUSCLE	NUMBER OF SAMPLES	PERCENTAGE (%)
ATROPHY PRESENT	58	53.7
ATROPHY ABSENT	50	46.3

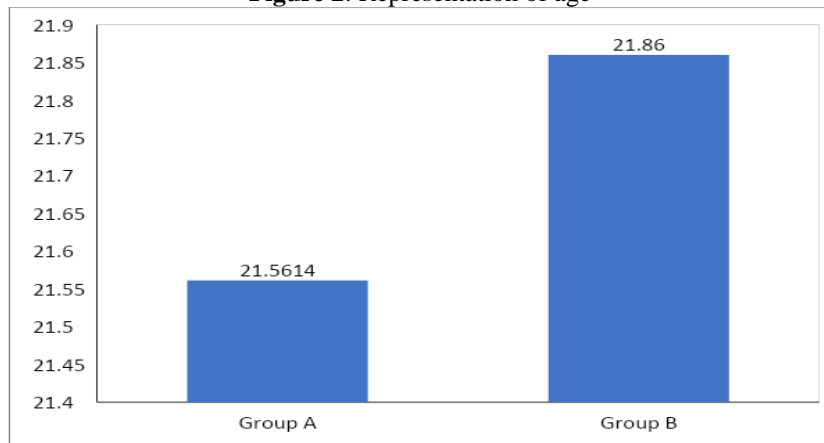
TOTAL	108	100
-------	-----	-----

**Table 2:** Showing mean and standard deviation of age in group A and in group B

Group	Mean	Std. Deviation
With Atrophy	21.5614	1.88052
Without atrophy	21.8600	2.08013

The average age of the Badminton players with atrophy was  $21.561 \pm 1.880$  years and without atrophy it was  $21.86 \pm 2.080$  years.

**Figure 2:** Representation of age

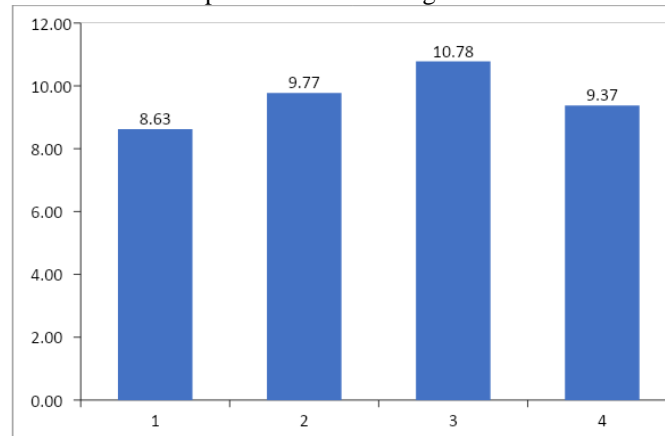


**Table 3:** Showing comparison of Infraspinus muscle strength between dominant and non-dominant hand

	Hand	Mean	Std. Deviation	t value	P value
With Atrophy	Dominant	8.6263	1.92275	4.930	P<0.001
	Non-Dominant	9.7711	2.52638		
Without Atrophy	Dominant	10.7760	2.22505	5.102	P<0.001
	Non-Dominant	9.3740	2.69723		

The Dominant hand Infraspinus muscle strength in badminton players with Atrophy was  $8.62 \pm 1.922$  and in non-dominant hand was  $9.771 \pm 2.526$ . In Non-atrophy group, dominant hand Infraspinus muscle strength was  $10.776 \pm 2.22$  and non-dominant hand was  $9.37 \pm 2.69$ . The analysis shows statistically significant difference in Infraspinus muscle strength between dominant and non-dominant hand of group A and group B with  $p < 0.001$ .

**Figure 3:** Representation of Infraspinus muscle strength in dominant and non-dominant hand.



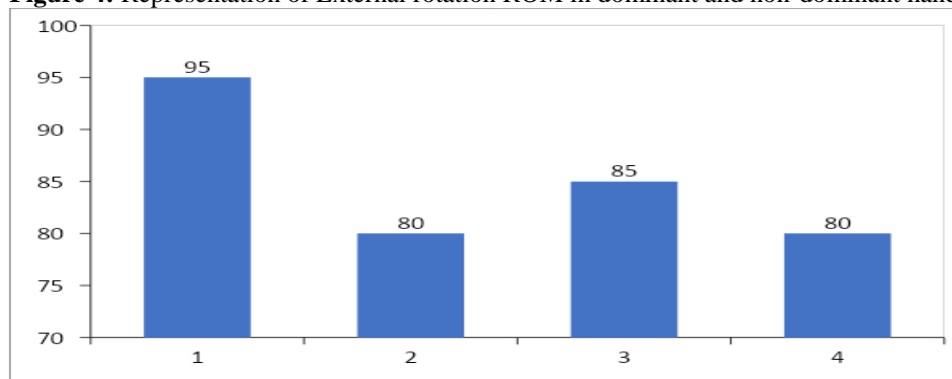
**Table 4:** Showing comparison of External rotation ROM between dominant and non-dominant hand

	Hand	Median	IQR	Z value	P value
With Atrophy	Dominant	95.0	(85.5-105.0)	5.472	P<0.001
	Non-Dominant	80.0	(70.0-92.0)		
Without Atrophy	Dominant	85.0	(75.0-90.5)	1.447	p>0.05
	Non-Dominant	80.0	(73.75-86.5)		

External rotation ROM of dominant hand in badminton players with atrophy showed average ROM 95.0 with inter quartile range 85.5 to 105.0 and non-dominant hand was 80.0 with inter quartile range 70.0 to 92.0 with p<0. 001.This indicate statistically significant difference in External rotation ROM between dominant hand and non-dominant hand.

External rotation ROM of dominant hand in non-atrophy group was 85.0 with inter quartile range 75.0 to 90.5 and in non-dominant hand was 80.0 with inter quartile range 73.75 to 86.5 with p>0.05. The analysis showed no statistically significant difference in External rotation ROM between dominant and non-dominant hand.

**Figure 4:** Representation of External rotation ROM in dominant and non-dominant hand



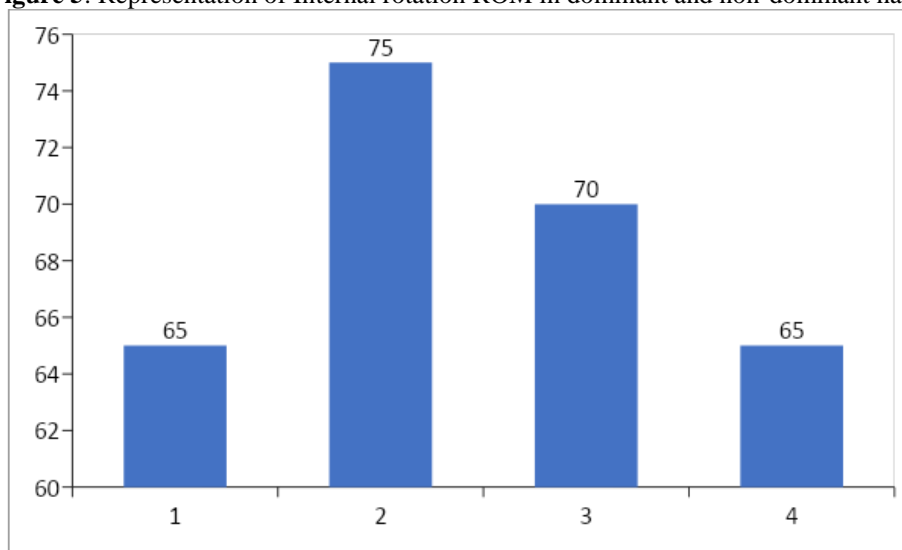
**Table 5:** Showing comparison of Internal rotation ROM between dominant and non-dominant hand

	Hand	Median	IQR	U value	P value
With Atrophy	Dominant	65.0	(55.0-72.0)	5.099	P<0.001
	Non-Dominant	75.0	(67.0-85.0)		
Without Atrophy	Dominant	70.0	(60.0-75.0)	1.416	p>0.05
	Non-Dominant	65.0	(60.0-70.0)		

Internal rotation ROM of dominant hand in badminton players with atrophy showed average ROM 65.0 with inter quartile range 55.0 to 72.0 and non-dominant hand was 75.0 with inter quartile range 67.0 to 85.0 with p<0. 001.This indicate in with atrophy group, internal rotation ROM in non-dominant hand is significantly more than dominant hand.

Internal rotation ROM of dominant hand in non-atrophy group was 70.0 with inter quartile range 60.0 to 75.0 and in non-dominant hand was 65.0 with inter quartile range 60.0 to 70.0 with p>0.05. The analysis showed no statistically significant difference in Internal rotation ROM between dominant and non-dominant hand.

**Figure 5:** Representation of Internal rotation ROM in dominant and non-dominant hand



**Table 6:** Showing comparison of Infraspinatus muscle strength between atrophy and non-atrophy group in Dominant and non-dominant hand

	Group	Mean	Std. Deviation	t value	P value
Dominant	With atrophy	8.626	1.923	5.361	p<0.001
	Without atrophy	10.776	2.225		
Non dominant	With atrophy	9.771	2.526	0.786	p>0.05
	Without atrophy	9.374	2.697		

The Dominant hand Infraspinatus muscle strength in badminton players with Atrophy was  $8.62 \pm 1.922$  and non-atrophy was  $10.776 \pm 2.22$ . The comparison showed Infraspinatus muscle strength of dominant hand significantly differ between with atrophy and without atrophy group ( $p < 0.001$ )

In non-dominant hand Infraspinatus muscle strength was  $9.771 \pm 2.526$  in atrophy group and in non-atrophy group it was  $9.37 \pm 2.69$ . The comparison showed Infraspinatus muscle strength of non-dominant hand does not vary significantly differ between with atrophy and without atrophy group ( $p > 0.05$ )

**Table 7:** Showing comparison of External ROM between atrophy and non-atrophy group in Dominant and non-dominant hand

	Hand	Median	IQR	U value	P value
Dominant hand	With Atrophy	95.0	(85.5-105.0)	4.450	P<0.001
	Without Atrophy	85.0	(75.0-90.5)		
Non dominant hand	With Atrophy	80.0	(70.0-92.0)	0.294	p>0.05
	Without Atrophy	80.0	(73.75-86.5)		

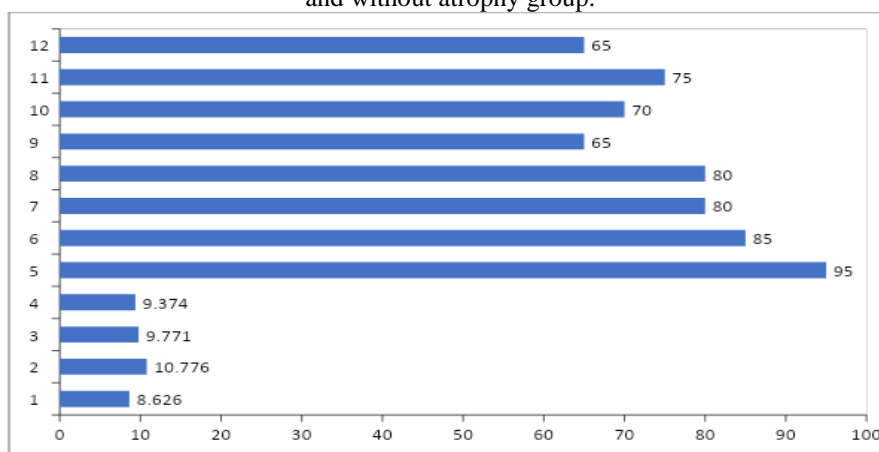
External rotation ROM of dominant hand in badminton players with atrophy showed average ROM 95.0 with inter quartile range 85.5 to 105.0 and in non-atrophy group was 85.0 with inter quartile range 75.0 to 90.5, The  $p < 0.001$  indicated statistically significant difference in external rotation between atrophy and non-atrophy group in their dominant hand. In non-dominant hand external ROM of atrophy group was 80.0 with inter quartile range 70.0 to 92.0 and non-atrophy group was 80.0 with inter quartile range 73.75 to 86.5 with  $p > 0.05$ . The analysis showed no statistically significant difference in External rotation ROM between atrophy and non-atrophy group in their non-dominant hand.

**Table 8:** Showing comparison of Internal ROM between atrophy and non-atrophy group in Dominant and non-dominant hand

	Hand	Median	IQR	U value	P value
Dominant hand	With Atrophy	65.0	(55.0-72.0)	1.625	P>0.05
	Without Atrophy	70.0	(60.0-75.0)		
Non dominant hand	With Atrophy	75.0	(67.0-85.0)	4.593	P<0.001
	Without Atrophy	65.0	(60.0-70.0)		

Internal rotation ROM of dominant hand in badminton players with atrophy showed average ROM 65.0 with inter quartile range 55.0 to 72.0 and in non-atrophy group was 70.0 with inter quartile range 60.0 to 75.0,  $p>0.05$  indicate dominant hand internal ROM does not differ significantly difference between with and without atrophy group. In non-dominant hand internal ROM of atrophy group was 75.0 with inter quartile range 67.0 to 85.00 and non-atrophy group was 65.0 with inter quartile range 60.0 to 70.0. The  $p<0.001$  indicated in non-dominant hand, external rotation in atrophy group is significantly more than non-atrophy group.

**Figure 6:** Representation of Infraspinatus muscle strength, external ROM and internal ROM between atrophy and without atrophy group.



**Table 9:** Showing sample population with atrophy correlating infraspinatus muscle strength with external rotation and internal rotation

With atrophy		External ROM	Internal ROM
Infraspinatus muscle strength	Correlation	-.253	-.029
	Coefficient (r)		
	P value		

No significant correlation was found between infraspinatus muscle strength and external ROM and infraspinatus muscle and internal ROM.

**Table 10:** Showing sample population without atrophy correlating infraspinatus muscle strength with external rotation and internal rotation.

Without atrophy			External ROM	Internal ROM
Infraspinatus muscle strength	Correlation		-.001	-.142
	Coefficient (r)			
	P value			

No significant correlation was found between infraspinatus muscle strength and external ROM and infraspinatus muscle and internal ROM.



### III. Discussion

This study describes the prevalence of infraspinatus muscle atrophy in professional badminton players. In the total sample population of 108 players with dominant arm infraspinatus muscle atrophy were 58(53.7%), players without infraspinatus muscle atrophy in their dominant arm were 50(46.3%). In addition to the prevalence the present study also found infraspinatus muscle strength and glenohumeral external and internal ROM measurements.

Previous study shows that, volleyball players had the highest prevalence of infraspinatus atrophy in the sports medicine literature, ranging between 13% and 34%.<sup>[7,8,9,10,11,12]</sup> Todd S. EllenBecker et al reported a very high prevalence of dominant arm infraspinatus muscle atrophy (61.1%) in male professional tennis players.<sup>[3]</sup>

In this study the average infraspinatus muscle strength of dominant arm with atrophy was  $8.62 \pm 1.92$  and dominant arm without atrophy was  $10.776 \pm 2.22$ . This statical analysis shows infraspinatus muscle strength of dominant arm significantly differ between with atrophy and without atrophy( $p < 0.001$ ).

With reference to prior studies our study also shows similar result that dominant arm muscle strength with atrophy is weaker than without atrophy.<sup>[1,10,13]</sup> The average external rotation rom of dominant arm with atrophy was 95 degrees with interquartile range 85.5-105, the average ER dominant arm without atrophy was 85 degrees with interquartile range 75-95 degree. This statistical analysis shows that there is significant difference in external rotation between atrophy and non-atrophy players in their dominant arm( $p < 0.001$ ). The average Internal rotation ROM of dominant arm with atrophy was 65 degrees with interquartile range 55-72, the average internal rotation of dominant arm without atrophy was 70 degrees with interquartile range 55-72 degrees. This statistical analysis shows that there is no significant difference in internal rotation between atrophy and non-atrophy players in their dominant arm ( $p > 0.05$ ).

The present study also shows there is no significant correlation between infraspinatus muscle strength and external ROM ( $r = -.253$ ) as well as infraspinatus muscle strength and internal ROM ( $r = -.029$ ), since  $r$  is very less it is a weak correlation. The common finding of dominant-arm infraspinatus atrophy in badminton players and its correlation with external rotation weakness indicates a possible need for external rotation strengthening interventions. Weakness of the external rotators and, specifically, decreases in the ratio of external to internal muscle strength have been linked to shoulder injury in professional overhead athletes.

This study was done by visual observation alone to identify infraspinatus muscle atrophy. Limitation of this study was that, no additional imaging was done to validate the visual appearance of hollowing as a true measure of muscle atrophy or to quantify the degree of atrophy. Additionally, objective measure of suprascapular nerve function with electrophysiologic testing.

### IV. Conclusion

Visual observation of infraspinatus muscle atrophy in sample of 108 male professional badminton players identified apparent infraspinatus muscle atrophy in 58 players (53.7%) on the dominant extremity. From this study we concluded that there is high prevalence of infraspinatus muscle atrophy. Players with infraspinatus muscle atrophy have lesser muscle strength and greater external rotation range of motion on their dominant arm comparatively to players without atrophy.

Based on the results of this study, the finding of dominant-arm infraspinatus atrophy is common in professional badminton players but, given the correlation with external rotation weakness, may indicate the need for focused external rotation strengthening and clinical monitoring. Infraspinatus muscle atrophy can be prevented by giving emphasis on strengthening exercises of external rotator of dominant shoulder.

### References

- [1]. Phomsoupha M, Laffaye G. The science of badminton: game characteristics, anthropometry, physiology, visual fitness and biomechanics. *Sports medicine*. 2015 Apr;45(4):473-95
- [2]. Williams, Justin M., Margaret A. Sinkler, and William Obremsky. "Anatomy, shoulder and upper limb, infraspinatus muscle." (2018).
- [3]. Ellenbecker TS, Dines DM, Renstrom PA, Windler GS. Visual observation of apparent infraspinatus muscle atrophy in male professional tennis players. *Orthopaedic Journal of Sports Medicine*. 2020 Oct 27;8(10):2325967120958834.
- [4]. Contemori S, Biscarini A. Isolated infraspinatus atrophy secondary to suprascapular nerve neuropathy results in altered shoulder muscles activity. *Journal of Sport Rehabilitation*. 2019 Mar 1;28(3):219-28.
- [5]. Kolbe AB, Collins MS, Sperling JW. Severe atrophy and fatty degeneration of the infraspinatus muscle due to isolated infraspinatus tendon tear. *Skeletal radiology*. 2012 Jan;41(1):107-10.
- [6]. Bozzi F, Alabau-Rodriguez S, Barrera-Ochoa S, Ateschrang A, Schreiner AJ, Monllau JC, Perelli S. Suprascapular neuropathy around the shoulder: A current concept review. *Journal of Clinical Medicine*. 2020 Jul 22;9(8):2331.
- [7]. Ferretti AN, Cerullo GU, RUso GI. Suprascapular neuropathy in volleyball players. *JBJS*. 1987 Feb 1;69(2):260-3.
- [8]. Holzgraefe M, Kukowski B, Eggert S. Prevalence of latent and manifest suprascapular neuropathy in highperformance volleyball players. *Br J Sports Med*. 1994;28(3):177-17.
- [9]. Lajtai G, Pfirrmann CWA, Aitzetmüller G, Pirkl C, Gerber C, Jost B. The shoulders of professional beach volleyball players: high prevalence of infraspinatus muscle atrophy. *Am J Sports Med*. 2009;37(7):1375-1383.

- [10]. Lajtai G, Wieser K, Ofner M, Raimann G, Aitzetmüller G, Jost B. Electromyography and nerve conduction velocity for the evaluation of the infraspinatus muscle and the suprascapular nerve in professional beach volleyball players. *Am J Sports Med.* 2012;40(10):2303–2308.
- [11]. Salles JI, Cossich VRA, Amaral MV, et al. Electrophysiological correlates of the threshold to detection of passive motion: an investigation in professional volleyball athletes with and without atrophy of the infraspinatus muscle. *Biomed Res Int.* 2013; 2013:634891
- [12]. Witvrouw E, Cools A, Lysens R, et al. Suprascapular neuropathy in volleyball players. *Br J Sports Med.* 2003;34(3):174–180.
- [13]. Young SW, Dakic J, Stroia K, Nguyen ML, Harris AHS, Safran MR. Hip range of motion and association with injury in female professional tennis players. *Am J Sports Med.* 2014;42(11):2654–2658.

I. Sulaiman, et. al. "Prevalence of Infraspinatus Muscle Atrophy in Professional Badminton Players." *IOSR Journal of Sports and Physical Education (IOSR-JSPE)* 10(2), (2023): pp. 01-10.