

Assessment of the Effect of *Cannabis sativa* and *Nicotiana tobacum* Leaves on some Haematological and Liver Function Indices of Albino Rats.

Dasofunjo K^a, Okwari, O. O.^b; Obembe A.O.^c, Olatunji T.L.^d Ezugwu H.C.^e and Osim, E. E.^c

^aDepartment of Medical Biochemistry, Cross River University of Technology, Okuku, ,Nigeria.

^bDepartment of Human Physiology, Cross River University of Technology, Okuku ,Nigeria.

^cDepartment of Human Physiology, University of Calabar, Calabar, Nigeria.

^dDepartment of Plant Biology, University of Ilorin ,Ilorin, Nigeria

^eDepartment of Chemical Sciences, University of Mkar, Mkar, Nigeria

Abstract: The effect of marijuana and tobacco leaves on male albino rats haematological and liver functional indices were investigated. Twenty (20) male albino rats were randomly grouped into four (4) A, B, C and D. Rats in B, C and D were administered with marijuana, tobacco and mixture of marijuana and tobacco respectively in the ratio 3:1 after an acclimatization period of 7 days. Rats in group A served as the control and were administered with standard feeds and water only. Their weights were monitored on daily bases with their consumption rate inclusive. The rats were sacrificed after an experimental period of 14 days. The haematocrit (PCV) and haemoglobin concentration showed a significant decrease ($p < 0.05$). Total protein produces a significant increase ($p < 0.05$) with rats administered with marijuana while tobacco and mixture of tobacco and marijuana shows a significant decrease ($p < 0.05$). Albumin gives a significant decrease ($p < 0.05$). Globulin produce an increase ($p < 0.05$) in for both marijuana and tobacco but modulates a decrease ($p < 0.05$) in mixture of tobacco and marijuana, serum AST and ALP produce a significant increase ($p < 0.05$) with marijuana and mixture of marijuana and tobacco. A significant increase ($p < 0.05$) was observed from liver AST and ALP. A drastic reduction was observed in weight of rats administered with marijuana, tobacco and mixture of marijuana and tobacco. The alterations in haematological and liver function indices are indications of dishaematopoetic potential, pathological condition and impairment on the liver.

Keywords: *Cannabis sativa*, dishaematopoetic potential, haematological ,*Nicotiana tobacum*, and pathological condition

I. Introduction

Drugs produce harmful as well as beneficial effects and the decision on when and how to use them involved the balancing of benefits and risks action . These drugs are usually taken to alter mood and are called psychoactive drugs. The psychoactive drugs are self-administered resulting in overdose administration with deadly consequence of drug abuse [1]. Drugs are also chemical substances that change the way our bodies work. When they are administered to the body (often by swallowing, inhaling, or injecting them), drugs find their way into our bloodstream and are transported to other parts of body. In the brain, drugs may either stimulate or depress our alertness, and sometimes decrease physical pain [2]. All psychoactive drugs have one feature in common, that is, they produce their effects by acting in some way on nervous system tissues. Most of these actions occur at the level of the brain. This is by binding of the molecules to the receptor sites, thus duping the receptor into reacting as if the natural transmitter is present and stimulating the neurons, such drugs are morphine, marijuana, nicotine, heroin are now thought to act by mimicking natural neurotransmitter called endorphins [3]. Drugs generally have effect on both animals and humans by either stimulating or depressing the activity in the systems of living cells. *Cannabis sativa* (marijuana) and *Nicotiana tobacum* (tobacco) are common drugs known today and the drugs have side effect on living cells of the system [4].

Marijuana (*Cannabis sativa*) is commonly known as **pot, grass, cannabis, weed, hemp** and it is medically known as **cannabis sativa, delta-9-tetrahydrocannabinol (THC), cannabinoid** [5]. *Cannabis sativa* is an annual plant belonging to the family *cannabaceae* of the nettle order (urticales) it grows wild in warm and tropical climates throughout the world and is cultivated commercially .It is commonly known today as psychoactive substance, but for many years it was harvested primarily for its fiber [6]. The leaves and buds of the plant have been used in herbal remedies for centuries. Scientists have identified (66) sixty six biologically active ingredients called cannabinoid, in marijuana. The most potent of these is thought to be the chemical delta-9-tetrahydrocannabinol, or THC, although other active substances are being tested [7].

The primary psychotropic action of marijuana occur in the brain and it result to drugs effect on neurotransmitters [8]. Much research has focused on the effects of marijuana on the chemical transmitter acetylcholine that is, when THC is in a relatively small (dose) it decrease the turnover in acetylcholine, particularly in the hippocampus resulting in decrease in neurotransmitter activity [8].Cannabis has been shown to decrease intraocular pressure, although patients have experienced side effects regardless of whether the cannabis was administered orally through injection, or by smoking [4]. These side effects have included increase heart rate and psychological effects [4].Cannabis preparations have been used to relieve nausea, improve appetite and reduce pain for thousand years [2]. Cannabinoid is also used in treatment of glaucoma which is the leading cause of blindness in the world [9].Positive outcomes have continued to emerge in subsequent researches, there are indications that children undergoing cancer chemotherapy may particularly benefit from administration of orally administered high dose of cannabinoid [10]. Selective cannabinoid receptor antagonists are in development for the treatment of obesity and tobacco smoking, and could be tested for antidepressant efficacy because recent results of clinical studies suggest that they would also treat co morbid symptoms of depression such as cognitive deficiencies, weight gain, and impulsivity and dependence disorders [10].

Tobacco (*Nicotianatobacum*) on the other hand, is a broad-leafed plant of the nightshade family. It is an annual plant of the family *campanulaceae*. It is indigenous to North and South America [11].Tobacco has many constituents, but nicotine is singled out as having the broadest and most immediate pharmacological action [12]. Nicotine is extremely toxic, about as toxic cyanide, and only sixty (60) mg are needed to kill humans but while smoking tobacco, it has a small portion of nicotine which the body metabolize to a non-toxic substance. Nicotine has major CNS stimulant, although these effects are not as intense as what is observed with cocaine and amphetamines but nicotine enhance effect on alertness, learning, and memory [12]. These effects may account for part of nicotine reinforcing effects in humans' .Nicotine has an autonomic effect, particularly on the cardiovascular system [2]. The stimulation of the heart and its resultant increased demand for oxygen underlie the association of nicotine and disease. In the cause of the failure to deliver an adequate supply of oxygen to the heart may result in chest pain (angina) or a heart attack [13]. One of the famous acute effects of nicotine is its relationship to lower body weight [14]. In this regard, nicotine decrease appetite for sweet foods and increase the amount of energy the body uses both while resting and exercising [15]. These features of nicotine helps to explain the research which show that smokers tend to weigh less than non-smokers. Alternatively, quitting from smoking is associated with weight gain [10]. Smoking during pregnancy poses a serious health concern to the developing fetus, growth and development [16].The nicotine signal through muscle-type and neuronal nicotine acetylcholine receptors in both human bronchial epithelial cells and air way fibroblasts [17]. According to [17], suggested that, muscle-type and neuronal-type nicotine acetylcholine receptors are functional in air way fibroblasts and human bronchial epithelial (HBE) cells, that prior tobacco exposure does not appear to be an important variable in nAChRs expression, and that distinct signaling pathways are observed in response to nicotine. Therefore, the overall aim of this study is to determine the effect of *cannabis sativa* and *nicotiana tobacum* leaves on the liver function indices and some haematological parameters.

II. Materials And Methods

PLANT MATERIALS

Marijuana leaves (*Cannabis sativa*) were obtained by permission from the Nigerian Drug and Law Enforcement Agency (NDLEA) Yandev, Benue State of Nigeria. While the tobacco leaves (*Nicotiana tobacum*) were obtained from Abintse along Makurdi-Gboko road, Benue state of Nigeria.

ASSAY KITS

The assay kits for Albumin, Globulin, Alkaline Phosphatase (ALP), Aspartate Amino Transferase (AST) were obtained from Randox Laboratories, Ltd, United Kingdom. Total protein concentration of the samples was assayed by the Biuret method [18]. All other reagents used were of analytical grade and were prepared in glass distilled water.

EXPERIMENTAL ANIMALS

Albino rats were obtained from the animal holding unit, department of chemical sciences, University of Mkar, Mkar. Nigeria. The animals were allowed to undergo an acclimatization period of seven days. Each rat was housed in a wooden cage. The animals was adequately kept at room temperature and relative humidity of $29 \pm 27^{\circ}\text{c}$ and 40-70% respectively with 12 hours natural light-dark cycle and were fed *adlibitum*. Good hygiene was maintained by constant cleaning and removal of faeces and spilled from cages daily.

PREPARATION OF THE PLANT MATERIALS

The leaves of marijuana and tobacco were collected and air dried separately for ten (10) days until a constant weight was obtained. The dried leaves were then pulverized and sieved.

ANIMALS GROUPING

A total of twenty (20) male albino rats with an average weight of 260 ± 3.00 were used for the study. They were randomly grouped into four: A, B, C and D. Animals in group A served as the control while those in group B, C and D served as test animals that were given marijuana leaves, tobacco leaves and mixture of marijuana and tobacco leaves respectively.

ADMINISTRATION OF MARIJUANA AND TOBACCO LEAVES

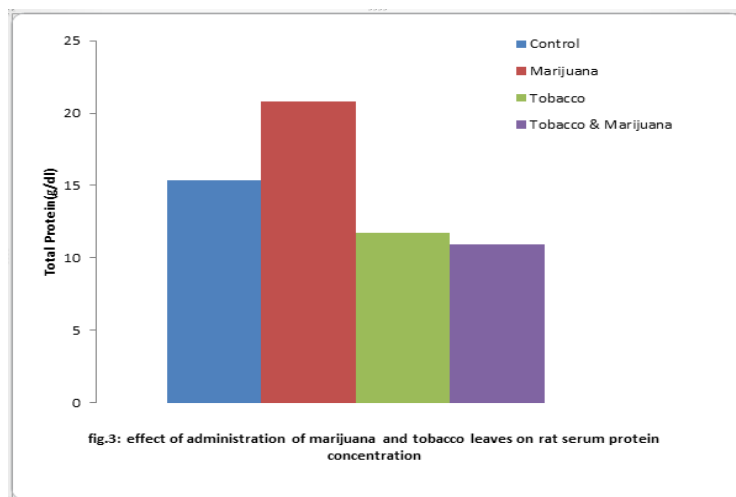
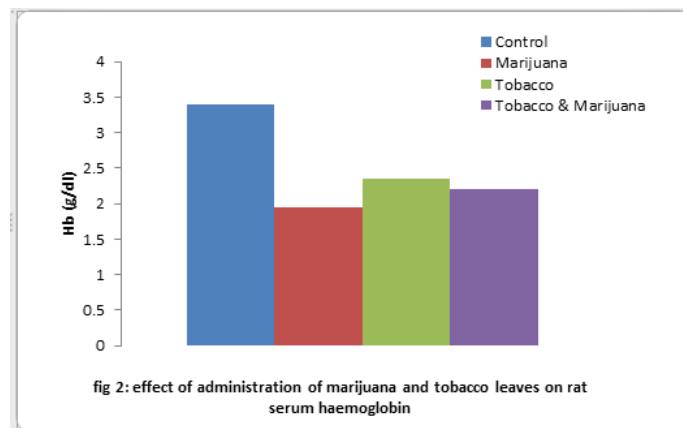
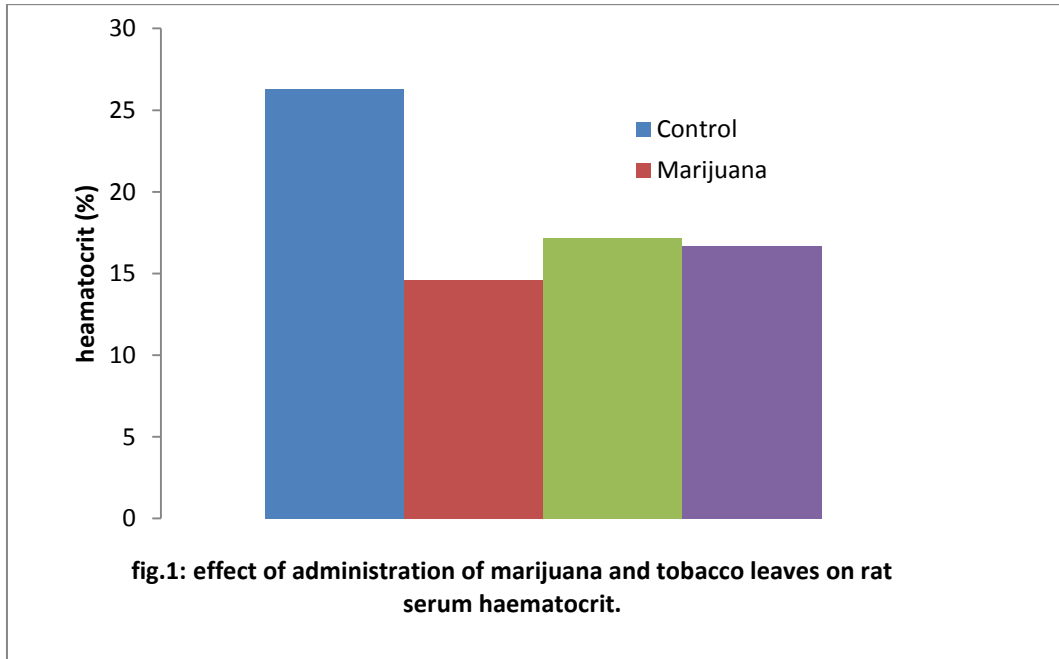
The animals in group A were administered with tap water and standard feeds from Grand Cereals and Oil Mills Limited, Gboko, Benue State while those in B, C and D were administered with the standard feeds and marijuana, standard feeds and tobacco and mixture of marijuana and tobacco respectively in ratio 3:1 (48:16)g. each group were fed *ad libitum* throughout the experimental period of fourteen (14) days and their respective weight were measured on daily base. All animals were sacrificed after the experimental period.

PREPARATION OF SERUM AND TISSUE HOMOGENATE

The animals were anaesthetized in a jar containing Cotton wool soaked in ether. When the rats became unconscious, they were quickly brought out of the jar. The abdominal region was then cut sharply with sterile scalpel blade to expose the organs and the blood was collected into a sterile bottle by cardiac puncture. The coagulated blood was then centrifuged at 3000 rpm for 5 minutes to give a clear supernatant (serum) which was aspirated with Pasteur pipette, store in sample bottles and used within 12 hours of preparation. Each of the organs was cut with a clean sterile blade and then homogenized in ice-cold 0.25M sucrose solution 1:5 w/v [18]. The homogenate were kept frozen over night at 20°C before being used for the biochemical assay.

III. Results

Figure 1 and 2 shows the effect of administration of marijuana, tobacco, and the mixture of marijuana and tobacco leaves on some selected haematological parameters. The administration of marijuana, tobacco, and the mixture of marijuana and tobacco shows a significant reduction ($p < 0.05$) for both the haematocrit (PCV) and haemoglobin when compared with the control following the administration of the leaves. The administration of marijuana, tobacco and mixture of tobacco and marijuana on serum protein concentration for both tobacco and marijuana shows a significant reduction ($p < 0.05$) with the exception of marijuana which shows a contrast with a significant increase when compared with the control (Fig.3). Figure 4 shows the effect of marijuana, tobacco leaves and mixture of tobacco and marijuana on rat serum albumin concentration. The administration of marijuana, tobacco and mixture of tobacco and marijuana shows a significant decrease ($p < 0.05$) when compared with control (fig 4).



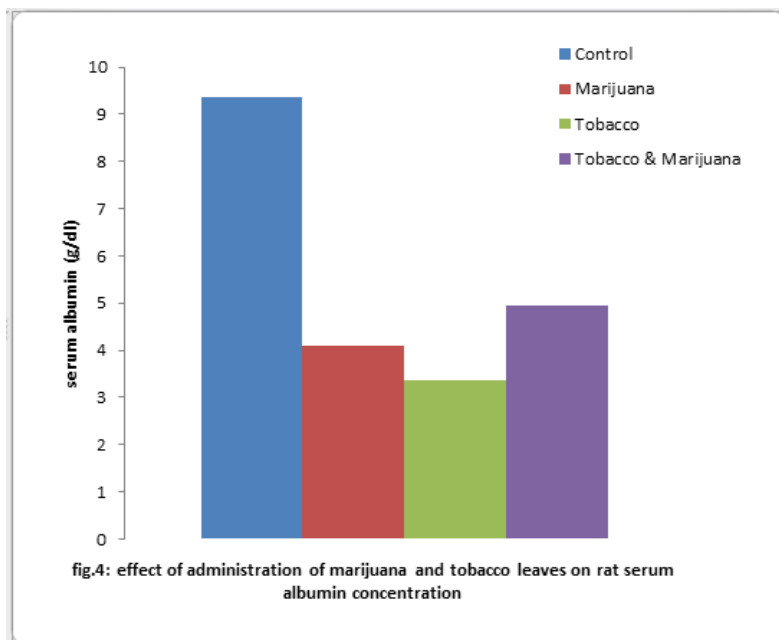
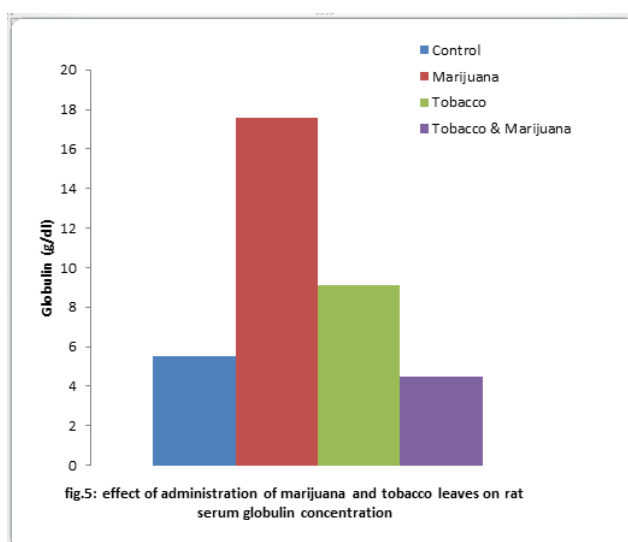
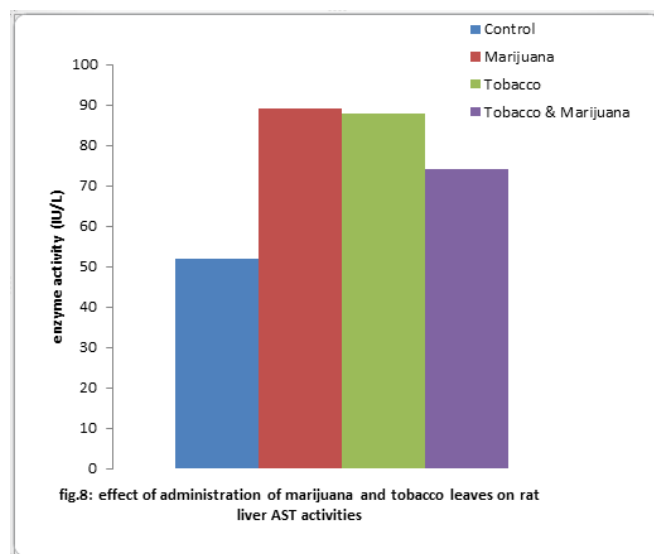
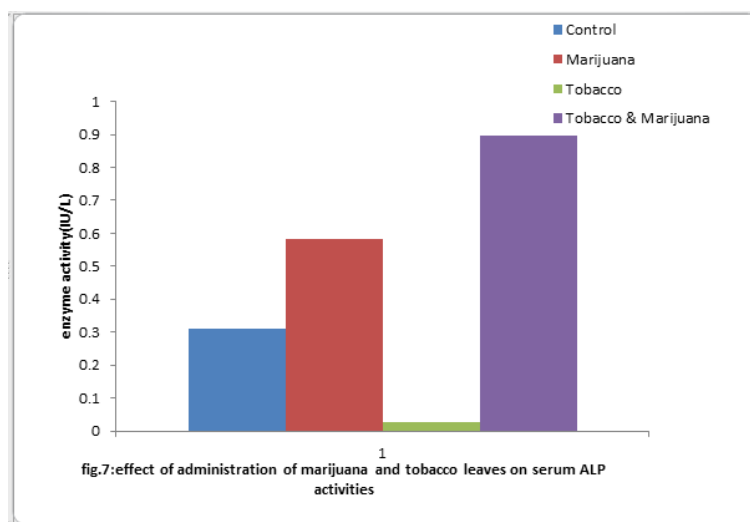
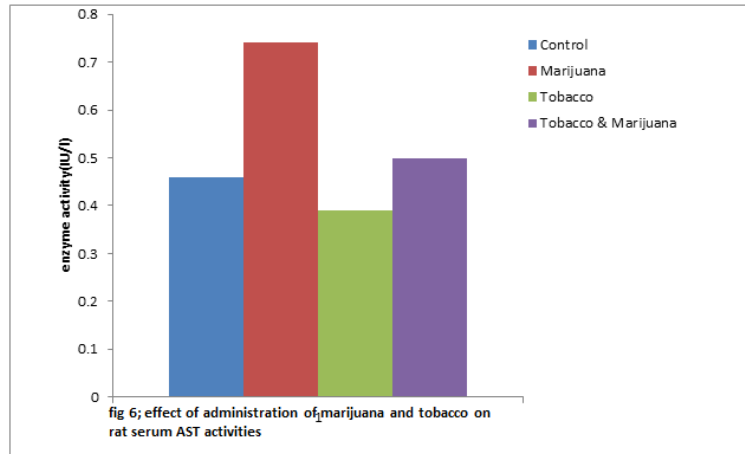
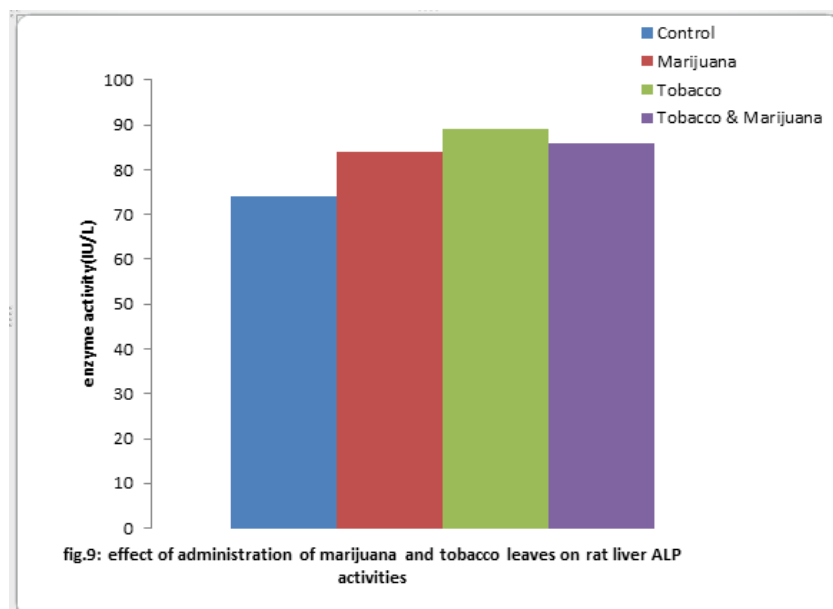


Figure 5 shows the administration of marijuana, tobacco and mixture of marijuana and tobacco on rat serum globulin concentration. The rats administered with marijuana and tobacco shows a significant increase ($p < 0.05$) when compared with the control while the rats administered with the mixture of marijuana and tobacco shows a significant reduction ($p < 0.05$) (fig 5). Figure 6 shows the effect of administration of marijuana and tobacco on rat serum AST activities. Rats administered with marijuana and mixture of tobacco and marijuana shows a significant increase ($p < 0.05$) while those administered only with tobacco shows a significant decrease ($p < 0.05$) on serum AST activities, when compared with the control. Figure 7 shows the effect of marijuana and tobacco leaves on serum ALP activities. These shows a significant increase ($p < 0.05$) on serum ALP activities of rats administered with marijuana and mixture of marijuana and tobacco respectively. Alternatively, rats administered with tobacco shows a significant decrease ($p < 0.05$) in serum ALP activities when compared with the control. The effect of marijuana and tobacco leaves on rats liver AST activities shows significant increase ($p < 0.05$) with rats administered with marijuana, tobacco and mixture of marijuana and tobacco leaves when compared with the control (Fig. 8). Likewise, a significant increase ($p < 0.05$) was observed from rats liver ALP activities following the administration of marijuana, tobacco and mixture of tobacco and marijuana respectively when compared with the control (Fig. 9)







IV. Discussion.

The assessment of haematological parameters in rats can be used to determine the extent of deleterious effect of a plant extract on animal blood [19]. These haematological parameters (haemoglobin concentration and haematocrit) values provide information on the general state of the blood chemistry [20]. It is inferred from this study that marijuana, tobacco and mixture of marijuana and tobacco leaves may have a toxic effect on the hematological parameters by altering the blood chemistry. Hence, inducing anemia by causing bone marrow depression through inadequate production of red blood cells [21] and ultimately cells death [22,23]. This may also be attributed to drastic loss in weight of these rats throughout the experimental period. Therefore, the leaves may have no hematopoietic potential since it has a direct effect on the hematopoietic and erythropoietin system. The liver function indices commonly assess liver injury rather than hepatic functions. It also reflects problems arising in the liver. The significant increase and decrease in serum total protein for rats administered with marijuana, tobacco and mixture of tobacco and marijuana is an indication of a pathological condition on the liver Albumin series in the maintenance of osmotic pressure of the blood and body fluids and transport of inorganic anions, fatty acids and drugs. Therefore, decrease in serum albumin level in rats administered with tobacco and mixture of marijuana and tobacco might have affected the metabolism of this substance that is transported by it. Also, the increase in the level of albumin for marijuana suggests that there was an increased protein synthesis or mobilization. The significant increase in the level of globulin following the administration of the plants might be due to impairment on the liver function or a pathological condition on the liver.

The biochemical indices monitored in the liver are useful 'maker' for assessment of tissue damage. The measurement of activities of various enzymes in the tissue and body fluids plays a significant role in disease investigation and diagnosis [24], assault on the organs/tissue, and to a reasonable extent the toxicity of the extract [25]. Tissue enzymes can indicate tissue cellular damage cause by chemical compounds, long before structural damage that can be picked by conventional histological technique.

Alkaline phosphatase (ALP) is a 'maker' enzyme for the plasma membrane and endoplasmic reticulum [26]. The increase in activity of serum ALP might be due to the leakage of the enzyme from the tissue into the serum. These suggest tissue damage such as cardiac infection; muscle injury and hepatic necrosis. Aspartate amino transaminase is localized within the cells of the liver, heart, gills, kidney, muscles and some other organs. The enzyme is mostly important in assessing and monitoring liver cytolysis. The significant increase in both serum and liver AST following the administration of the leaves could be due to denovo synthesis of the enzyme molecule leading to an activity higher than the control [27]. The increase in serum AST also suggests a pathological condition on the liver.

V. Conclusion.

The various alterations in the haematological parameters and liver functional indices of liver which do not compare favourably with the control values are manifestation of adverse effect on haematological and liver functional parameters evaluated following the administration of the plants. The effects are indications of a disheamatopoietic and erythropoietic potential. The effects also include an indication of impairment, and assault to the liver. This study has also supported the speculations that consumptions of herbal preparations may

contribute to increasing incidence of liver failure. Therefore, casual usage of these leaves by addicts is unsafe and inimical to healthy being. Its usage therapeutically should be done with caution and appropriate dosage.

References

- [1] J.H. Jaffe...Drug addiction and drug abuse. In A. G. Gilman, T.W Rall, S. Nies, & P. Taylor (Eds.), The pharmacological base of therapeutics (8th ed) . New York: pergamon press. 1990
- [2]. H.Checkoway, K. , Powers, , T. Smith-Weller, G.M.Franklin.W.T. , Longstreth.Jr, P.D. Swanson, Parkinson's disease risk associate with cigarette Smoking. Alcohol consumption, and caffeine intake. *Am J. Epidemiol*155, 2002, 732-738.
- [3] W.D. Hall,W. Swift,. The policy implications of cannabis dependence in:Roffman, R.A, Stephen, R.S., Editors. Cambridge University press (UK) Pp. 315-339., 2006.
- [4]. R.S .Helper., and R.J. Petrus., (1996). Experiences with administration of Marijuana to glaucoma patients. In S. Cohen & R.C. Stillman (Eds.), The therapeutic aspects of marijuana (Pp. 63-75). New York: Plenum Press
- [5] J.E. Joy,,S.J. Watson,and JAJ Benson,,Marijana and medicine: As The science Base Washinton DC: National academic press,1999
- [6]. S.Sussman , A.W. Stacy, C.W. Dent, T.R. Simon,, and C.A. Johnson, Marijuana use : current issues and new research directions. *Journal of Drug issues*, 26;1996,695-733.
- [7] Nathan, P.E.. Substance use disorders in the DSM-IV. *Journal of abnormal Psychology*, 100: 1991,356-361
- [8], M.J. Marks , J.R.Pauly, S.D. Gross, E.S.Dennis, Hemans-Borgmeyer, I,Heinemann, S.F.,and Collins, A.A. Nicotine binding and nicotinic Receptor subunit RNA after chronic nicotine treatment. *Journal of Neuro-science*. 12: 1992,2765-2784
- [9], LKe., , C.E. Eisenhour, , M. Bencherif, , R.J Lukas.. Effect of chronic nicotine Treatment on expression and function of diverse nicotinic receptor sub-Type, 1 dose- and time dependent effects of nicotine treatment.*Pharmacol. Exp. Ther.* 286, 1998,825-840
- [10] A.W Meyer, R.C.Klesges , S.E Winders., K.D Ward.,B.A. Peterson,, and, I.H Eck. . Are weight concerns predictive of smoking cessation? A Prospective analysis. *Journal of consulting and clinical psychology*, 6: 1997,448-452
- [11], H.C Miller., Hassanien, K., , P.A. Hensleigh.. Fetal growth retardation in Relation to maternal smoking and weight gain in pregnancy.*Am J. Obstetric Gynecol* 125: 1996, 55-60
- [12] S.J.Heishman,, R.C.Taylor, and, J.E. Heniningfield. Nicotine and Smoking: A review of effects on human performance. *Experimental and Clinical Psychopharmacology*,2: 1994,345-395.
- [13], L.C. Diane , M.H. Toni , G.D. Autumn , J.S. Michele , D.L. James , A.C. Neil., and M.S Jill, Nicotine signals through muscletypes and neuronal Nicotinic acetylcholine receptor in both human bronchial epithelial cells and air way fibroblast". *Respiratory Research*.10 :2004,1186/1465-9921.
- [14], R.MJulien.. A primer of drug action (7thed).New York: W.H.Freeman& co. 1996
- [15], TVik., , G Jacobsen., L Vetten,, , L.S Bakketeig..Pre and post- natal growth In children of women who smoked in pregnancy. *Early Hum.Dev.* 45: 1996,245-255.
- [16], J.MWehner., , J.J. Keller, A.B. Keller., , R.Paylor, T.K Booker,, , S.F Heinemann., S.A .Balogh.. "Role of neuronal nicotinic receptors in the effects of nicotine and ethanol on contextual fear conditioning".*Neuroscience* Volume 129: 2004,11-24.
- [17] I.B. Adams, and, B. R .Martin.. Cannabis: Pharmacology and toxicology in Animals and humans. *Addiction*, 91:1996,1585-1614.
- [18] E.O.Ngaha, M.A.Akanji, and, M.AMadusolumuo..Studies on correlation between chloroquine induced tissue damage and serum change in rats Experience; 45- 143. 1989
- [19], G.O.Obochi, S.PMalu, N.O, Alobi., A.MIyam., and, YAlozie.. Effect of Aspartame and sucrose on some biochemical and haematological Parameters inWisterAlbino Rats. *Global journal of pure and applied Sciences*. 15: 2008,47-52.
- [20], M.T.Yakubu, M.A.Akanji,, A.T. Oladiji.. Haematological evaluation in male Albino rats following chronic administration of aqueous extract of Fadogiaagrestis stem. *Pharmacog. Mag.* 3: 2007,,34-38
- [21], E.BDede and H.OKagbe, A study on the acute toxicological effect of Commercial diesel fuel in Nigeria in rats (*Ratusratus*) using Haematological parameters. *J. Applied sci. Environ. Mgt* 6;2002, 84-86.
- [22] Adedapo, A.A., Abatan, M.O., Olorunsogo, O.O. (2004).Toxic effects of some Plants in the genus Euphorbia on haematological and biochemical Parameters of rats. *Vet Arhiv* 74:53-62.
- [23] Adedapo, A.A., Abatan, M.O., Olorunsogo, O.O. (2007a). effects of some plants of the spurge family on the haematological and biochemical parameters of rats. *Vet Arhiv* 77: 29-38.
- [24].. Malomo, S.O (2000). Toxicological implication of ceftriaxon administration in Rats.Nig J Biochem. Mol. Biol. 15 (1): 33-38.
- [25] Yakubu, M.T.,Bilbis, L.S., Lawal, M.andAkanji, M.A. (2003). Evaluation of Selected parameters of rats liver and kidney function following repeated Administration of yohimbin*Biochemistri*. 15 (2): 50-56.
- [26] Wright, P.J. and Plummer, D.T. (1974). The use of urinary enzymes measurement todetect renal damage cause by nephrotoxic compound- *biochem. Pharmacol* 12: 65.
- [27] Yakubu, M.T., Akanji, M.A., Salau, I.O. (2001). Protective effect of ascorbic acid on Some selectedtissues of ranitidine treated rats. *Nig. J. Biochem Mol. Biol*16 (2): 177-182.