

Effect of Graviola Leaves Extract on Nicotine Induced Reproductive Damages In Male Albino Rats.

El-Sawi, M.R.¹; Abou-El-Naga, A. M.²; Atta, M. S.³ and Shalaby, S. A⁴.

1 & 2: Zoology Department, Faculty of Science, Mansoura University, Egypt

3: Faculty of veterinary, Kafr El-Sheikh University, Kafr El-Sheikh, Egypt.

Abstract:

Nicotine (NIT) is the main ingredient of cigarette smoke that has harmful effects on reproductive system of both sexes and reduced fertility. However, the major cause of male infertility is the oxidative stress. Also, NIT caused depression in semen parameters, male hormones and apoptotic markers which led to male infertility. Graviola leaves extract (GLE) has many antioxidants that can treat hyperlipidemia, hematological and fertility disorders caused by NIT. The current study was done to assess the influence of NIT on the rat testes and also to clarify the possible protective and therapeutic effects of GLE against NIT induced testicular damages in male rats. Thirty male albino rats were classified into five groups (containing 6 animals in each) as follows: group I which served as control: rats were received saline solution only; group II: received orally GLE (200 mg/kg bw daily, for 1 month); group III: injected subcutaneously with NIT (0.6 mg/kg bw daily, for 1 month); group IV: received orally GLE daily, for 1 month and then injected subcutaneously with NIT daily, for another 1 month; group V: injected subcutaneously with NIT daily, for 1 month and then received orally GLE daily, for another 1 month. Serum and homogenate of testes were assayed for CAT, SOD, GSH and MDA. The testes were then excised and examined by light microscope. The results showed significant increase in TC, TG, LDL-C as well as WBCs, MDA, COX and P53. While significant decrease in testis weight, body weight, male hormones such as FSH, LH and T and hematological parameters as Hb, RBCs and PLT as well as HDL-C, GSH, SOD, CAT also showed a decrease in sperm concentration, count, motility, and sperm activity as well as the changes occur in histological investigation. However, GLE administration before and after NIT restored all parameters resulted from NIT injection and marked amelioration in the changes occurred in the testicular tissues when compared with control.

Date of Submission: 10-01-2020

Date of Acceptance: 27-01-2020

I. Introduction

Male reproductive system is affected by various chemicals and drugs which lead to infertility [1]. Smoking for example, was considered as a potential cause of infertility in males. NIT was known to account for 90 % of total cigarette alkaloid [2]. It is the major ingredient of cigarette in the particulate phase which is easily absorbed via respiratory system [3]. Beside it is considered as the major alkaloid constituent of the cigarette smoke, NIT is a pharmacologically active substance [4]. Infertility is known as the failure to get pregnancy after one year of regular intercourse in human. It is the condition that prevent the normal reproductive system mission[1]. On the other hand, the medicinal antioxidant plants play major roles in the treatment of different diseases as they contain antioxidants. An antioxidant is the substance which functions to protect the body from free radicals attack. Some examples of antioxidants are vitamins, polyphenols, karotin, and minerals. Naturally, these substances have a significant role to prevent diseases by suppressing the damage on cells which occurs due to oxidation of free radicals [5]. One of these medicinal plants is graviola which has antioxidant properties without any adverse effects [6]. Graviola contains the chemical compounds which display antiviral, antitumor and germicide effects [7] and antioxidant properties [8]. The graviola plant has many phytoconstituents and compounds of them: different important minerals, flavonol, alkaloids, essential oils, phenolics and acetogenin compounds which are the major components in GLE [9]. Moreover, the phytochemical screening of GLE shows the presence of saponins, triterpenoids, flavonoids, tannins and cardiac glycosides [10]. They are capable of neutralizing free radicals which can cause cells and tissue destructions [11]. Also, GLE contains ascorbic acid which plays a vital role in scavenging the free radicals resulted from the oxidative effect induced by NIT [12].

II. Material and Methods

Study Design: After 10 days of acclimatization period, rats were randomly grouped into 5 main groups, each has six rats as follow:

Control group: Rats of this group administered with saline solution.

Nicotine (NIT) group: Where, rats were subcutaneously injected with NIT (0.6 mg/kg bw) daily for 1 month.

Graviola leaves extract (GLE) group: The rats were orally administered with GLE (200 mg/kg bw) daily for 1 month by gavage.

Nicotine and graviola leaves extract (NIT + GLE) group: The rats were injected subcutaneously with NIT (0.6 mg/kg bw) daily for 1 month followed by orally administration of GLE (200 mg/kg bw) daily for 1 another month.

Graviola leaves extract and nicotine (GLE + NIT) group: The rats were orally administered with GLE (200 mg/kg bw) daily for 1 month followed by NIT injection (0.6 mg/kg bw) daily for 1 another month.

Study Location: This study was conducted on male albino rats in the animal house of the faculty of veterinary, Kafr El-Sheikh University, Egypt.

Study Duration: All rats were adapted to the place for 10 days before the beginning of the experiment, then 2 months the duration of the experiment.

Sample size: 30 rats.

Chemicals: Nicotine (NIT) was obtained from local suppliers for Sigma-Aldrich Company for chemicals, St. Louis, Mo, USA. NIT was administered subcutaneously [13] with a dosage of 0.6 mg/kg bw according to the previous study of [4]. Graviola dry extract was purchased from Origini Naturali Company, Italy. GLE was administered orally (200 mg/kg bw); according to the previous study of [7].

Sample collection and preparation: After 2 months, the period of the experiment, the fasted rats were weighted and then, sacrificed 24 hours after the last treatment. Blood samples under diethylether anesthesia were collected in clean and dry centrifuge glass tubes, let to clot and then, centrifuged for 15 min at 3000 rpm. The clear supernatant was quickly sucked by pipette. The sera were kept at -20°C for further biochemical analyses. Rats were dissected and the two testes were removed, cleaned and weighed. The left testes of all rats were homogenized by Lephlon homogenizer in a 10 volume ice-cold distilled water, then centrifuged for 15 min at 300 rpm and the supernatants were frozen at -20°C for further biochemical analyses. Right testis from each rat was processed for histopathological examination.

Hematological parameters: The chosen parameters were performed using hematology analyzer (Medonic CA530). Each blood samples was put in a 1ml tube coated with EDTA (ethylene diamine tetra acetic acid), and then analyzed for the following hematological parameters: white blood cells (WBCs), red blood corpuscles (RBCs), hemoglobin (Hb), platelets (PLTs).

Semen collection: The testicles were quickly removed through a lower abdominal incision. The testis was then separated from the epididymis with the scalped blade. The cauda of right epididymis was sucked into a pre-warmed (37°C) physiological saline to get sperm suspension. Sperms were stained with 2% eosin. The results were presented as mean \pm standard error [14]. The semen samples were analyzed by the method described by **Mira Spermolyzer CASA**.

Histopathological Investigation: The right testis of all rats of different groups was removed, fixed in 10% neutral formalin solution, dehydrated in buffered ethanol with an ascending grade, cleared in xylene and then, embedded in paraffin wax. The prepared tissue blocks were sectioned at 5 μ m thick. The paraffin sections were picked up on glass slides, processed for hematoxylin and eosin staining, then examined and photographed to confirm the pathological changes in each testis [15].

Statistical analysis: All statistical analyses were carried out using GraphPad Prism 5.0 software, San Diego, California, USA). The statistical comparisons were carried out by one-way analysis of variance (ANOVA), followed by Tukey post-hoc test [16]. The differences were counted as significant at $P \leq 0.05$.

III. Results

Injection of NIT subcutaneously to adult rats showed significant increase in TC, TG, LDL-C as well as WBCs, MDA, COX and P53. While significant decrease in testis weight, body weight, male hormones such as FSH, LH and T and hematological parameters as Hb, RBCs and PLT as well as HDL-C, GSH, SOD, CAT also showed a decrease in sperm concentration, count, motility, and sperm activity as well as the changes occur in histological investigation. However, GLE administration before and after NIT restored all parameters resulted from NIT injection and marked amelioration in the changes occurred in the testicular tissues when compared with control. The data are listed in the following tables (1- 8).

Table 1: Shows the effect of NIT and GLE on body weight (g):

Animal groups	C	GLE	NIT	GLE + NIT	NIT + GLE
Initial weight	214.5±2.4	219.5±3.3	216.5±7.1	218.7±3.1	214.7±5.8
1 st week	224.8±3.2	221.3±1.9	214.0±10.1	225.0±5.5	220.0±6.4
2 nd week	231.3±3.6	231.5±4.1	220.0±9.9	234.0±9.8	221.0±12.9
3 rd week	242.7±4.8	241.0±5.3	230.0±8.4	241.0±10.3	225.0±4.4
4 th week	245.0±7.7	242.8±7.6	242.0±5.9	245.2±8.4	230.0±13.9
5 th week	254.7±7.1	248.0±4.2	245.0±9.6	245.0±4.7	232.0±15.1
6 th week	250.0±7.1	245.0±4.1	250.0±6.6	235.0±9.1	240.0±7.6
7 th week	255.0±7.5	251.0±6.3	240.0±7.5	240.0±6.6	244.0±4.9
8 th week	261.0±5.9	262.0±55.6	230.0±5.9 ^a	246.0±6.3 ^b	248.0±3.9 ^b

Table 2: Shows the effect of NIT and GLE on testis weight (g):

Parameters	C	GLE	NIT	GLE+NIT	NIT+GLE
Testis weight	2.37±0.13	2.4±0.14	1.43±0.19 ^a	2.4±0.03 ^b	2.03±0.19 ^b

Table 3: Shows the effect of NIT and GLE on hematological parameters:

Parameters	C	GLE	NIT	GLE+NIT	NIT+GLE
Hb (g/dl)	12.7±0.5	14.1±0.6	9.9±0.6 ^a	11.8±0.4	12.7±0.3 ^b
RBCs (millions/dl)	9.2±0.6	9.3±0.5	4.1±0.3 ^a	6.0±0.3	5.9±0.5 ^b
WBCs (thousands/dl)	9.5±0.3	10.2±0.3	5.5±0.3 ^a	7.3±0.3 ^b	7.1±0.3 ^b
PLT (thousands/dl)	755.9±35.4	764.3±40.9	269.6±25.2	458.4±46.4	443.3±44.2

Table 4: Shows the effect of NIT and GLE on lipid profile (mg/dl):

Parameters	C	GLE	NIT	GLE+NIT	NIT+GLE
TC	44.5±3.8	43.5±3.8	95.5±6.2 ^a	52±3.6 ^b	47.8±3.8 ^b
TG	50.2±3.2	51.9±2.2	107.2±3.4 ^a	56.6±2.6 ^b	55±2.4 ^b
HDL-C	56.1±1.5	55.1±1.5	23.2±2.5 ^a	42.8±2.1 ^{ab}	48.8±2.3 ^b
LDL-C	29.9±2.1	29.3±1.9	111.2±3.3 ^a	32.3±2.2 ^b	27.6±3.3 ^b

Table 5: Shows the effect of NIT and GLE on male hormones:

Parameters	C	GLE	NIT	GLE+NIT	NIT+GLE
FSH (mIU/ml)	3.6±0.1	3.5±0.1	0.7±0.1 ^a	2.7±0.1 ^{ab}	3.50±0.10 ^b
LH (mIU/ml)	6.4±0.4	6.2±0.4	0.8±0.1 ^a	5.1±0.2 ^{ab}	5.40±0.30 ^b
T (ng/ml)	3.4±0.2	3.4±0.2	0.8±0.1 ^a	2.8±0.1 ^b	3.20±0.10 ^b

Table 6: Shows the effect of NIT and GLE on semen analysis:

Parameters	C	GLE	NIT	GLE+NIT	NIT+GLE
Concentration of sperm (million/ml)	66.9±2.38	68.5±2.3	19.2±1.5 ^a	60.52±2.9 ^b	66.2±2.26 ^b
Sperm count (million/Ejaculate)	245±7.60	258.3±4.4	53.2±4.5 ^a	244.3±7.4 ^b	245±7.60 ^b
Total motility (%)	76.7±4.41	76.8±4.3	24.7±2.9 ^a	27.5±3.2 ^b	75.67±3.75 ^b
Sperm activity (%)	85±3.15	90.5±2.4	30.3±1.5 ^a	77.7±2.4 ^b	82.50±2.49 ^b

Table 7: Shows the effect of NIT and GLE on oxidative stress markers:

Parameters	C	GLE	NIT	GLE+NIT	NIT+GLE
MDA (nmol/g)	485±22.9	455.3±22.9	775.8±19.4 ^a	529.4±19.38 ^b	530.5±17.10 ^b
GSH (U/g)	13.9±0.8	14.1±0.7	5.9±0.7 ^a	11.67±0.86 ^b	12.48±0.8 ^b
SOD (U/g)	167.3±7.4	167.8±7.9	117.6±7.9 ^a	158.5±7.93 ^b	166.6±6.6 ^b

CAT (U/g)	168.8±7.8	168.9±7.9	100±7.9 ^a	155.5±7.6 ^b	167.2±6.6 ^b
-----------	-----------	-----------	----------------------	------------------------	------------------------

Table 8: Shows the effect of NIT and GLE on apoptotic markers:

Parameters	C	GLE	NIT	GLE+NIT	NIT+GLE
P53	27.5±1.6	27.4±1.1	40.02±1.82 ^a	31.4±0.9 ^b	33.3±1.5 ^b
COX (ng/mg)	0.09±0.01	0.09±0.01	0.41±0.02 ^a	0.18±0.01 ^{ab}	0.14±0.01 ^{ab}

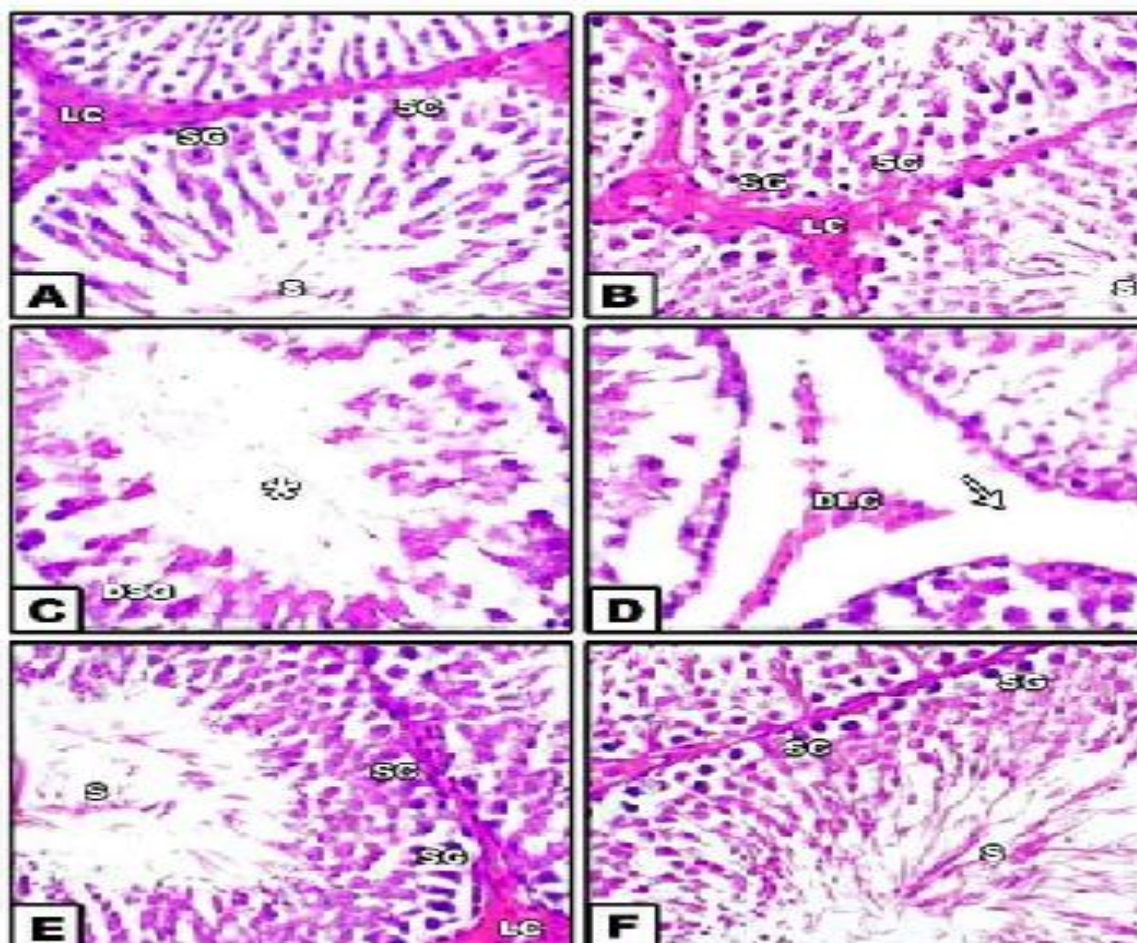
Data were expressed as means ± SE (number of rats in each group 6).

(a, b) indicated the significant change at P ≤ 0.05.

a= significance when compared with control, b= significance when compared with NIT group.

C: Control, GLE: Graviola leaves extract, NIT: Nicotine

Figure 1: Shows the effect of NIT and GLE on histopathological studies:



Testis sections of control group A and GLE supplemented group B displayed normal seminiferous tubules with narrow interstitial spaces with normal Leydig cells. The tubules were lined with stratified germinal epithelium composed of different spermatogenic stages. Between the spermatogenic cells; Sertoli cells were identified. Sperms were also seen in the lumen of seminiferous tubules (Figs. A & B, H&E-stained)

Sections in testis of NIT-treated group showed widening of the interstitial spaces between the seminiferous tubules containing damaged Leydig cells. Wide separation between the epithelium and the basement membrane was also noticed in some areas. Damage of spermatogenic cells and marked reduction of sperms in some seminiferous tubules were observed (Figs. C & D, H&E-stained)

Section in testis of GLE + NIT treated rats showed almost normal appearance of seminiferous tubules with normal spermatogenic cells nearly similar to those of the control group. They were lined by several layers of spermatogenic cells resting on a regular basement membrane. Normal spermatozoa in the lumen of

seminiferous tubules were observed. Interstitial spaces were apparently narrow with the arrangement of Leydig cells were also seen (Fig. E. H&E-stained).

Section in testis of NIT + GLE supplemented rats showed well organized seminiferous tubule with distinct primary, secondary spermatocyte, spermatids and spermatozoa compared with the nicotine treated group. Interstitial Leydig cells showed normal structure compared to the nicotine group (Fig. F. H&E-stained).

IV. Discussion

The results of current study showed a significant decrease in rat mean body weight comparing with other studied groups and these results are similar to the findings of [2]. The decreased body weight caused by NIT may be due to neuroregulatory mediators that mediate food intake [17]. NIT may also, reduced food consumption *via* disrupting leptin level which may increase lipolysis [18]. Also, NIT showed a significant decrease in rat testis weight. Such results go parallel with the findings of [19] and [2] who reported that NIT caused a reduction of testicular weight and they related this to acute androgens scarcity. On the other hand, oral administration of GLE to male albino rats treated with NIT showed increased body weight mean. These results go parallel with that reported by [20] and [21] who observed that GLE could improve the mean body weight or testis weight and they related this to the benefits of GLE. GLE which did not possibly cause any alterations in carbohydrate, protein or fat metabolism in these experimental animals [22].

The current study revealed a significant increase in the WBCs while significant decrease in RBCs count, Hb and PLTs were observed comparing with the control group. One of the major effects of NIT on the physiology of body is that it greatly suppresses the function of immune system and due to this reason the number of WBCs increased in the body to strengthen the immune system. It is documented that NIT inhibits the proliferation and function of erythrocytes [23]. On the other hand, the oral administration of GLE to male albino rats treated with NIT ameliorates the studied hematological parameters. These results were in accordance with [7] who confirmed that, administration of GLE to male rats treated with NIT could ameliorate the hematological changes as GLE exerts its anti-inflammatory and antioxidant effects on rats.

The current study revealed interruption in lipid profile in NIT treated rats. NIT caused a significant decrease in HDL-C and significant increase in TC, TG and LDL-C comparing with the control group. These results were similar to the previous studies obtained by [24] who reported that the presences of hypercholesterolemia and triglyceridemia in heavy smokers are due to increased activity of 3-hydroxy-3-methyl-glutaryl CoA reductase (HMG-CoA reductase) and increased incorporation of labeled acetate into cholesterol. Higher level of TG occurred due to the presence of NIT which decreases the activity of lipoprotein lipases and these enzymes involved in the uptake of circulating triglycerides rich lipoprotein by the extra hepatic tissue. The smokers showed an increase in LDL and TG and a decreased HDL all of which are measures of the deteriorating health condition. On the other hand, GLE administration as a protection or a treatment to rat treated with NIT showed a noticeable improvement. Such results go parallel with the findings of [25] who recorded that administration of GLE to rat treated with NIT could ameliorates the lipid profile changes. The GLE may have prevented the increase of TC by inactivating HMG-CoA reductase, the rate-limiting enzyme in cholesterol biosynthesis. The significant reduction in the concentration of TC and TG by GLE may also be due to the presence of antioxidants and hypolipidaemic agents which decrease in absorption of cholesterol and/or an increase in HDL-cholesterol.

The data of the present study indicated that the sperm concentration, motility and sperm activity were significantly decrease in semen analysis in rat treated with NIT and these results were agreement with the previous studies [2] and [19]. Similarly, it was found that the normal morphology of sperm was adversely affected by smoking behavior. Sperm abnormalities observed in rats treated with NIT might be due to low production of testosterone and the DNA damage. In addition, an increase in reactive oxygen species (ROS) level caused by NIT would also leads to the morphological defects in the sperm, since mammalian sperms are rich in polyunsaturated fatty acids and are susceptible to attack by ROS [26]. On the other hand, GLE mitigated the toxicity on sperm motility, sperm count and sperm head abnormalities. These results were in agreement with [20] who attributed to its scavenging properties for free radical and its antioxidant capacity which induced by its active ingredients. Also, it could be attributed to its rich of vitamin C content which exerts the protective role of vitamin C. Ascorbic acid (Vitamin C) is an important component of the body's antioxidant defense mechanisms; it can decrease the oxidative effects of toxic substances [12].

The data of the present study showed that, the mean level of T, FSH and LH were significantly lower in rats treated with NIT compared to the control group. These results are in accordance with [26] and [19] who reported that NIT interfere with hypothalamus-pituitary-testicular axis in several levels. Also, these added that impairment in sex hormones was induced by ROS. Moreover, the decreased in serum T level of the rat treated with NIT may have been caused by the disruption of testicular cyto-architecture which consequently adversely affected Leydig cell number and functioning, which leading to the decrease of serum T level. In the opposite way, GLE supplemented to rats treated with NIT as protective or treatment cause a significant increase in T,

FSH and LH levels. [10] and [7] showed that the role of GLE in ameliorate of testicular hormon levels could be attributed to its antioxidant properties which scavenging the free radicals induced by NIT.

In addition, the obtained results showed that the oxidative stress in the testis of NIT treated rats represented by a significant increase in MDA and significant decrease in CAT, SOD and GSH. These results were accompanied with [19] who revealed that NIT has been found to disturb the antioxidant defense mechanism, increased LPO, hydrogen peroxide and hydroxyl radical generation, while reduced the level of GSH, the activities of antioxidant enzymes which supported the results obtained in the present study. Also, these results are in agreement with [26] who attributed that due to the cellular integrity alterations of tested as a result of elevation of oxidative stress directly reduce the endogenous antioxidant activities. On the other hand, oral administration of GLE led to a significant increase in GSH, CAT and SOD while showing a significant decrease in MDA compared to the NIT treated group. These results are parallel with the findings of [27] and [7] who explained that the active ingredient of phytochemical compounds especially acetogenins are very vital component for the free radical scavenging and antioxidant activities of the plant which.

In the current study, NIT increased the apoptotic markers (P53 & COX) and these results are in agreement with [2]. On the other hand, GLE administration led to ameliorate the apoptotic factors such as P₅₃. Annonacin, considered the main GLE acetogenin, is documented as being able to cause cell death by apoptosis in the G1 phase of the cell cycle. The mechanism involves promoting pro-apoptotic protein expression, as well as the P₅₃ and P₂₁ while inhibiting the antiapoptotic protein expression [28].

In the current study, several histopathological alterations were recorded in the testicular sections of rats treated with NIT. Such results were represented by fragmented seminiferous tubule, several vacuoles, damage Leydig cells and disorganization of spermatogenic cells. Similar results were recorded by [4] who observed many disruption in the testis by NIT which can cause a valuable index of reproductive toxicity in male animals and that is in consistent with the elimination of germ cells from testis. Also, the spermatogenic disorder had been reflected by the decrease in the number of different generations of germ cells at stage VII of spermatogenic cycle. The histological evaluation of the testicular section also revealed the disruption of spermatogenesis. This was attributed to the low levels of both serum T and FSH hormones. T hormone was processing the normal growth of sexual organs and FSH hormone play a vital role in production of androgen binding protein (ABP) by activation of the Sertoli cells. The ABP is necessary to bind T that is important for full spermatogenesis [29]. On the other hand, oral administration of GLE led to a remarkable amelioration were recorded in the histological testicular sections of rats treated with NIT and supplemented with GLE before or after NIT. The present results are in agreement with [7] who reported that GLE and the combination of them confirmed by histopathological observations where showing recovery in seminiferous tubules with production in normal sperm cells and seminiferous tubules return in normal structure. The antioxidant effect of GLE has been considered to be mediated via its major effects on eradication of free radicals and/or via preventing lipid peroxidation and it is at least 10 times more active as an antioxidant than Vitamin E. This is so because GLE have been shown to possess antioxidant properties, due to the presence of acetogenins, which probably play the role of effective free radical scavengers. GLE was found to decrease structural changes in the testis [30].

V. Conclusion

This study concluded that there were biochemical and histological alterations in male albino rats treated with NIT. These results indicated a testicular damage in male albino rats induced by NIT toxicity related to decrease in sperm characteristics and other parameters which resulted in infertility.

References

- [1]. **Lindgren, M.C. (2018):** Male infertility. *Physician Assistant Clinics*, 3: 139-147.
- [2]. **Mosadegh, M.; Hasanzadeh, S. and Razi, M. (2017):** Nicotine-induced damages in testicular tissue of rats; evidences for bcl-2, p53 and caspase-3 expression. *Iranian Journal of Basic Medical Sciences*, 20: 199–208.
- [3]. **Ray, D. and Mukherjee, S. (2018):** The Protective effects of *chlorophytum boriviltanum* on Nicotine-induced reproductive toxicity, oxidative damage, histological changes and haematotoxicity in male rats. *Journal of Innovations in Pharmaceutical and Biological Sciences*, 5: 76-81.
- [4]. **Jana, K.; Samanta, P.K. and De, D.K. (2010):** Nicotine diminishes testicular gametogenesis, steroidogenesis, and steroidogenic acute regulatory protein expression in adult albino rats: possible influence on pituitary gonadotropins and alteration of testicular antioxidant status. *Toxicological Sciences*, 116: 647-659.
- [5]. **Tanaya, G.; Kuswinarti, K. and Dewi, R.N.S. (2015):** *Annona muricata* Linn. Leaf Effect in Inhibiting SGPT Elevation. *Althea Medical Journal*, 2: 86-89.
- [6]. **Vijayameena, C.; Subhashini, G.; Loganayagi, M. and Ramesh, B. (2013).** Original research article phytochemical screening and assessment of antibacterial activity for the bioactive compounds in *Annona muricata*. *International Journal of Current Microbiology and Applied Sciences*, 2: 1-8.
- [7]. **Elshater, A.-E.A.; Ali, R.A.; Mohi, M.M. and Gedawy, H.Y. (2018):** Comparative biochemical studies on the effect of nano-magnetic particles (nps) and graviola leaves extract on adriamycin induced-gonadotoxicity in male albino rats. *Egyptian Academic Journal of Biological Sciences C, Physiology and Molecular Biology*, 10: 11-25.

- [8]. **Rady, I.; Bloch, M.B.; Chamcheu, R.-C.N.; Banang Mbeumi, S.; Anwar, M.R.; Mohamed, H.; Babatunde, A.S.; Kuate, J.-R.; Noubissi, F.K. and El Sayed, K.A. (2018):** Anticancer Properties of Graviola (*Annona muricata*): A Comprehensive Mechanistic Review. *Oxidative Medicine and Cellular Longevity*, 2018: 1-39.
- [9]. **Prasad, S.K.; Varsha, V. and Devananda, D. (2019):** Anti-cancer properties of *Annona muricata* (L.): A Review. *Medicinal Plants International Journal of Phytomedicines and Related Industries*, 11: 123-134.
- [10]. **Amadi, B.A.; Onyegeme-Okerenta, B.M. and Ezeonyilimba, V.O. (2018):** The potential ameliorative effects of *Annona muricata* (Linn) on sodium fluoride-induced toxicity on haematological indices and fecundity of adult male wistar rats. *Journal of Applied Life Sciences International*, 19: 1-16.
- [11]. **Rafieian-Kopaei, M.; Baradaran, A. and Rafieian, M. (2013):** Oxidative stress and the paradoxical effects of antioxidants. *Journal of Research in Medical Sciences*, 18: 620-628.
- [12]. **Hassan, K.A.; Ahmed, M.A.; Hassanein, K.M. and Waly, H. (2016):** Ameliorating effect of vitamin C and selenium against nicotine induced oxidative stress and changes of p53 expression in pregnant albino rats. *Journal of Advanced Veterinary and Animal Research*, 3: 321-331.
- [13]. **Nair, S.V.G. and Rajamohan, T. (2014):** The role of coconut water on nicotine-induced reproductive dysfunction in experimental male rat model. *Food and Nutrition Sciences*, 5: 1121-1130.
- [14]. **Bello, N.B.; Rabi, A.M. and Odeh, S.O. (2013):** The effect of aqueous leave extract of *Nicotiana Tabacum* (tobacco) on some reproductive parameters and micro-anatomical architecture of the testis in male albino wistar rats. *Nature Science Research*, 5: 137-143.
- [15]. **Bancroft, J. and M. Gamble. (2008):** Theory and Practice of Histological Techniques. Elsevier health sciences, 6th edition: 135-160.
- [16]. **Armitage, P.; Berry, G. and Matthews, J.N.S. (2008):** Statistical methods in medical research. John Wiley & Sons.
- [17]. **Sharif, S.; Farasat, T.; Fatima, N.; Farooq, A. and Naz, S. (2014):** Effect of nicotine on hematology, lipid profile and liver enzymes in adult male mice (*Mus musculus*). *Advances in Animal and Veterinary Sciences*, 2: 222 – 225.
- [18]. **Harris, K.K., Zopey, M. and Friedman, T.C. (2016):** Metabolic effects of smoking cessation. *Nature Reviews Endocrinology*, 12: 299-308.
- [19]. **Ekaluo, U.; Ikpeme, E.; Ibiang, Y. and Omordia, F. (2013):** Effect of soursop (*Annona muricata* L.) fruit extract on sperm toxicity induced by caffeine in albino rats. *Journal of Medical Sciences*, 13: 67-71.
- [20]. **Ahalya, B.; Shankar, K.R. and Kiranmayi, G. (2014):** Exploration of anti-hyperglycemic and hypolipidemic activities of ethanolic extract of *Annona muricata* bark in alloxan induced diabetic rats. *International Journal of Pharmaceutical Sciences Review and Research*, 25: 21-27.
- [21]. **Arthur, F.; Woode, E.; Terlabi, E. and Larbie, C. (2011):** Evaluation of acute and subchronic toxicity of *Annona muricata* (Linn.) aqueous extract in animals. *European Journal of Experimental Biology*, 1: 115-124.
- [22]. **Singh, R. and Singh, K. (2019):** Protective activity of Guduchi and green tea extract on nicotine-induced toxicity in mice. *The Pharma Innovation Journal*, 8: 650-656.
- [23]. **Reddy, A.V.; Killampalli, L.K.; Prakash, A.R.; Naag, S.; Sreenath, G. and Biraggari, S.K. (2016):** Analysis of lipid profile in cancer patients, smokers, and nonsmokers. *Dental Research Journal*, 13: 494-499.
- [24]. **Usunomena, U. (2014):** Protective effects of *Annona muricata* ethanolic leaf extract against Dimethylnitrosamine (DMN)-induced hepatotoxicity. *Journal of Pharmacy and Biological Sciences*, 9: 1-6.
- [25]. **Salem, N.A.; Alnahdi, H.S. and Ibrahim, G.S. (2017):** Therapeutic effect of curcumin against nicotine-induced reproductive dysfunction in male rats. *Journal of Innovations in Pharmaceuticals and Biological Sciences* 4: 26-31.
- [26]. **Vaghela, B.; Bhavsar, D. and Jain, N. (2016):** Effect of aqueous extract of *Annona muricata* (Graviola Tea) on the oxidative stress produced by the artificial UV source *in vivo* and *in vitro*. *International Journal of Current Microbiology and Applied Sciences*, 5: 648-655.
- [27]. **Doku, D.A. (2017):** Antiproliferative activity of aqueous leaf extract of *Annona muricata* (Linn.) on rat prostate, BPH-1 cells and some target genes. PhD Thesis.
- [28]. **Kianifard, D.; Sadrkhanlou, R.-A. and Hasanzadeh, S. (2011):** The histological, histomorphometrical and histochemical changes of testicular tissue in the metformin treated and untreated streptozotocin-induced adult diabetic rats. *Veterinary Research Forum*, 2: 13-24.
- [29]. **Abd-Ella, E. and Mohamed, A. (2016):** Attenuation of monosodium glutamate-induced hepatic and testicular toxicity in albino rats by *Annona muricata* Linn.(Annonaceae) leaf extract. *Journal of pharmaceutical and Biological Sciences*, 11: 61-69.

El-Sawi, M.R, et.al. "Effect of Graviola Leaves Extract on Nicotine Induced Reproductive Damages In Male Albino Rats." *IOSR Journal of Pharmacy and Biological Sciences (IOSR-JPBS)*, 15(1), (2020): pp. 44-50.