

## Evaluation of the Effect of Ethanolic Extract of *Annonamuricata* Leaf on the Testes and Prostate Gland of Male Albino Rats

Elizabeth O. Nweke<sup>1\*</sup>, Frank C. Akpuaka<sup>1,2</sup>

<sup>1</sup>Department of Anatomy, Faculty of Basic Medical Sciences, Chukwuemeka Odumegwu Ojukwu University, Anambra State, Nigeria

<sup>2</sup>Department of Anatomy, college of Medicine and Health Science/ Abia State University, Uturu, Nigeria  
Corresponding author: Nweke Elizabeth O

Department of Anatomy, Faculty of Basic Medical Sciences, Chukwuemeka Odumegwu Ojukwu University, Anambra State, Nigeria

---

**Abstract:** This study investigated the effect of ethanolic extract of *Annonamuricata* leaf on the testes and prostate gland. Twenty four male albino rats weighing between 150-180 g were used in this study. The animals were divided as follows: Group A was treated with 2 ml/kg body weight of distilled water, Group B was treated with 100 mg/kg body weight of the extract of *A. muricata*, Group C was treated with 200 mg/kg body weight of the extract of *A. muricata* and Group D was treated with 300 mg/kg body weight of the extract of *A. muricata*. The treatments were given orally and lasted for 30 days. After treatment, the animals were sacrificed and the organs harvested, weighed and fixed in 10% formal saline for histological studies. Data were analysed using one-way ANOVA and SPSS version 2.0. Results showed a significant ( $P < 0.05$ ) increase in testicular weight and a significant ( $P < 0.05$ ) decrease in sperm count and motility. Histopathological findings showed distortions of the seminiferous tubules and mild degeneration of the interstitial cells of Leydig in group B, group C showed moderate apoptosis of the interstitial cells of Leydig and moderate degeneration and arrest of spermatogenesis while group D showed moderate to severe degeneration with severe arrest of the spermatogenesis and moderate apoptosis of the interstitial cells of Leydig. The prostate gland showed no distortions and appeared to be normal after treatment. Consumption of ethanolic extract of *A. muricata* leaf at higher doses has the potential of causing damage to the Leydig cells thereby reducing the level of testosterone. This reduction indirectly has a positive effect in the management of prostate cancer.

**Keywords:** *Annonamuricata*; Testes; Prostate gland; Albino rats; Sperm count; Sperm motility

---

Date of Submission: 10-04-2019

Date of acceptance: 26-04-2019

---

### I. Introduction

Medicinal plants have played a vital role in the prevention and management of various diseases especially in some traditional African localities and among the low socio – economic class. Herbal medicines are apparently considered relatively safer with an increase in demand compared with conventional therapy<sup>[1]</sup>. The increase in demand is fostered by the increase in the attention it is being given<sup>[2]</sup>.

*Annonamuricata* (Soursop) is an example of medicinal plants that belongs to the family Annonaceae and is found throughout the tropics<sup>[3]</sup>. The leaves, stem, seeds, bark and roots possesses several bioactive substances known as annonaceous acetogenins. The bioactive chemical acetogenins found in *A. muricata* have been reported to be moderately cytotoxic to normal cells compared to cancerous cells<sup>[4]</sup> and have the ability to induce apoptosis<sup>[5]</sup>. At low doses, it has been reported to be significantly toxic against Ovarian, breast, cervical, skin and bladder cancer cell lines<sup>[6]</sup>. The leaf of *A. muricata* have been reported to be used in the treatment of cancer and skin infection such as eczema while the white pulp of the fruit is used to make juice, as well as candies, sorbets and ice-cream flavourings<sup>[7]</sup>. Furthermore, it has been known to have several medicinal uses such as in the management of diabetes and its complications<sup>[3, 8, 9]</sup>, treatment of malaria<sup>[10, 11]</sup>, as antioxidant and anti-mutagenic agent<sup>[12]</sup> and it is usually recommended in the treatment of constipation, obesity, hypertension and coronary diseases<sup>[8]</sup>. Medicinal plants have been reported to be very useful in spite of the lack of evidence to back their efficacy and safety<sup>[13]</sup>.

Prostate cancer is the most common cancer and the leading cause of cancer death in men both in developed and developing countries with its risk increasing with age above 50 years<sup>[14]</sup>. One of the possible causes of prostate cancer is a hormonal imbalance of the male sex hormone testosterone<sup>[15]</sup>. Testosterone is produced by the testes and removal of the testes helps control the growth of advanced prostate cancer. However, it is not a common procedure as most men wouldn't oblige to removing their testes. This study therefore seeks alternative ways in which prostate cancer growth can be managed using *A. muricata* leaf extract.

---

## II. Materials And Methods

### Collection of Plant Materials

Fresh leaves of *A. muricata* were harvested from Uturu, Abia State. The leaves were identified at the herbarium units, Department Botany, Abia State University, Uturu.

### Preparation of Plant Extract

The fresh leaves of *A. muricata* were washed; air dried and pulverized using electronic blender. 500g of the powdered leaves were macerated in two litres of ethanol for 48hrs inside a mechanical shaker. After 48hrs, the mixture was then filtered using filter paper into a clean glass beaker. The filtrate was concentrated using rotary evaporator into a jelly-like form which was stored in refrigerator until when needed.

**Chemicals:** The chemicals used in the course of this research were of certified analytic grade.

### Experimental Animals

Twenty (20) healthy and sexually mature male albino rats of about 150 -180 g were used in this study. The rats were purchased from the experimental animal unit of Department of Anatomy, Abia State University, Uturu. They were housed in conventional wire mesh cages under standard laboratory conditions and allowed free access to water and pellet feed throughout the period of the experiment. The animals were acclimatized for two weeks before the commencement of study. Ethical approval on the animal act right was obtained from the University animal care committee which is in compliance with the National regulation for animal research.

### Experimental Design and Procedures

The 20 rats were randomly divided into four groups of five rats each designated as groups A, B, C and D. Group A served as control and received only distilled water and laboratory chow, Group B, C and D received 100 mg/kg, 200 mg/kg and 300 mg/kg body weight of *A. muricata* leaf extract respectively. The extract was given orally and lasted for 30 days. The rats were sacrificed under chloroform anaesthesia 24 hours after the last treatment. Blood was collected via cardiac puncture for serum testosterone level examination. The testes and prostate gland were harvested and weighed using Scout Pro SPU 601 electronic weighing balance.

### Sperm Motility and Count

Epididymal spermatozoa were collected by cutting the caudal region of the epididymis into small pieces in a container containing 5ml of normal saline solution. Assessment of sperm motility and count were performed according to the method by Freund and Carol [16]. Two drops of the solution containing the small pieces of the caudal epididymis, was smeared on the microscope slide. Epididymal sperm motility was then assessed by calculating motile spermatozoa per unit area and was expressed in percentage. Epididymal sperm count was obtained by cytometry using the improved Neubauer cytometer and expressed as million/mL of suspension [17].

### Histopathological Analysis

The harvested testes were blotted with clean tissue, weighed to obtain the relative organ weight and then fixed in 10% formal saline. Three micrometres (3 µm) sectioned slides of the testes was stained with haematoxylin and eosin (H&E) and later evaluated microscopically for changes in the tissues using Olympus BX 51TF light microscope connected to a digital camera. Images were captured at x400 magnification.

### Statistical Analysis

Data from testicular weight, serum testosterone level, sperm motility and sperm count were subjected to the Analysis of Variance (ANOVA) test followed by multiple comparisons using Least Significant Difference (LSD). The levels of significance were considered at  $P < 0.05$  and data was expressed as Mean  $\pm$  SEM.

## III. Results

### Weight of Testes

Testicular weight analysis (Table 1) showed a statistically significant increase ( $P < 0.05$ ) in the treated groups when compared to the control. The highest weight was recorded in group C.

**Table 1:** Effect of ethanolic extract of *A. muricata* leaf on Testicular weight

GROUPS	TESTICULAR WEIGHTS
A	1.55 $\pm$ 0.16
B	2.16 $\pm$ 0.23*
C	2.62 $\pm$ 0.20**
D	2.53 $\pm$ 0.05*

\* $P < 0.05$  and \*\* $P < 0.001$  when compared to the control

### Serum Testosterone Level

The serum testosterone level significantly decreased ( $P < 0.05$ ) in the treated groups when compared to the control (Table 2) with the highest dose having more effect indicating a dose dependent effect.

**Table 2:** Effect of ethanolic extract of *A. muricata* leaf on Testosterone level

GROUPS	TESTOSTERONE CONCENTRATION (ng/ml)
A	5.20 ± 0.14
B	1.20 ± 0.28**
C	1.10 ± 0.28**
D	0.45 ± 0.21**

\* $P < 0.05$  and \*\* $P < 0.001$  when compared to the control

### Sperm Motility and Count

There was a statistically significant reduction ( $P < 0.05$ ) in sperm motility and sperm count in the treated groups when compared to the control (Table 3). These reductions were in a dose-dependent manner.

**Table 3:** Effect of ethanolic extract of *A. muricata* leaf on sperm motility and sperm count

		MEAN ± SEM	P-VALUE	F-VALUE
Sperm Motility	Group 1	85.00 ± 2.88		
	Group 2	70.00 ± 5.77	0.017*	
	Group 3	70.00 ± 0.00	0.017*	6.000
	Group 4	65.00 ± 2.88	0.004*	
Sperm Count (million/mL)	Group 1	64.33 ± 1.76		
	Group 2	47.33 ± 1.20	0.000**	
	Group 3	31.00 ± 2.88	0.000**	94.487
	Group 4	23.00 ± 1.15	0.000**	

\* $P < 0.05$  and \*\* $P < 0.001$  when compared to the control

### Histopathological findings

#### Testes

The photomicrograph sections of the testes in Group A showed normal testicular architecture with well enhanced spermatogenesis (WES) and seminiferous tubule (S) that are lined with interstitial cells of the Leydig (ICL). The overall feature appeared normal (Plate A). Group B which was administered with 100 mg/kg of *A. muricata* showed mild disorganization of the seminiferous (MDST) and mild degeneration with mild apoptosis of the interstitial cells of Leydig (MAICL) (Plate B). Group C administered with 200 mg/kg of *A. muricata* showed the moderate apoptosis of the interstitial cells of Leydig (MAICL) and moderate arrest of the spermatogenesis Leydig (MAS) (Plate C) while Group D administered with 300 mg/kg of *A. muricata* showed moderate to the severe degeneration with severe arrest of the spermatogenesis (SAS) and moderate apoptosis of the interstitial cells of Leydig (MAICL) (Plate D).

#### Prostate gland

Photomicrograph section of group A showed normal prostatic tissue with secretion within the lumen. Group B showed moderately normal prostate gland with moderate prostatic secretion (MPS). Group C showed well perfused proliferating prostatic gland with thicker secretion (TS) while group D showed well perfused proliferating prostatic gland with well enhanced secretion (WPPG).

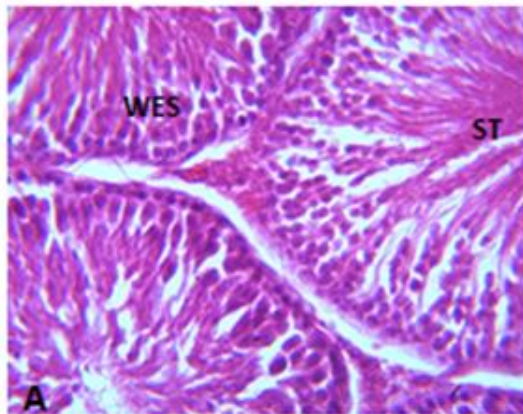


Plate A: Photomicrograph section of testes in Group A (H&E, x400 magnification)

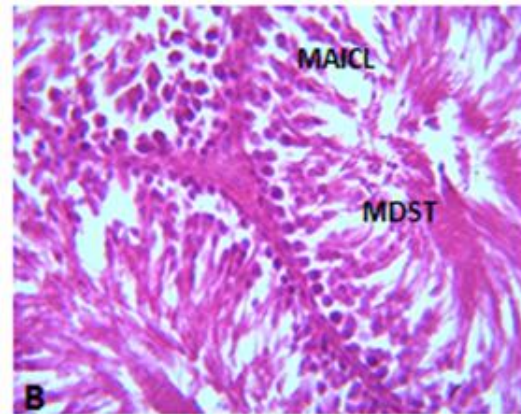


Plate B: Photomicrograph section of testes in Group B (H&E, x400 magnification)

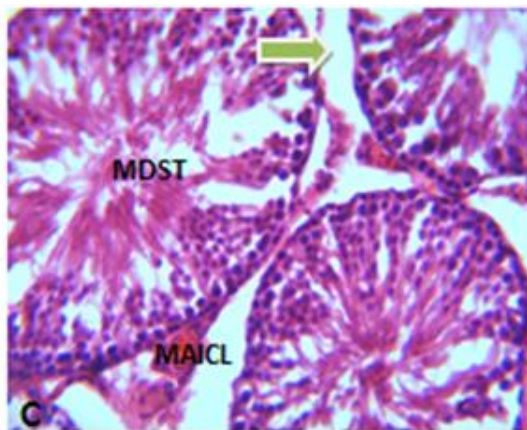


Plate C: Photomicrograph section of testes in Group C (H&E, x400 magnification)

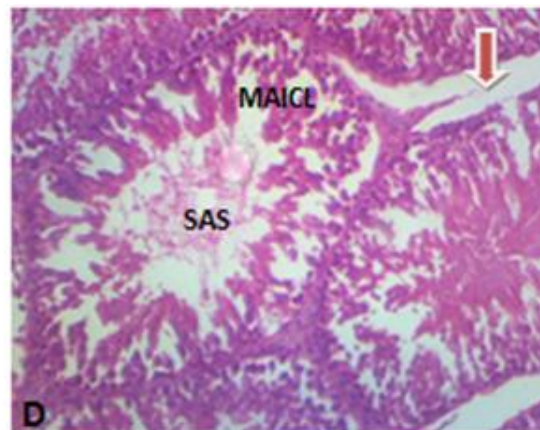


Plate D: Photomicrograph section of testes in Group D (H&E, x400 magnification)

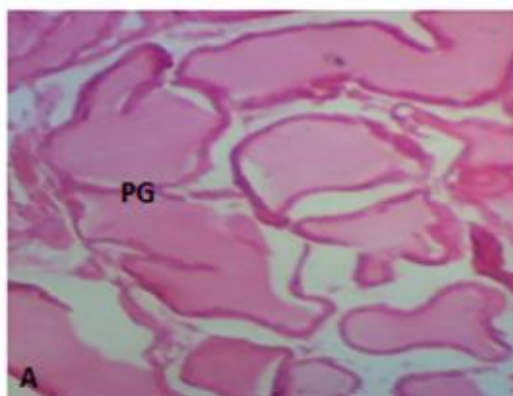


Fig. 1: Photomicrograph section of Prostate gland in group A (H/E, x400 magnification).

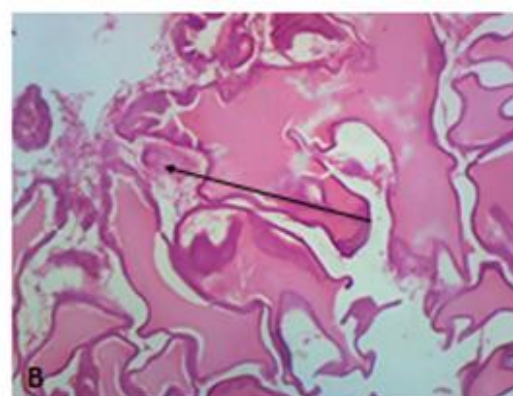


Fig. 2: Photomicrograph section of Prostate gland in group B (H/E, x400 magnification).

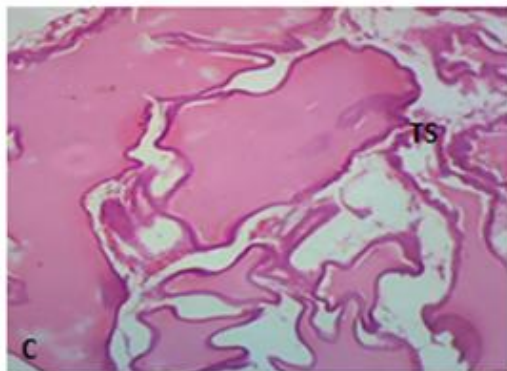


Fig. 3: Photomicrograph section of Prostate gland in group C (H/E, x400 magnification).

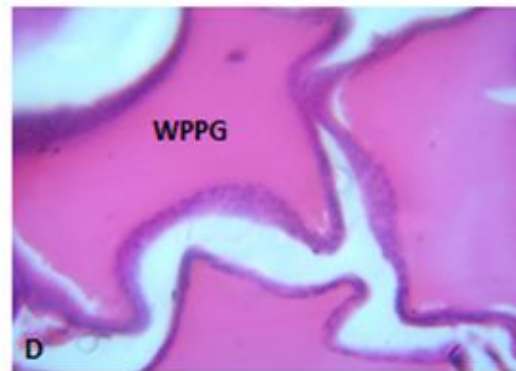


Fig. 4: Photomicrograph section of Prostate gland in group D (H/E, x400 magnification).

#### IV. Discussion

Some medicinal plants with antioxidant properties exhibit protective effects against diseases, sexual enhancement effect and increase the production of testosterone. However, *A. muricata* has toxic effect on the testes thereby resulting to an indirect beneficial effect to the prostate.

Results obtained from this study revealed that ethanolic extract of *A. muricata* leaf caused a significant effect on testicular weight, serum testosterone level, sperm motility and sperm count when compared to the control. The ethanolic extract of *A. muricata* leaf caused a significant increase in testicular weight, with group C having the highest weight. The reason for the increase in weight could be due to inflammation caused by toxicity of the extract. However, there was a significant reduction in the serum levels of testosterone, sperm motility and sperm count in all treated groups with higher dose having a more significant effect. These reductions could be attributed to the distortions in spermatogenesis and supported by Ikpemeet *al.*<sup>[18]</sup> who reported a direct correlation with distortions in the underlying processes of spermatogenesis. This is similar to findings of Thakkaret *al.*<sup>[12]</sup> and Ekaluoet *al.*<sup>[19]</sup>.

In the same vein, histopathological findings revealed distortion of the testicular tissues, Leydig cell hypoplasia and incomplete maturation of spermatozoa in the seminiferous tubules. High doses of *A. muricata* leaf extract caused damage to the interstitial Leydig cells and this synchronises with concomitant fall in serum levels of testosterone since the Leydig cells are responsible for the production and secretion of testosterone. This is in line with Astrinet *al.*<sup>[5]</sup> who reported the cytotoxic effect of acetogenins and its ability to induce apoptosis. This histopathological result supports that of sperm count motility and testicular weight, establishing the fact that *A. muricata* extract exerts toxic effects on testicular tissues in a dose-dependent manner. This is in agreement with that of Ekaluoet *al.*<sup>[19]</sup>.

*A. Muricata* did not pose any dangerous effect on the prostate gland as the tissues were normal after treatment with the extract. Prostate cancer is highly dependent on high testosterone level; it is therefore conceivable that extract of *A. muricata* would have beneficial effects on patients with this disease. Most beneficial effect in the management of cancer of the prostate is not usually a direct effect on the prostate gland but an indirect effect brought about by lowering the level of testosterone. With the extract of *A. muricata* leaf showing a significant reduction in the levels of testosterone, it is right to say that *A. muricata* could have a beneficial indirect effect in the management of prostate cancer. This is in agreement with the work of Ragasaet *al.*<sup>[20]</sup>. However, despite its proposed beneficial effect on prostate cancer, it is worth noting that consuming this extract at higher doses have a direct effect on the basal ganglia and could result in atypical forms of Parkinsonism<sup>[21]</sup>.

#### V. Conclusion

The present study reveals that consumption of ethanolic extract of *A. muricata* leaf is good in the management of prostate cancer because it exerted direct effect on the testes by causing distortions and destroying the interstitial cells of Leydig thereby lowering the testosterone levels. Thus, patients with prostate cancer are recommended to consume extract of *A. muricata* but at moderate doses.

#### Acknowledgement

None

## References

- [1]. Gurib-Fakim A. Medicinal plants: traditions of yesterday and drugs of tomorrow. *Mol Aspects Med.* 2006;27:1–93.
- [2]. Crook MA. *Clinical chemistry and metabolic medicine.* 7th ed. London: Hodder Arnold. 2006.
- [3]. Adewole SO, Caxton-Martins EA, OjewoleJAO. Histochemical and Biochemical effects of melatonin on pancreatic  $\beta$ -cells on streptozocin treated diabetic rats. *Pharmacology-Online.* 2006; 2: 1-21.
- [4]. George VC, Kumar DR, Rajkumar V, Suresh PK, Kumar RA. Quantitative assessment of the relative antineoplastic potential of the n-butanolic leaf extract of *Annonamuricata*Linn. in normal and immortalized human cell lines. *Asian Pac J Cancer Prev.*2012;13(2): 699–704.
- [5]. Astirin OP, Artanti AN, Fitria AM, Perwitasari EA, AdiPrayitnoA. *Annonamuricata*Linn Leaf Induce Apoptosis in Cancer Cause Virus. *J Cancer Ther.*2013;4: 1244–50.
- [6]. Yuan SS, Chang HL, Chen HW, Yeh YT, Kao YH, Lin KH *et al.* Annonacin, a mono-tetrahydrofuranacetogenin, arrests cancer cells at the G1 phase and causes cytotoxicity in a Bax- and caspase-3-related pathway. *Life Sci.*2003;72(25): 2853–61.
- [7]. Mangal M, Khan MI, Agarwal SM. Acetogenins as Potential Anticancer Agents. *Anti-cancer agents in Med Chem.*2015;16(2):138-159.
- [8]. Pamplona-Roger GD. *Encyclopedia of food and their healing power.* Madrid: Editorial Safeliz. 2005
- [9]. Shirwaikar A, Rajendran K, Kumar CD, BodlaR. Antidiabetic activity of aqueous leaf extract of *Annonasquamosa* in streptozotocin-nicotinamide type 2 diabetic rats. *Journal Ethnopharmacology.*2014;91: 171-175.
- [10]. Gbeassor M, Kedjagni AY, Koumaglo K, De Souza C, Agbo K, Aklikokou K *et al.* *In Vitro* antimalarial activity of six medicinal plants. *Phytother Res.*1990;4(3): 115–7.
- [11]. Antoun MD, Gerena L, Milhus WK. Screening of the flora of Puerto Rico for potential antimalarial bioactives. *Int J Pharmacol.* 1993;31: 255-8.
- [12]. Thakkar JH, Solanki HK, Tripathi P, Patel NJ, Jani GK. Evaluation of antimutagenic potential of *Annonasquamosa* leaf extract. *Elixir Human Physiology.*2011;31: 1960-1965.
- [13]. Muhammad BY, Awaisu A. The need for enhancement of research, development, and commercialization of natural medicinal products in Nigeria: lessons from the Malaysian experience. *Afr J Tradit Complement Altern Med.*2008;5(2): 120–30.
- [14]. Torre LA, Bray F, Siegel RL, Ferlay J, Lortet-Tieulent J, Jemal A.A global cancer statistics, 2012. *Cancer J Clin.*2015;65(2):87-108.
- [15]. Wein AJ, Kavoussi LR, Partin AW, Peters CA. *Urology Book* (Tenth ed.) Philadelphia, PA: Elsevier. 2012.
- [16]. Freund M, Carol B. Factors affecting haemocytometer counts of sperm concentration in human semen. *J Repord Fertil.*1965;8: 149-155.
- [17]. Ekaluo UB, Udokpoh AE, Ikpeme EV, Peter EU. Effect of chloroquine treatment on sperm count and weight of testes in male rats. *Global J Pure Appl Sci.*2008;14: 175-177.
- [18]. Ikpeme EV, Udensi O, Ekaluo UB, Efieneokwu N. Biological response of male wistar rats to crude extracts of *Ficusexasperate*(VAHL). *Int J Curr Res.*2010;7:9-13.
- [19]. Ekaluo UB, IkpemeEV, Ibiang YB, Omordia FO. Effect of soursop (*Annonamuricata*L.) fruit extract on sperm toxicity induced by caffeine in albino rats. *J Med Sci.*2013;13: 67-71.
- [20]. Ragasa C, Soriano G, Torres OB, Ming-Jaw D, Chien-Chang S. Acetogenins from *Annonamuricata*. *Phcog J.* 2012; 32: 32–7.
- [21]. Nweke EO, AkpuakaFC. The effect of ethanolic extract of *Annonamuricata* leaf on the basal ganglia. *GSC Biol and Pharm Sci.*2019;6(3):40-44.

Nweke Elizabeth O. "Evaluation of the Effect of Ethanolic Extract of *Annona Muricata* Leaf on the Testes and Prostate Gland of Male Albino Rats." *IOSR Journal of Pharmacy and Biological Sciences (IOSR-JPBS)* 14.2 (2019): 78-83.