

Scrub Typhus - An Overview

Dr.Nandita Basak

Abstract: Scrub typhus an emerging disease endemic to south east Asia pacific region. The disease is usually remains undiagnosed due to lack of specific clinically symptoms . Although it is not common/observed with pregnant woman but in rare cases leads to increased fetal loss, preterm delivery, and small for gestational age infants. Its main treatment is by the use of doxycycline. Scrub typhus can be prevented by using insect repellent and by avoidance of areas with lots of vegetation and bushes.

Key Words: Scrub typhus, chigger, tsutsugamushi, tsutsugamushi triangle,doxycycline,

Date of Submission: 12-05-2018

Date of acceptance: 29-05-2018

I. Introduction

Scrub typhus is an acute febrile disease caused by *O.tsutsugamushi* .It is transmitted by bites of larvae of trombiculid mites.It causes a disseminated vasculitic and perivascular inflammatory lesions resulting in significant vascular leakage and end-organ injury. It affects people of all ages and creeds.

Scrub typhus or bush typhus is caused by an intercellular parasite-*Orientia tsutsugamushi* (In Japan ‘tsutsuga’ means dangerous and ‘ mushi’ means bug).It is a gram negative alpha pro bacterium, is transmitted by mite larvae which feeds on both forest and rural rodents. These rodents acts as vector as well as natural reservoir for *O.tsutsugamushi* .

Scrub typhus was initially categorised in genus rickettsia,but it is now classified in a separate genus-orientia. It is 5um wide and 1.2-3um long. It is an obligator organism that can cultured in cell on layer. The organism is highly virulent and should be handled in laboratories with biosafety level 3 facilities.

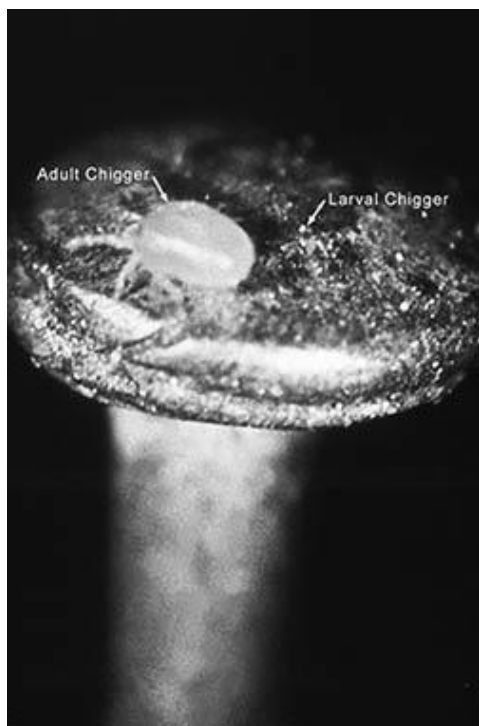


Fig 1: Adult and larval chigger

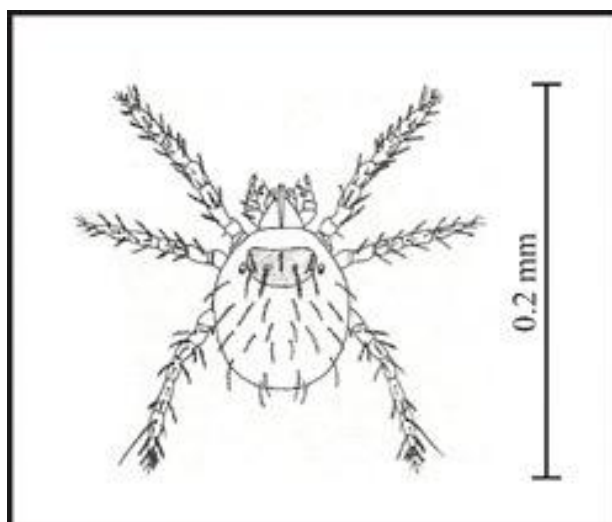


Fig 2: Chigger

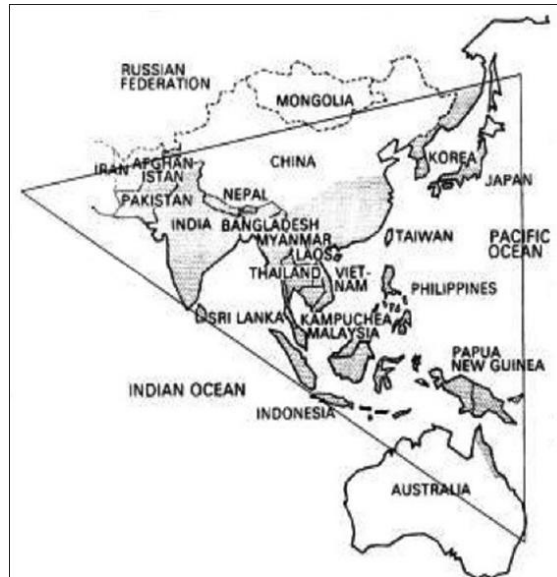


Fig 3: tsutsugamushi triangle

Scrub typhus is endemic to a part of the world known as *tsutsugamushi* triangle, named after *tsutsugamushi* species. This triangle extends from northern Japan and far eastern parts of Russia in the north to the territories around Solomon Sea into northern Australia in the south while to Pakistan and Afghanistan in the west. Scrub typhus is also endemic in homeports of South America too.

II. Clinical Features-

It is generally diagnosed by clinical symptoms like sudden onset of high grade fever associated with chills and rigor along with severe headache, body ache, muscle pain, rashes, gastrointestinal symptoms and lymphadenopathy. A primary papular lesion which later crusts to form a flat black eschar, may be present.

In severe case low BP, tachycardia, delirium, stupor and muscle twitching are also observed. Splenomegaly and Interstitial myocarditis are more common in scrub typhus compared to other rickettsial diseases. Typical lesion or eschar are common in whitish people but are rarely seen in Asian people (only 5% of the affected people have this lesion.).

Scrub typhus is rarely seen in pregnancy but if occurred it cause fatal outcomes like increased fetal loss, preterm delivery, and small for gestational age infants.

The Incubation period of scrub typhus is 6 to 21 days, during which eschar develops. The eschar usually develops as red, indurated lesions of about 1 cm diameter, it eventually vesiculates ruptures and became covered with black scab. Regional lymph nodes are enlarged.

III. INVESTIGATION

Scrub typhus is often misdiagnosed with pyrexia of unknown origin, enteric fever, typhoid fever, DHF, malaria, infection mononuclear, leptospirosis. headache often mimics trigeminal

TEST	RESULTS/ COMMENTS	RECOMMENDATION
WEIL FELIX	Detects cross reacting antibodies to proteus mirabile OXK	It is not very sensitive test, but is a specific test. Its
ELISA	Detects antibodies against infectious agents using pooled human sera as reference material	High sensitivity and specificity
RAPID LATERAL FLOW ASSAY	Assay using recombinant protein. positive test- purple colour for control test line of the cassette strip either IgG or IgM negative test- purple colour only on the cassette strip	Result is obtained in 10 mins, therefore can be used for fast detection

TEST	RESULTS/ COMMENTS	RECOMMENDATION
Western blot	Positive result- Presence of a 41-kD band on the film	High sensitivity and specificity
Indirect immunoperoxide	Any rickettsial strain can be used as the antigen, and either IgG or IgM antibodies could be titrated individually	Rapid and has high specificity and sensitivity
PCR	Can be performed as early as 3-4 days of fever phase, which is before the appearance of specific antibodies in the blood	Most sensitive diagnostic test ,but it is expensive test
Isolation	<i>O.tytsugamushi</i> can be isolated and cultured by inoculating it into white mice tissue	Not appropriate for routine diagnosis as it is expensive and laborious
Inoculation	Scrotal reaction following intraperitoneal injection of blood into male guinea pig	Obsolete test

Table 1: Different types of Diagnosis of scrub typhus

neuralgia. Owing to the potential for severe complication ,diagnosis and decision to initiate treatment should be based on clinical suspicion and confirmed by serological tests.

Laboratory tests -

Reveals leukopenia, thrombocytopenia, coagulopathy ,deranged hepatic and renal function, proteinurea and reticulonodular infiltrate or peribronchial intestinal infiltrate in chest x ray. CSF examination reveals mild mononuclear pleocytosis with normal glucose level

Serological tests -

- ◆ Weil Flex
- ◆ ELISA
- ◆ Western Blot
- ◆ Indirect Fluorescent Assay
- ◆ Rapid Lateral flow assay
- ◆ PCM
- ◆ Isolation
- ◆ Inoculation

Primary treatment or 1st line treatment is tetracycline drug, most commonly used is Doxycycline, following which rifampicin and azithromycin are used. As *O.tytsugamushi* lacks the classical peptidoglycan cell wall so beta lactic antibiotics are resistant ,while aminoglucoisides are ineffective as they cannot penetrate intracellularly.

Second line of treatment includes chlorophenicol. Commercial vaccine of scrub typhus is still not available as no single vaccine is available which can prevent all types of typhus strain.

IV.PRECAUTION

Scrub typhus can be avoided by following steps-

- Avoid areas with lot of vegetation and bushes where scrub typhus is common.
- Use insect repellent that contains 20%-30% DEET or other active ingredient that is used against chiggers.
- Use of protective clothing impregnated with benzyl benzoate.

V. Conclusion

Scrub typhus is a growing and emerging disease in underdeveloped and developing countries as it is grossly undiagnosed. It is due to its nonspecific clinical presentation, limited awareness and low index of suspicion among clinician and lack of diagnostic features. Early diagnose and treatment can reduce the mortality and complication associated with the disease.

Reference:

- [1]. Hornick RB. Rickettsial Diseases. In: Bennett JC, Plum F, editors. Goldman: Cecil Textbook of Medicine. 21st ed. Philadelphia, USA: WB Saunders Company; 2000. pp. 1911–2. (Chapter 371).
- [2]. Walker DH, Dumler JS, Marrie T. Rickettsial Diseases. (Part 8, Section 10, Chapter 174) In: Longo DL, Fauci AS, Kasper DL, Hauser SL, Jameson JL, Loscalzo J, editors. Harrison's Principle of Internal Medicine. 18th ed. USA: The McGraw-Hill Companies; 2012. pp. 1064–5.
- [3]. Dumler JS, Siberry GK. Scrub Typhus (Orientia Tsutsugamushi). (Part XVI. Section 11. Chapter 226) In: Kliegman RM, Behrman Re, Jenson HB, Stanton BF, editors. Nelson Textbook of Pediatrics. 18th ed. Philadelphia: Saunders, Elsevier; 2007. pp. 1295–6.
- [4]. Chang WH. Current status of tsutsugamushi disease in Korea. J Korean Med Sci. 1995;10:227–38. [PMC free article] [PubMed]
- [5]. Mahajan SK. Scrub typhus. J Assoc Physicians India. 2005;53:954–8. [PubMed]
- [6]. Mahajan SK, Kashyap R, Kanga A, Sharma V, Prasher BS, Pal LS. Relevance of Weil-Felix test in diagnosis of scrub typhus in India. J Assoc Physicians India. 2006;54:619–21. [PubMed]
- [7]. Singh P. Scrub typhus, a case report: Military and regional significance. Med J Armed Forces India. 2004;60:89–90.
- [8]. Corrales-Medina VF, Shandera W. Viral-Rickettsial Infections (Chapter 32) In: Mc Phee SJ, Papadakis MA, editors. Current Medical Diagnosis and Treatment. 50th ed. USA: Mc Graw Hill companies; 2011. p. 1283.
- [9]. Kim D, Kim SW, Choi SH, Yun NR. Clinical and laboratory findings associated with severe scrub typhus. BMC Infect Dis. 2010;10:108. [PMC free article] [PubMed]
- [10]. Blacksell SD, Bryant NJ, Paris DH, Doust JA, Sakoda Y, Day NP. Scrub typhus serologic testing with the indirect immunofluorescence method as a diagnostic gold standard: A lack of consensus leads to a lot of confusion. Clin Infect Dis. 2007;44:391–401. [PubMed]
- [11]. Koh GC, Maude RJ, Paris DH, Newton PN, Blacksell SD. Diagnosis of scrub typhus. Am J Trop Med Hyg. 2010;82:368–70. [PMC free article] [PubMed]
- [12]. Raoult D. Orientia tsutsugamushi. In: Mandell GL, Bennett JE, Dolin R, editors. Principles and Practice of Infectious Diseases. 7th ed. Philadelphia: Churchill Livingstone; 2009. pp. 2529–30.
- [13]. Wallach J. 8th ed. Philadelphia: Lippincott Williams and Wilkins; 2009. Interpretation of diagnostic tests; p. 950.
- [14]. Saah AJ. Orientia tsutsugamushi (Scrub Typhus) In: Mandell GL, Bennet JE, Doalin R, editors. Principles and Practice of Infectious Diseases. Philadelphia: Churchill Livingstone; 2000. pp. 2056–7.
- [15]. Jacobson RH. Validation of serological assays for diagnosis of infectious diseases. Rev Sci Tech. 1998;17:469–526. [PubMed]
- [16]. Jang WJ, Huh MS, Park KH, Choi MS, Kim IS. Evaluation of an immunoglobulin M capture enzyme-linked immunosorbent assay for diagnosis of Orientia tsutsugamushi infection. Clin Diagn Lab Immunol. 2003;10:394–8. [PMC free article] [PubMed]

Dr.Nandita Basak "Scrub Typhus - An Overview. "IOSR Journal of Pharmacy and Biological Sciences (IOSR-JPBS) 13.3 (2018): 33-36.