

## Inhibitory Activity of Lycopene on Cypermethrin- Induced Hepatotoxicity and Liver Injury in Malesprague-Dawley Rats

Adetutuolubunmi Godwin-Obulor<sup>1</sup> And Eme Efiowan Orlu<sup>2</sup>

Department Of Animal and Environmental Biology Rivers State University, P.M.B 5080, Nkpolu-Oroworukwo, Rivers State Port Harcourt ,Nigeria

Corresponding Author: Adetutuolubunmi Godwin-Obulor

---

**Abstract:** Increased use of pesticides all over the world is alarming and has attracted researchers due to the adverse effect on vital organs and reproduction. Cypermethrin is a synthetic Pyrethroid. The use of natural antioxidants in the reduction of oxidative stress and liver injury is gaining awareness because they are less expensive, readily available and exhibit no adverse effects. This research was thus undertaken to evaluate the hepatotoxicity of Cypermethrin and the inhibitory effect of Lycopene. All biomarkers in the group administered Cypermethrin only, showed significantly ( $p < 0.05$ ) elevated levels of biomarkers, necrosis, degeneration of hepatocytes, infiltration of lymphocytes in the portal vein, indicating that Cypermethrin induced oxidative stress and liver injury in the exposed rats. A comparison of the trend in the levels of liver biomarkers and Histopathological micrographs of the other groups studied strongly suggests that processed *Solanum lycopersicum* possesses antioxidant capability, inhibits Cypermethrin – induced stress, provides a boost for healing of the liver injury via mitotic division of hepatocytes and its regeneration. It is concluded that, full potential of antioxidant activity in fresh *S. lycopersicum* cannot be unlocked because mammals lack cellulase. Thus, its efficacy is highest in pure lycopene >processed>fresh fruits.

**Keywords:** Biomarkers, Cypermethrin, liver injury, lycopene, hepatocyte mitosis

---

Date of Submission: 23-02-2018

Date of acceptance: 10-03-2018

---

### I. Introduction

The increased use of pesticides all over the world is alarming and this has drawn the attention of researchers due to the adverse effects they have on non-target organisms. Cypermethrin, a type II synthetic Pyrethroid is an active ingredient in indoor and outdoor insecticides hence the risk associated with Cypermethrin exposure largely occurs in the home. This group of Pyrethroid can bio-accumulate in adipose tissues, brain cells and liver of rodents [1]. Residues of Cypermethrin are found on walls, in air, furniture and floor after three months of household treatment [2]. Several studies have shown that pyrethroids cause liver injury, alteration in liver biomarkers and induction of oxidative stress [3,4,5,6,7,]. An induction of liver cell damage with a significant increase in the activities of the transaminases in Deltamethrin exposed rats [8,9], disruption of hepatic and renal function causing DNA damages in pubescent female rats has also been reported [10]. However, report showed that oral administration of *Allium sativum* extract and Vitamin C caused a significant restoration of normal liver biomarkers activities induced by Deltamethrin [11]. A positive correlation between pyrethroid insecticides such as prallethrin and liver damages has been reported [12].

Biological defense mechanisms against intracellular oxidative stress induced by pesticides are present in the organism as antioxidant enzymes and non-enzymatic antioxidants including carotenoids, vitamin E, Vitamin C, glutathione and Coenzyme Q10. The use of natural plant based antioxidant in the reduction of oxidative stress and liver injury is gaining awareness because they are less expensive, readily available and exhibit no adverse side effect. Due to the distinctive ability of antioxidants to neutralize free radicals, exhibit inhibitory effect towards degenerative in animals and also in man this research was undertaken to evaluate the possible protective ability of Lycopene against Cypermethrin induced Hepatotoxicity.

### II. Material And Methods

#### 2.1 Experimental Location

The study was carried out in the Reproductive Physiology and Genetics Research Laboratory of the Department of Animal and Environmental Biology, Rivers State University, Port Harcourt Nkpolu-Oroworukwo Rivers State [Coordinates: 4°47' 50" N 6° 58' 49" E]. The experiment was conducted from December 2016 to March 2017.

#### 2.2 Experimental animals and management protocol

Twenty-eight sexually matured male Sprague-Dawley rats (mean weight  $236 \pm 35.6$ g) were obtained from the Department of Biochemistry, University of Port Harcourt, Nigeria. The rats were housed individually in plastic cages under standard conditions (12 hL:12hD, ) and acclimated for two weeks prior to the commencement of the experiment. All animals were fed with standard rodent pellet and cool clean water *ad libitum*. All experiments were conducted according to the institutional animal care protocols at the Rivers State University, Nigeria and followed approved guidelines for the ethical treatment of experimental animals [ 9]

### 2.3 Experimental design and procedure

Twenty eight adult male Sprague-Dawley rats were assigned to seven groups (A-G) of 4 (four) rats each. Group (A) received neither Cypermethrin nor lycopene and so acted as control, Group B received Cypermethrin Emulsifiable Concentrate (EC) diluted to 30mg/kg/bw/day dissolved in canola oil. Group (C and D) 5,000 and 10,000 mg/kg/bw of processed *Solanum lycopersicum* dissolved in distilled water, Group (E and F) 5,000 and 10,000mg/kg/bw/day of blended *Solanum lycopersicum*. Group G received 10mg/kg/bw/day of pure lycopene capsule. All the groups were exposed to their treatment by oral gavage for 70 days. All animals were observed daily for behavioral changes; signs of intoxication, mortality, morbidity as well as food and water intake. Animals were weighed twice a week and the average weight per week recorded to the nearest 0.01 g

### 2.4 Biochemical analysis

Blood samples for biochemical analysis were collected as reported in [12, 13]. The samples were collected individually by cardiac puncture into sterile tubes and the serum separated at 2500 g for 10 min and stored for determination of Alanine aminotransferase (ALT) [14] and Aspartate aminotransferase (AST) [15] Alkaline Phosphatase (ALP) [16,17].

### 2.5 Histopathological analysis of the Liver

Known weight of the liver was fixed in 10% neutral formalin and sectioned with a digital (AO spencer No. 820) at 5µm thick. Histological sections mounted on slides was stained with Hematoxylin and Eosin(H&E) according to [18]. Photomicrographs were generated with a digital Microscope Biosphere Miller B with an image processor DN2-Microscopy Image Processing Software [19] at X100 magnification.

### 2.6 Statistical analysis

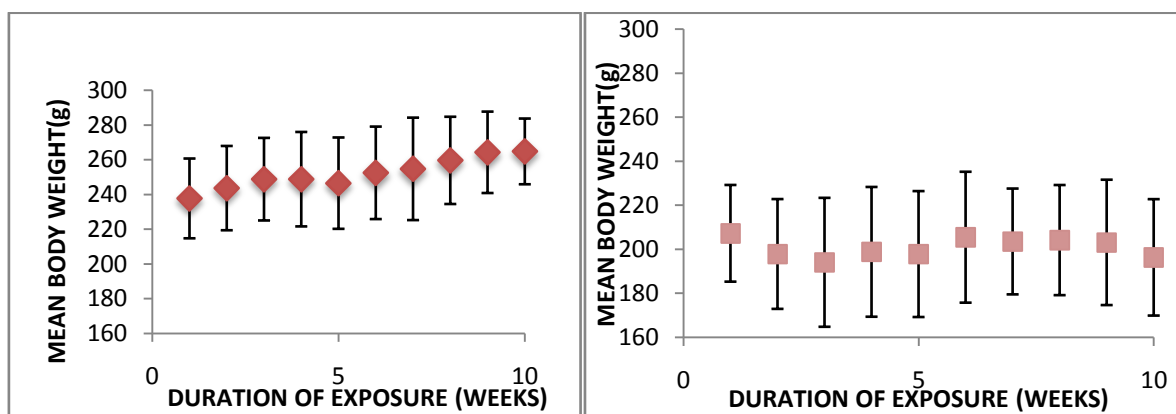
Data from biochemical analyses were subjected to one-way ANOVA; where significant differences were found, Pair-wise mean comparisons were conducted with Tukey test using SPSS 20 software. Spearman Rank correlation was used to assess relationship between each biochemical parameters.  $P > 0.05$ ,  $df = 20$

## III. Results

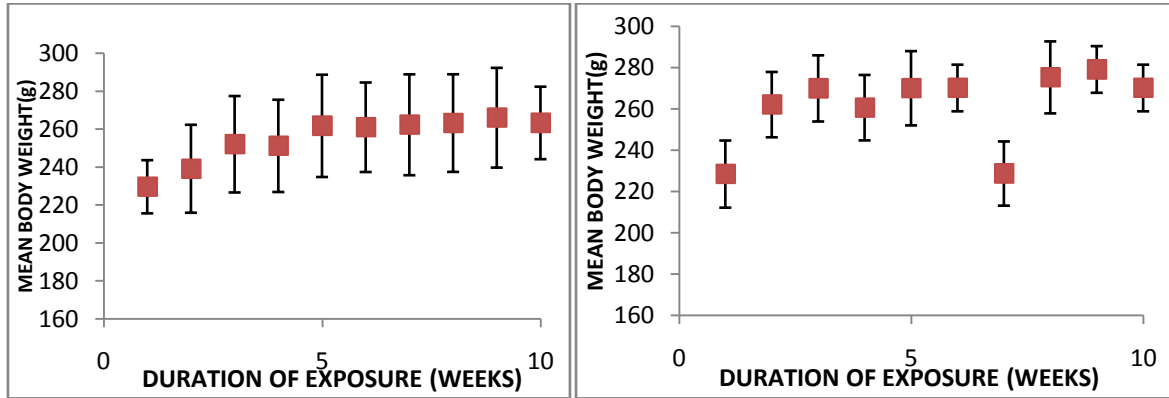
### 3.1 The effect Cypermethrin and Lycopene on bodyweight

The effect co-administration of Cypermethrin and Lycopene on body weight of Sprague-Dawley rat is shown on Figure 1a-g.

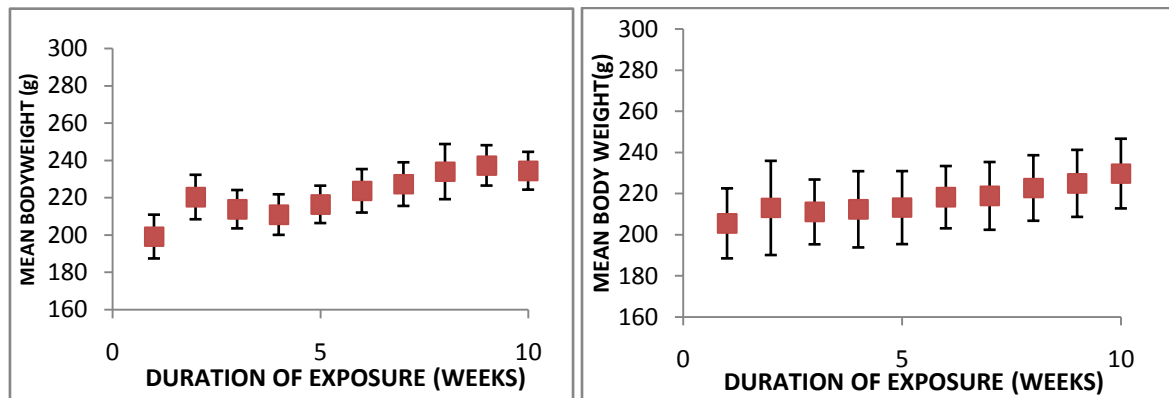
There was progressive non-significant increase in the body weight of experimental animals from week one to week 10. Animals in group B administered Cypermethrin only showed a steady non-significant decrease in bodyweight from week one to ten (see fig. 1a-g).



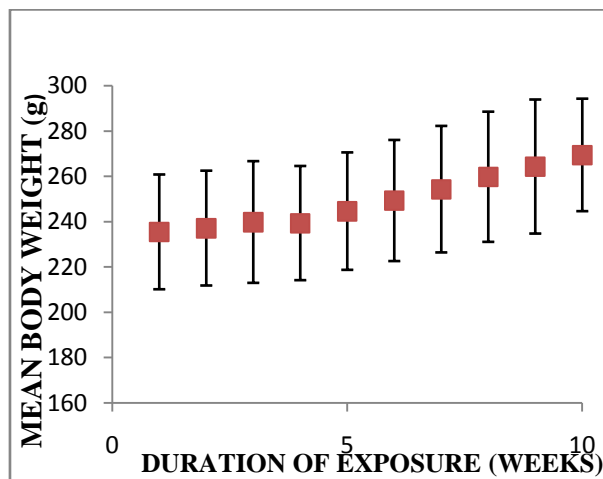
**Fig 1a:** Body weight of Animals in control (group A) **Fig 1b:** B Animals administered Cypermethrin only (group B)



**Fig 1c:** Body weight of animals administered with Cypermethrin and 5,000mg/kg/bw of *P.Solanum lycopersicum* (group C) **Fig 1d:** Body weight of animals administered with Cypermethrin and 10,000mg/kg/bw of *P.Solanum lycopersicum* (group D)



**Fig 1e:** Body weight of animals administered with Cypermethrin and 5,000mg/kg/bw of *F.Solanum lycopersicum* (group E) **Fig 1f:** Body weight of animals administered with Cypermethrin and 10,000mg/kg/bw of *F.Solanum lycopersicum* (group F)



**Fig 1g:** Body weight of animals administered with Cypermethrin and 10mg/kg/bw of Pure Lycopene (group G)  
**Fig.1a-g** Effect of Co-administration of Cypermethrin and Lycopene anti-oxidant for on the bodyweight of Sprague-Dawley Rat

### 3.2 Effect of co-administration of Cypermethrin and lycopene on liver weight

The mean weight of the Liver evaluated throughout the experiment is shown in Fig.2 and revealed no significant difference from the control group A, the Groups B,C,D,E and F, co-administered Cypermethrin and *Solanum lycopersicum* at 5000 and 10,000mg/kg/bw/day, as well as, Group F administered pure Lycopene with Cypermethrin. Groups B,C,D,E showed decrease in the liver weight which was statistically non-significant (Fig.2).

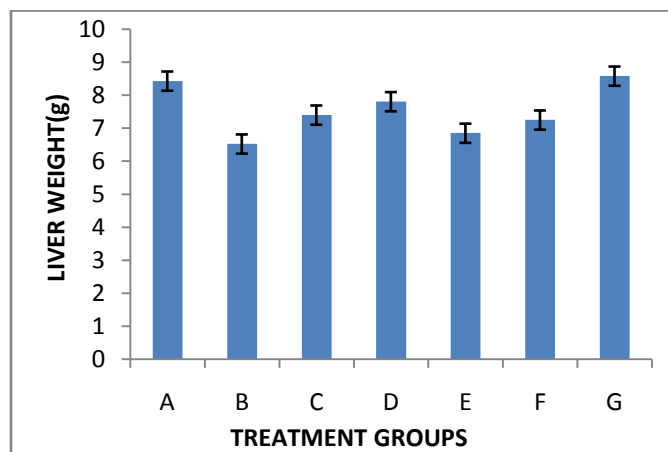


Fig. 2: Mean weight (Mean±SD) of liver of Rat after 70 days co-administration of Cypermethrin and Lycopene

### 3.3 Liver Biomarkers

The concentrations of the Liver biomarkers in Sprague-Dawley Rats exposed concomitantly to Cypermethrin and Lycopene is shown in Table 1. The concentration of Glucose increased from 3.53±0.32 in the control group to 6.33±0.47 in the group that received pure lycopene, a difference significant at p< 0.05. All other groups co-administered processed *S.lycopersicum* and fresh *S.lycopersicum* showed steady increase in glucose except B administered Cypermethrin alone. However, variation in the means were not statistically significant. The values of Total cholesterol also showed no statistically significant variation among the experimental groups. Other Liver biomarkers, AST, ALP and ALT showed statistically significant increase in concentration in all the groups exposed to Cypermethrin and Lycopene (see Table 1)

Table 1: Mean ±SD concentration of Liver Biomarkers of Sprague-Dawley Rat Co-administered Cypermethrin and Lycopene for 70 days

| GROUPS        | GLU(mmol/L)              | T.CHOL. (mmol/L)         | AST(IU/L)                   | ALT(U/L)                 | ALP(U/L)                  |
|---------------|--------------------------|--------------------------|-----------------------------|--------------------------|---------------------------|
| A             | 3.53±0.32 <sup>a</sup>   | 2.80±0.10 <sup>a</sup>   | 79.33±1.15 <sup>ab</sup>    | 65.33±5.51 <sup>b</sup>  | 77.67±4.04 <sup>b</sup>   |
| B             | 3.00±0.30 <sup>a</sup>   | 3.00±0.87 <sup>a</sup>   | 91.67±30.35 <sup>b</sup>    | 75.67±20.65 <sup>b</sup> | 86.00±20.95 <sup>ab</sup> |
| C             | 4.10±0.72 <sup>a</sup>   | 2.37±0.21 <sup>a</sup>   | 70.33±7.77 <sup>ab</sup>    | 56.33±8.96 <sup>ab</sup> | 67.00±7.55 <sup>ab</sup>  |
| D             | 3.77±0.42 <sup>a</sup>   | 2.50±0.10 <sup>a</sup>   | 71.00±2.00 <sup>ab</sup>    | 55.67±3.51 <sup>b</sup>  | 75.00±3.00 <sup>ab</sup>  |
| E             | 4.10 ± 0.53 <sup>a</sup> | 2.23 ± 0.38 <sup>a</sup> | 81.67 ± 10.50 <sup>ab</sup> | 70.33±6.66 <sup>b</sup>  | 63.00 ± 9.54 <sup>b</sup> |
| F             | 4.40±1.73 <sup>a</sup>   | 2.30±0.20 <sup>a</sup>   | 86.00±22.72 <sup>b</sup>    | 66.67±26.65 <sup>b</sup> | 50.67±8.51 <sup>a</sup>   |
| G             | 6.33±0.47 <sup>b</sup>   | 5.03±0.15 <sup>b</sup>   | 50.00±2.00 <sup>a</sup>     | 22.67±3.51 <sup>a</sup>  | 47.67±2.52 <sup>a</sup>   |
| Anova F-value | 4.44                     | 19.78                    | 3.37                        | 7.78                     | 8.99                      |
| Sig           | 0.01                     | 0.00                     | 0.03                        | 0.00                     | 0.00                      |

\*Value are Mean±SD. Values with same superscripts<sup>(a)</sup> in the column are not significantly different, while those with different superscript<sup>(ab)</sup> are significantly different (P < 0.05).

The intra specific relationship of the Liver biomarkers evaluated by correlation analysis indicated a high correlative relation between glucose and all other biomarkers assessed, glucose was positively and significantly correlated with total cholesterol (r = 0.805, p < 0.05, R<sup>2</sup> = 0.6480), negatively but significantly correlated to AST (r = - 0.776 p < 0.01, R<sup>2</sup> = 0.6022) ALT, r = - 0.901 p < 0.01, R<sup>2</sup> = 0.8118), ALP (r = - 0.766, p < 0.01, R<sup>2</sup> = 0.5867) and total protein r = -0.457, p < 0.05, R<sup>2</sup> = 0.2088) (see Table 2) Total cholesterol was also negatively correlated to AST (r = -0.790, p < 0.01), ALT (r = -0.685, p < 0.01), ALP (r = -0.482, p < 0.05) Total protein (r = -0.517, p < 0.05).

**Table 2:** Correlation analysis of some liver biomarkers in Sprague-Dawley rats exposed to Cypermethrin and co-administration of Lycopene.

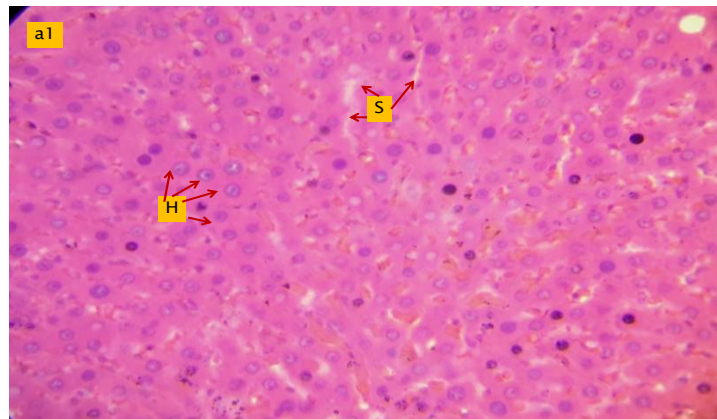
| INDEPENDENT VARIABLES      | DEPENDENT VARIABLES |         |          |          |          |         |
|----------------------------|---------------------|---------|----------|----------|----------|---------|
|                            | 1                   | 2       | 3        | 4        | 5        | 6       |
| Glucose (mmol/L)           | 1                   | 0.805** | -0.776** | -0.901** | -0.766** | -0.457* |
| Total Cholesterol (mmol/L) |                     | 1       | -0.790** | -0.685** | -0.482*  | -0.517* |
| AST(IU/L)                  |                     |         | 1        | 0.898**  | 0.369    | 0.365   |
| ALT(U/L)                   |                     |         |          | 1        | 0.531*   | 0.378   |
| ALP(U/L)                   |                     |         |          |          | 1        | 0.135   |
| Total Protein              |                     |         |          |          |          | 1       |

\*Values are significant at P<0.05

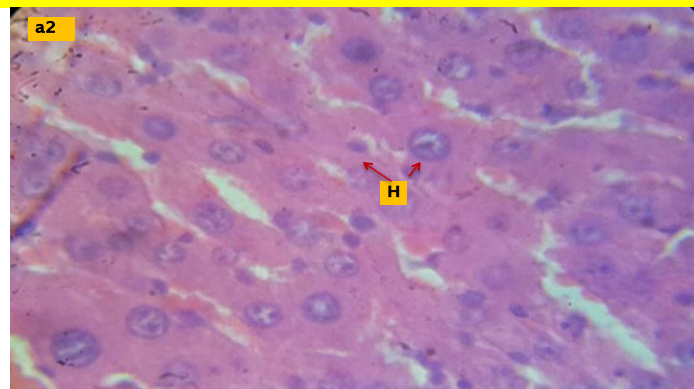
\*\* Values are significant at P<0.01

### 3.4 Histopathological evaluation of the Liver

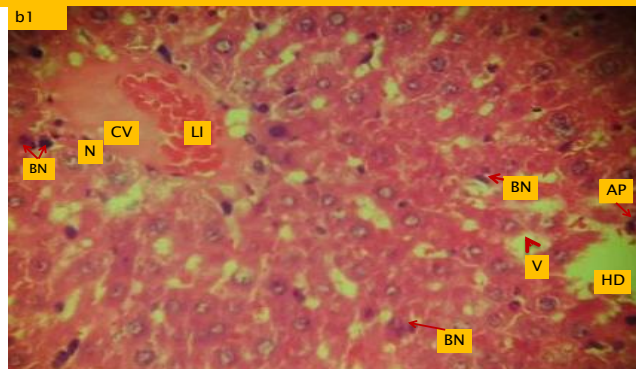
Histopathological examination of the H & E sections of the liver of the experimental animals revealed the following: The epithelium of the animals in the control group A showed the normal liver hepatocytes (H) with the characteristic polygonal cellular architecture and liver sinusoid (s) (Fig.a1 and a2 at Mag.x40 & x100 respectively). Atypical hepatocyte and lesions were observed in the liver of animals exposed to 30mg/kg/bw<sup>-day</sup> without co-administration of fresh *Solanum lycopersicum*, processed form or pure lycopene (Fig.b1x40&b2x 100). This injury to the liver by the pesticide was also indicated by the statistically significant (p<0.05) elevation of all the liver biomarkers, except Glucose. The central portal vein was infiltrated with lymphocytes (LI). Epithelium became vacuolated linked to hepatocyte degeneration, necrosis and apoptosis. Some binucleated hepatocytes were also observed. With co-administration of processed *S.lycopersicum* at 5000mg/kg/bw/day, regeneration of necrotic hepatocytes (HR) was observed, there was a ten-fold increase in the number of binucleated hepatocytes (BN) (Fig.c1 x40 & c2 x100) dilation of the sinusoids was observed. Liver epithelium of rats co-administered 10,000mg/kg/bw/day (Fig1d1 x40 & d2 x100) exhibited fewer lesions, but binucleated hepatocytes were observed, many hepatocytes at various stages of mitotic divisions were captured (HDV) as well as hepatocyte regeneration. Fig.1:e1 X40,e2 X 100) shows an epithelium of Sprague-Dawley rat exposed fresh *S.lycopersicum* @ 5,000mg/kg/bw/day along with Cypermethrin @ 30mg/kg/bw/day. The hepatocytes have regenerated with approximately 50% hepatocytes mitotic division. The epithelium appeared to have partially recovered from the injuries induced by Cypermethrin exposure. This trend of recovery was also observed in ( Fig.1:f1X40 & f2 X100) of epithelium of rat exposed to 10,000mg/kg/bw/day of fresh *S.lycopersicum*. The epithelium of animals exposed to 10mg/kg/bw/day are presented in Fig.1:g1 X40 & g2 X100. The hepatocytes appear to have fully recovered from the cypermethrin-induced hepatotoxic effect and become fully regenerated.



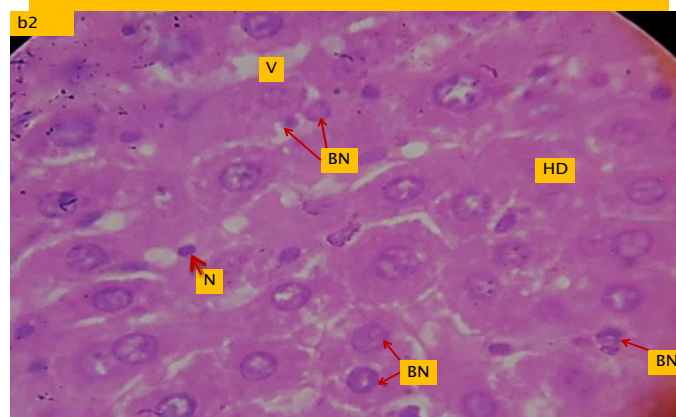
**Plate 1 a: PHOTOMICROGRAPH OF LIVER SECTION OF CONTROL ANIMALS STAINED WITH HEMATOXYLIN & EOSIN X 40**



**PLATE 1 b: PHOTOMICROGRAPH OF LIVER OF CONTROL ANIMALS STAINED WITH HEMATOXYLIN & EOSIN X 100**



**Plate 2 a: HISTOPATHOLOGICAL MICROGRAPH OF LIVER OF RAT EXPOSED TO CYPERMETHRIN @ 30 mg/kg/bw/day X 40**



**Plate 2 b: HISTOPATHOLOGICAL MICROGRAPH OF LIVER OF RAT EXPOSED TO CYPERMETHRIN @ 30 mg/kg/bw/day X 100**



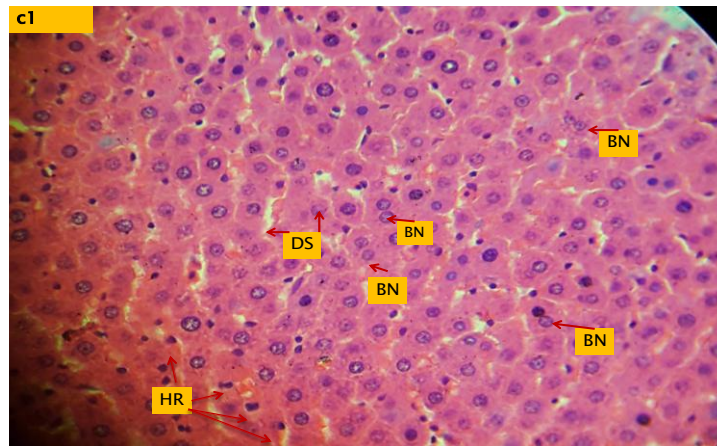


Plate3a: HISTOPATHOLOGICAL MICROGRAPH OF LIVER OF RAT EXPOSED TO CYPERMETHRIN AND 5,000mg/kg/bw /day of *P. Solanum lycopersicum* Mag.x400

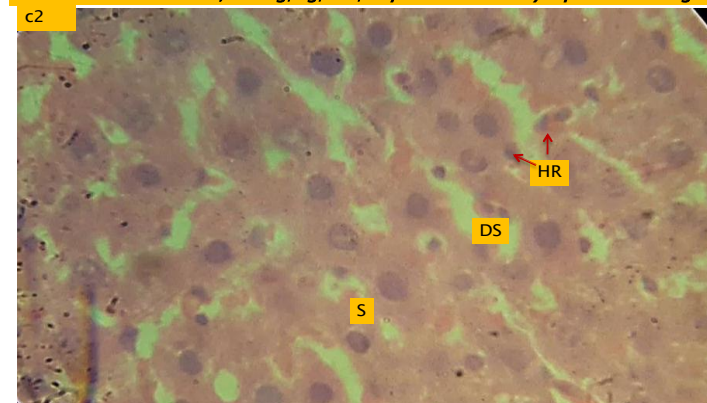


Plate3b: HISTOPATHOLOGICAL MICROGRAPH OF LIVER OF RAT EXPOSED TO CYPERMETHRIN AND 5,000mg/kg/bw/day of *P. Solanum lycopersicum* X100

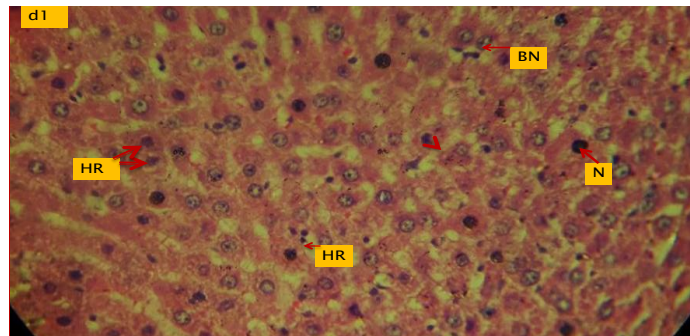


Plate4a: HISTOPATHOLOGICAL MICROGRAPH OF LIVER OF RAT EXPOSED TO CYPERMETHRIN & 10,000mg/kg/bw/day *P. Solanum lycopersicum* X40

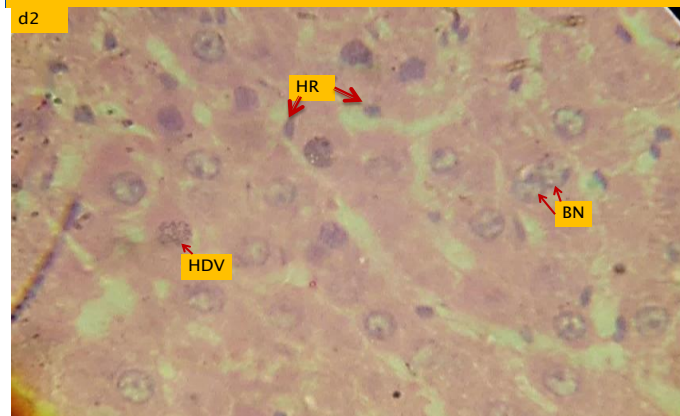


Plate4b: HISTOPATHOLOGICAL MICROGRAPH OF LIVER OF RAT EXPOSED TO CYPERMETHRIN & 10,000mg/kg/bw/day *P. Solanum lycopersicum* X100

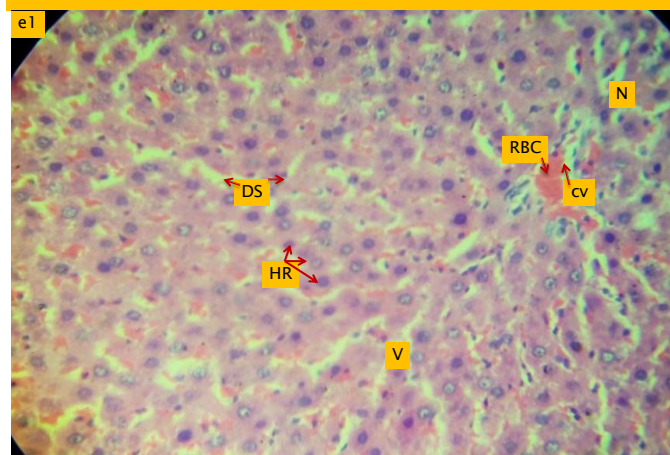
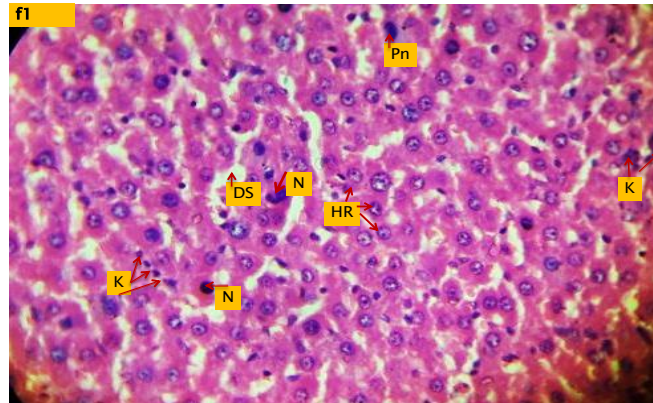


Plate 5a: HISTOPATHOLOGICAL MICROGRAPH OF LIVER OF RATS EXPOSED TO CYPERMETHRIN AND 5000mg/kg/bw/day *F. Solanum lycopersicum* X40

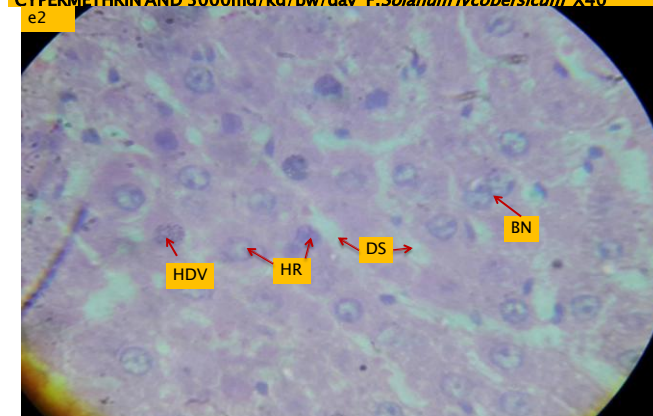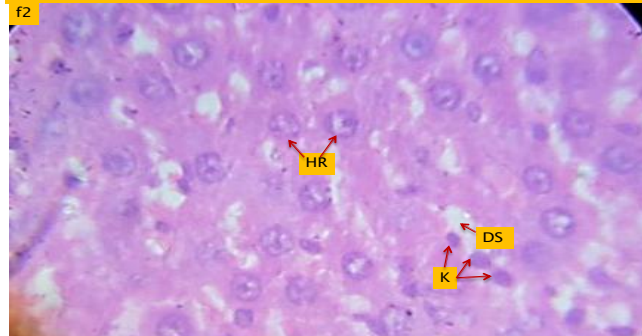


Plate5b: HISTOPATHOLOGICAL MICROGRAPH OF LIVER OF RAT EXPOSED TO CYPERMETHRIN AND 5,000mg/kg/bw *F. Solanum lycopersicum* X100

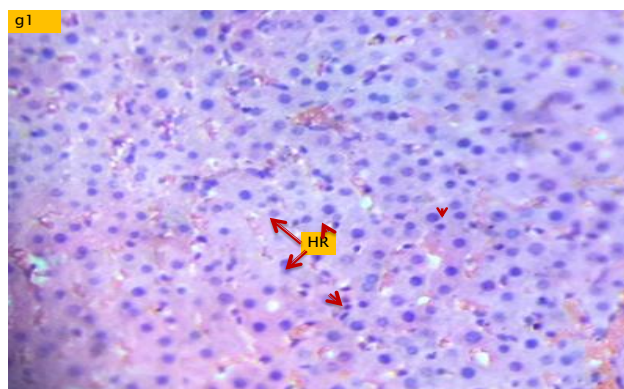




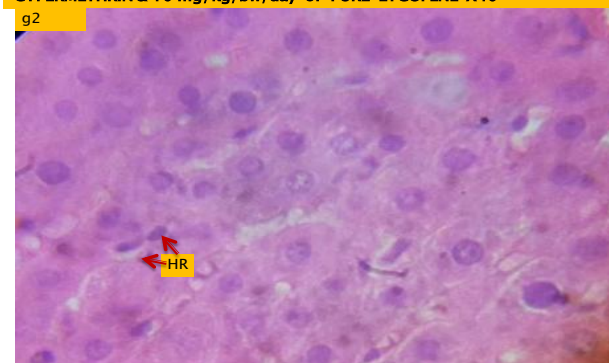
**PLATE6a: HISTOPATHOLOGICAL MICROGRAPH OF LIVER OF RAT EXPOSED TO CYPERMETHRIN 10,000mg/kg/bw/day F. *Solanum lycopersicum* .X40**



**Plate6b: HISTOPATHOLOGICAL MICROGRAPH OF LIVER OF RAT EXPOSED TO CYPERMETHRIN & 10,000mg/kg/bw/day F. *Solanum lycopersicum* . mag X100**



**Plate 7a: HISTOPATHOLOGICAL MICROGRAPH OF LIVER OF RAT EXPOSED TO CYPERMETHRIN & 10 mg/kg/bw/day of PURE LYCOPENE X40**



**Plate 7b: HISTOPATHOLOGICAL MICROGRAPH OF LIVER OF RAT EXPOSED TO CYPERMETHRIN & 10 mg/kg/bw/day of PURE LYCOPENE X 100**

**FIG.1a-g** shows the Histopathological micrographs of the liver of Sprague-Dawley rat exposed to Cypermethrin 30mg/kg/bw<sup>-day</sup> and co-administered pure Lycopene, Fresh and Processed *Solanum lycopersicum* @ 5000 and 10,000mg/kg/bw<sup>day</sup>. **Fig.1a** (Mag.x10 and 40 respectively) are H&E cross sections from control group and shows the typical hepatocyte architecture with normal sinusoids(**H**)(**s**) **Fig.1b**:BN =Binucleated hepatocytes,CV=Central Vein V=vacuolation,HD=Hepatocyte degeneration,LI=lymphocyte infiltration of central vein.N=necrosis.

**Fig.1c**:BN=Binucleated hepatocytes,HDV=Hepatocyte division/mitotic figures. **Fig.1d**:HR=hepatocyte regeneration.

**Fig.1e**:K=karyokinesis. **Fig.1g** HR=fully regenerated epithelium ,hepatocyte number restored

#### IV. Discussion

The organ that carries out the process of metabolism and detoxification is the liver being the first point of contact for all metabolites, Xenobiotics become bio-transformed in the liver by the action of metabolizing enzymes, microsomal enzymes, aminotransferases, and oxygenases[9]. The liver possesses inducible enzyme systems that confer on it the flexibility to regulate the expression of genes to be transcribed, biosynthesized into enzymes for metabolism of numerous metabolites and toxicants. The liver has a remarkable capacity to regenerate following injuries by undergoing rapid mitotic division as observed in the epithelium exposed to Cypermethrin in this study. This injury to the liver by the pesticide was also indicated by the statistically significant ( $p < 0.05$ ) elevation of all the liver biomarkers, except Glucose. The central portal vein was infiltrated with lymphocytes (LI). Epithelium became vacuolated due to hepatocyte degeneration, necrosis and apoptosis. Some bi-nucleated hepatocytes were also observed ((Fig.1:b1 and b2)). Mitotic division was noted as some hepatocytes were captured at specific stages of mitotic division (Fig.1d). The increase in the number of hepatocytes in Fig.1:c-g) is indicative that most of the metabolic activities are carried out by the hepatocytes, necessitating rapid regeneration by mitotic division. Reports by other researchers have agreed that Cypermethrin, a Pyrethroid causes liver injury, elevation in the levels of Liver biomarkers vis-a-vis induction of oxidative stress[3,4,5,6,7,8,9,10]. Co-administration of processed *Solanum lycopersicum* in Fig.c-d) at 5,000 and 10,000mg/kg/bw/day respectively, appears to have exhibited antioxidant activity by boosting the regenerative activity of the hepatocytes as seen in the almost 10% increased number of bi-nucleated hepatocytes. There was a minimal difference in the epithelium of rats co-administered fresh *Solanum lycopersicum* at the same concentrations (Fig.1:e-f) However, based on the number of regenerated hepatocytes, it appears the processed *S.lycopersicum* conferred greater antioxidant activity than the fresh, perhaps based on the lack of cellulose enzymes in the rat liver enzyme system. Close observation of the liver Histopathological

micrographs following the co-administration of pure Lycopene in Fig.1g shows an epithelium that has completely undergone regeneration and with integrity of the hepatocyte architecture restored. A casual look at Fig.1:c-d and indeed e-f shows liver micrographs difficult to distinguish from that of the control animal. The concentrations of the liver biomarkers Aspartate aminotransferase, Alanine aminotransferase, Alkaline phosphatase and Glucose increased non-significantly from  $79.33 \pm 1.15$  to  $81.67 \pm 10.50$  in group C & D co-administered 5,000 and 10,000mg/kg/bw/day of fresh *Solanum lycopersicum*. In groups E & F, where animals were co-administered 5,000 and 10,000mg/kg/bw/day of processed *S.lycopersicum*, the values of biomarkers were observed to be even lower than the control (see Table 1). All biomarkers in group B administered Cypermethrin only showed significantly ( $p < 0.05$ ) elevated levels compared to the control, an indication that Cypermethrin induced oxidative stress in the exposed rats. A comparison of the trend in the liver biomarkers and Histopathological micrographs of the groups studied strongly suggested that processed *S.lycopersicum* not only possesses an antioxidant capability by inhibiting oxidative stress induced by administration of cypermethrin but also provides a boost for healing of the liver injury based on the observation of mitotic division of the hepatocytes and subsequent hepatocyte regeneration

In the light of these observations, it is, therefore, concluded that fresh *S.lycopersicum* possesses some antioxidant activity, but its full potential cannot be unlocked by mammals without cellulase enzyme or by mechanically destroying the cellulose. Thus, in terms of its efficacy it was observed that pure lycopene >processed> fresh fruits of *S.lycopersicum*.

### References

- [1]. Hallegue, D., Tebourbi, O, Kacem K, Sakly M, Ben Rhouma K. (2010). Impact of dieldrin on liver morphological and biochemical parameters of rats. *Toxicol. Ind Health*: 26(3):131-137
- [2]. Wright, C.G., Leigy, R.B., Dupree, H.E. (1993). Cypermethrin in the ambient air and on surfaces of rooms and treated for cockroach. *Bulletin of Environmental contamination and toxicology*. 5(3).356-60.
- [3]. Giray, B., Gürbay, A., Hincal, F. (2001). Cypermethrin-induced oxidative stress in rat brain and liver is prevented by Vitamin E or allopurinol. *Toxicology Letters*. 118(3). 139-46.
- [4]. Gomaa, M S., Abd Alla, M. A., Sameer, M. M. (2011). The possible protective effect of propolis (Bee glue) on cypermethrin-induced hepatotoxicity in adult albino rats. *J. Forensic Med. Clin. Toxicol*. 19(1). 17-32.
- [5]. Dubey, N., Khan, A.M., Raina, R. (2013). Subcutaneous deltamethrin and fluoride toxicity induced hepatic oxidative stress and biochemical alterations in rats. *Bulletin of Environmental contamination and toxicology*. 91(3).334-338
- [6]. Soliman, M.M., Altia, H.F., El-Ella, G.A. (2015). Genetic and histopathological alterations induced by Cypermethrin in rat kidney and Liver: Protection by Sesame oil. *Int. J. Immunopathol. Pharmacol*. 28(4)508-20.
- [7]. Mossa, A.T., Heikal, T.M., Belaiba, M., Raoelison, E.G., Ferhourt, H., Bouajila, J. (2015). Antioxidant activity and hepatoprotective potential of *Cedrelopsis grevei* on Cypermethrin induced oxidative stress and liver damage in male mice. *BMCComplement Altern. Med*. 15: 251-261.
- [8]. Orlu, E.E. 2014 Deltamethrin-Induced Alterations in Sperm Morphology and Spermatogenesis Impairment in Adult male of Sprague-Dawley rats. *Research Journal of Applied Science, Engineering and Technology* 7,(11), 2324-2331
- [9]. Marwa, N., Ghada, B.S., Hassen, K., Fatma, M.A., Abdelmajid, K., Abdelfattah, E., Mongi, S. (2015) Histopathological, oxidative damage, biochemical and genotoxicity alterations in hepatic rats exposed to deltamethrin: modulatory effects of garlic (*Allium sativum*). *Canadian Journal of Physiology and Pharmacology*.
- [10]. Chargui, I., Grissa, I., Bensassi, F., YahiaHrira, M., Haouem, S., Haouas, Z., Benheikh, H., (2012). Histopathological alterations in the liver and kidney of female rats exposed to low doses of Deltamethrin (DM): A molecular assessment: *Biomedical and Environmental Sciences*. 25(6).672-83.
- [11]. Adikwu, E & Deo, O. (2013). Hepatoprotective effect of Vitamin C (Ascorbic Acid). *Pharmacology & Pharmacy*. 4:84-92
- [12]. Mossa, A.T., heikal, T.M., Belaiba, M., Raoelison, E.G., Ferhourt, H., Bouajila, J. (2015). Antioxidant activity and hepatoprotective potential of *Cedrelopsis grevei* on Cypermethrin induced oxidative stress and liver damage in male mice. *BMC Complement Altern. Med*. 15: 251.
- [13]. Orlu, E.E. and U.U. Gabriel, 2011a. Effect of sublethal concentrations of aqueous extract of *Lepidagathis alopecuroides* on spermatogenesis in the fresh water catfish *Clarias gariepinus*. *Res. J. Environ. Toxicol.*, 5: 27-38.
- [14]. Orlu, E.E. and U.U. Gabriel, 2011b. Liver and plasma biochemical profile of male *Clarias gariepinus* (Burchell 1822) broodstock exposed to sublethal concentrations of aqueous leaf extracts of *Lepidagathis alopecuroides* (Vahl). *Am. J. Scient. Res. Issue*, 26: 106-115.
- [15]. Bergmeyer, H.U., M. Herder and R. Rej 1986a. International Federation of Clinical Chemistry (IFCC) Scientific Committee, Analytical Section: Approved recommendation (1985) on IFCC methods for the measurement of catalytical concentration of enzymes, Part 2. IFCC method for aspartate aminotransferase. *J. Clin. Chem. Clin. Biochem.*, 24: 497-510.
- [16]. Bergmeyer, H.U., M. Herder and R. Rej. 1986b. International Federation of Clinical Chemistry (IFCC) Scientific Committee, Analytical Section: Approved recommendation (1985) on IFCC methods for the measurement of catalytical concentration of enzyme, part 3. IFCC for alanine aminotransferase. *J. Clin. Chem. Clin. Biochem.*, 24: 481-495.
- [17]. McComb, R.B. and G.N. Bowers, 1972. Study of optimum buffer conditions for measuring alkaline phosphatase activity in human serum. *Clin. Chem.*, 18: 97-104.
- [18].
- [19]. Orlu, E.E., & Egbunike, G.N. (2009). Daily Sperm production of the Domestic fowl (*Gallus domesticus*) determined by quantitative Testicular histology and homogenate methods. *Pakistan Journal of Biological Sciences*, 12(20), 1359-1364
- [20]. Orlu, E.E. and Ogbalu, O.K. (2012). Litter Size, Sex ratio and some Liver Biomarkers in Sprague-Dawley Rats recovering from Exposure to Ethanol Extract of *Lepidagathis alopecuroides*. *Current Research Journal of Biological Sciences*, 4 (5), 643-648

Adetutuolubunmi Godwin-Obulor " Inhibitory Activity of Lycopene on Cypermethrin- Induced Hepatotoxicity and Liver Injury in Malesprague-Dawley Rats." *IOSR Journal of Pharmacy and Biological Sciences (IOSR-JPBS)* 13.1 (2018): 63-73.