

Ibopamine Eye Drops In Ophthalmology

Italo Giuffre' Md Phd

Department of Ophthalmology (Head: Prof. A. Caporossi), Catholic University, Rome, Italy, EU.

Abstract: *Ibopamine eyedrops are used in ophthalmology. This molecule is characterized by a dual mechanism of action, since it acts on both adrenergic and dopaminergic receptors. The adrenergic action is responsible for a marked mydriasis without accommodative paralysis, while the dopaminergic action promotes the production of aqueous humor. Given this dual action, ibopamine may be useful for diagnostic purposes in ophthalmology. This review article aims at presenting the most intriguing evidence on ibopamine and discusses the profile of patients who may be best suitable to this molecule.*

Key-words: *Glaucoma, ibopamine, provocative test, safety mydriasis.*

I. Introduction

Ibopamine eyedrops are used in ophthalmology since 1986 [1]. Ibopamine induces a marked mydriasis without accommodative paralysis and increases the production of aqueous humor: given this dual effect, ibopamine may be useful for diagnosis and therapy in multiple clinical pictures in ophthalmology [2]. This review article aims at presenting the most intriguing evidence on ibopamine and discusses the profile of patients who may be best suitable to this molecule.

Pharmacology of ibopamine

Ibopamine is a nonselective dopaminergic prodrug. Upon adsorption, it is rapidly transformed into the active metabolite epinine, a catecholamine with multiple agonist activity on DA 1, DA 2, alpha 1, alpha 2, beta 1 and beta 2 receptors (Figure 1) [3,4]. After entering the conjunctival sac through the cornea, ibopamine is hydrolyzed – with a half-life of about two minutes - into epinine by the esterases of the aqueous humor and ocular tissues [5,6].

In its active form, ibopamine stimulates the α -adrenergic and D1 dopaminergic receptors. The interaction with the α - adrenergic receptors of the dilating muscle of the pupil promotes the mydriatic effect of ibopamine [7]. Of note, since ibopamine has no effect on the ciliary muscle, the mydriasis is not associated with cycloplegia. The adrenergic stimulation can be antagonized by the administration of α -blockers such as timoxamine or dapiprazole.

On the other hand, the D1 dopaminergic activity increases the stimulation of aqueous humor production [7-9].

The administration of ibopamine 2%, i.e. the dose currently used in clinical practice, is not associated with any clinically-relevant local or systemic adverse effect: a single drop contains 1 mg of ibopamine, while the oral dose is >200 mg/day. This favorable toxicity profile may lend support to the use of ibopamine also in the pediatric setting. In particular, electrophysiological assessment showed that ibopamine is not retinotoxic, and the administration of this molecule is not associated with any change in laboratory parameters [9]. After local instillation, normal refraction is preserved [3,7].

II. Diagnostic Mydriasis

Ibopamine induces a potent mydriasis. In a study on 22 healthy volunteers, mydriasis induced by different dosages of ibopamine was superior to the mydriasis associated with tropicamide; no effect on accommodation or refraction was found with ibopamine, while a cycloplegic effect was constantly reported with tropicamide [10]. In another study on 15 patients with open-angle glaucoma and 15 healthy volunteers, 2% ibopamine induced a marked mydriatic effect, greater than those associated with 10% phenylephrine or 1% tropicamide, with no concomitant changes in refraction or visual acuity [11]. Noteworthy, ibopamine induced some biometric changes: the anterior chamber angle (ACA) showed a mean 5 degrees widening with an increase in scleral-iris angle (SIA) and sclera-ciliary process angle. In 37% of cases, separation of the pupil border and lens surface occurred, whereas contact was maintained only with the zonule in the remaining 63% of cases. These changes were quantitatively greater than those induced by 10% phenylephrine and 1% tropicamide, with this advantage likely due to the greater mydriatic effect of ibopamine [11].

The mydriatic effect of ibopamine lasts <1 hour, but it can be prolonged every 30 minutes by rechallenge and it can be reversed by the instillation of dapiprazole 0.5% [3]. In addition, the favorable toxicity profile of ibopamine compares well with those of other mydriatic agents such as phenylephrine and tropicamide, which might be sometimes associated with some adverse events such as contact dermatitis and with a temporary

reduction of visual acuity [12]. In more details, phenylephrine has been associated with blood pressure increase in premature newborns and elderly patients, as well as with other major cardiovascular events including syncope, myocardial infarction, tachycardia, arrhythmia, and fatal subarachnoid hemorrhage [13]. Based on this evidence, in Italy, phenylephrine at concentration >2.5% is not indicated in children <12 years [14].

Collectively these findings suggest the use of ibopamine to induce a safe and reversible mydriasis, in line with the landmark “safe mydriasis” principle by Mapstone [15]. In line of principle, the use of ibopamine in this setting can be extended also to the pediatric population, thanks to its excellent safety profile [16].

III. Pre-Surgical Mydriasis

In eye surgery – especially in cataract and in posterior segment surgery – pre-operative mydriasis has a crucial role in achieving best clinical outcome and safety. Some factors including change in pupillary diameter and stability should be given particular attention.

The stability of mydriasis depends upon a number of pre-existing factors. Among these, the so-called intraoperative floppy iris syndrome (IFIS), described for the first time by Chang et al in 2005 [17] and then observed in other studies [18-22]. Special concerns exist regarding the risk of IFIS development following cataract surgery in patients on the α -blocker tamsulosine (or with previous exposure to this molecule) or, although to a modest extent, risperidone and paliperidone [23-25]. A retrospective analysis, conducted in the USA, showed that 1254/4923 patients (25.5%) undergoing cataract surgery were in treatment with α -blockers; of them, 428 (8.7% of the total population) developed IFIS and 125 (2.5%) reported intra-operative complications. Noteworthy, 75.2% of patients have taken α -blockers before the intervention, thus confirming the correlation between α -blocker therapy and IFIS development.

Data on IFIS prophylaxis and treatment are scant. An interruption of tamsulosine therapy – or appropriate therapeutic switching – is recommended, but this approach is not supported by robust evidence given the irreversible antagonism of α 1-receptors exerted by this molecule [Tamsulosine SpC]. Local injection of adrenaline/atropine or specific surgical procedures potentially associated with further adverse events are recommended in cases of overt [19].

The efficacy and safety of ibopamine in this setting have been shown in different studies. Gelmi et al. reported a mean pupillary diameter of 9.1 mm with ibopamine, as compared with 8.6 mm with tropicamide [8,10]. These findings were corroborated in another study, in which ibopamine was superior over phenylephrine while showing a similar safety profile [8,26]. Of note, in another study conducted in pediatric patients, phenylephrine has been associated with hemodynamic complications [27]. Noteworthy, at the time of the drafting of this review no cases of IFIS have been reported in association with ibopamine. In addition, this molecule can have a role in the maintenance of mydriasis in eye surgery patients given its efficacy in promoting pupillary dilation also in poorly-pigmented iris or in patients with pseudoexfoliation syndrome.

Provocative test

It has been consistently shown that the instillation of ibopamine 2% results in a marked (up to 92%) increase of IOP in eyes with open-angle glaucoma, while no such effect is reported in healthy eyes [3,9,18,28, 29,30]. This dose-dependent effect reaches its peak within 45 minutes from the first instillation and lasts about 180 minutes, without any painful symptom or ocular discomfort [18]. Of note, this increase in IOP is not dependent upon the mydriatic effect of the drug, since it cannot be inhibited by the administration of α -blockers [4]. Conversely, the increase in IOP can be attributed to D1-dopaminergic activity [31]. In more details, the increase in aqueous humor induced by the action of ibopamine on dopaminergic receptors is compensated by a corresponding outflow in the healthy eye, but not in the glaucoma eye [32].

In a study on 20 open-angle glaucoma patients and 20 healthy subjects who were treated with ibopamine 2% eye drops and phenylephrine 10% eye drops, ibopamine was able to induce a significant increase in IOP only in glaucomatous eyes ($p<0.001$). No hypertensive effect was observed in normal eyes, and a similar mydriatic activity as that exerted by phenylephrine was shown (Figure 2) [8].

Given this peculiar effect, ibopamine has a role in the provocative test for glaucoma detection [9,29,30]. This test is performed by two consecutive administrations of ibopamine 2%, with a 5-minute interval. IOP is measured at baseline and 45 minutes after the first instillation: the test is considered positive if a ≥ 3 mmHg rise in IOP is reported [9].

The diagnostic performance of this test has been shown in different studies. In the analysis of 18 glaucoma suspects and 21 patients with glaucoma, ibopamine showed the potential to differentiate between them [29]. In fact, an increase of IOP of 1.9 ± 1.6 mmHg ($12.5\pm 10.3\%$) was observed for glaucoma suspects, whereas the corresponding figure for glaucoma patients was 7.4 ± 4.0 mmHg ($52.4\pm 26.5\%$; $p<0.0001$). Four glaucoma suspects (22%) and 19 glaucoma patients (90%) were tested as positive ($p<0.0001$).

In a recent study on 44 patients and 37 controls, early glaucoma was diagnosed in 26 patients, and the sensitivity and specificity of the ibopamine test to identify patients with early glaucoma were 78.7% and 71.6%,

respectively [30]. At multivariable analyses, subjects with a positive ibopamine test at baseline had an 8-fold higher risk of glaucoma compared with those with a negative test.

The main application for the provocative test is currently represented by pseudoexfoliation glaucoma [33]. On the other hand, in corticosteroid-associated glaucoma the frequency of test-positive patients rises with the increase of steroid potency [4]. In another study, conducted in 163 patients aged 8-40 years who were born from at least one glaucoma parent, ibopamine provocative test indicated that offspring of at least 1 parent with primary open-angle glaucoma - offspring without glaucomatous damages - shows an increase of IOP after ibopamine administration in 44.3% of patients [34]. This finding suggests the impaired function of outflow structures and, therefore, a predisposition to intraocular hypertension and possible glaucoma. However, a glaucoma patient with a positive ibopamine challenge will likely show a negative challenge result when re-challenged following trabeculectomy surgery, as suggested by a small study in 13 patients [35].

IV. Post-Surgical Hypotony

Ocular hypotony is a condition of low IOP (<6 mmHg) dependent upon impaired production or excretion of aqueous humor. It can ultimately lead to permanent blindness and excruciating bulbar pain [36]. This condition is secondary to metabolic alterations, loss of intraocular fluids, post-surgical or inflammatory blockade of aqueous humor synthesis. The incidence of this condition has increased after the introduction of antimetabolites for filtration surgery [37]. Therefore, interventions aimed at a rapid resolution of ocular hypotony are eagerly awaited.

At present, standard medical treatment of ocular hypotony is represented by mydriatic cycloplegic drugs or corticosteroids together with appropriate supportive procedures [38].

Given its marked effect on the increase of aqueous humor production by stimulating the D1 dopaminergic receptor [39], ibopamine can have a key role in the treatment of ocular hypotony in eyes with undamaged ciliary body.

In a preliminary study on 14 patients with ocular hypotony treated for 30-60 days with ibopamine 2% and corticosteroids following vitreoretinal surgical intervention, Virno et al. showed a significant increase in mean IOP versus baseline values, with IOP being increased in most patients (mean value +3.64 mmHg; $p=0.03$) [39]. One month after ibopamine-treatment discontinuation, mean IOP returned to pre-treatment values. Similar findings were reported in studies on patients with ocular hypotony associated with hypo-athalamia: the administration of ibopamine 2% eyedrops resulted in improved clinical outcomes compared with cycloplegic drugs and corticosteroids [40].

V. Conclusions

Ibopamine has both an α -adrenergic and a D1 dopaminergic action. This peculiar mechanism of action makes ibopamine able to induce a mydriatic effect without cycloplegia as well as an increase in the production of aqueous humor. Of note, these effects are not associated with the onset of serious adverse events or alterations of visual acuity, as shown by extensive clinical experience collected on this molecule. The duration of ibopamine action is short, with a peak at about 45 minutes since administration, and usually lasts no more six hours, thus comparing favorably with other molecules used in the ophthalmology setting (Table 1).

Given the above-mentioned characteristics, and beyond its established role in the provocative test, ibopamine may find a role in Ophthalmology, in almost all patients who do not need a cycloplegic effect. In particular, ibopamine can be particularly suitable in the induction of diagnostic mydriasis in some patients such as those who need an extensive mydriasis or must avoid cycloplegic effect. Moreover, the short duration of action of ibopamine and the favorable safety profile of this molecule can support its use in the induction of diagnostic mydriasis in patients at particular risk of adverse events or with angle closure. In the pre-surgical setting, ibopamine may be considered for patients with concomitant systemic conditions including cardiovascular disease, benign prostatic hyperplasia or diabetes, those with glaucoma, and subjects at risk of ocular hypotony of hypothalamia. In the future, it will be interesting to further explore the efficacy and safety of ibopamine in the above-mentioned indications. Such studies will help expand knowledge on the use of this dual-acting molecule in the ophthalmological setting.

References

- [1] Virno M, Taverniti L, Motolese E et al. : Ibopamina: nuovo midriatico non cicloplegico (nota preliminare). *Boll Ocul* 1986;65: 11.
- [2] McLaren JW, Herman DC, Brubaker RF, Nau CB, Wayman LL, Ciarniello MG, Rosignoli MT, Dionisio P: Effect of ibopamine on aqueous humor production in normotensive humans. *Invest Ophthalmol Vis Sci* 2003;44: 4853-4858.
- [3] Marchini G, Babighian S, Tosi R, Perfetti S & Bonomi L : Effects of 2% ibopamine on pupil, refraction, anterior segment anatomy and intraocular pressure. *J Ocul Pharmacol Ther* 2001;17: 215-223.
- [4] Virno M, Pecori Giraldi J, Taverniti L. et al: Ibopamine. D-1 dopaminergic agonist in the physiopathology of intraocular pressure. I.N.C.Editor, 2003, Rome (Italy).
- [5] Soldati L, Ganesello V, Galbiati I, Gazzaniga A & Virno M: Ocular pharmacokinetics and pharmacodynamics in rabbits of ibopamine, a new mydriatic agent. *Exp Eye Res* 1993; 56: 247-254.

- [6] Ugahary LC, Ganteris E, Veckeneer M, Cohen AC, Jansen J, Mulder PG & van Meurs JC: Topical ibopamine in the treatment of chronic ocular hypotony attributable to vitreoretinal surgery, uveitis, or penetrating trauma. *Am J Ophthalmol* 2006; 141: 571-573.
- [7] Giuffrè I : Ibopamine stimulates α -adrenergic receptors and D1-dopaminergic receptors in the eye. *Curr Drug Ther* 2007;2: 127-132.
- [8] Giuffrè I, Taverniti L, Di Staso S : The effects of 2% ibopamine eye drops on the intraocular pressure and pupil motility of patients with open- angle glaucoma. *Eur J Ophthalmol* 2004; 14: 508-513.
- [9] Giuffrè I, Falsini B, Gari MA & Balestrazzi E: Pattern electroretinogram assessment during ibopamine test in ocular hypertension. *Eur J Ophthalmol* 2013;23: 819-822.
- [10] Gelmi C, Palazzuolo A, Lucchetti M & Trimarchi F: Pupillographic evaluation of the mydriatic effect of ibopamine solution. *Int J Clin Pharmacol Ther Toxicol* 1989; 27: 346-351.
- [11] Marchini G, Babighian S, Tosi R, Perfetti S & Bonomi L: Comparative study of the effects of 2% ibopamine, 10% phenylephrine, and 1% tropicamide on the anterior segment. *Invest Ophthalmol Vis Sci* 2003;44: 281-289.
- [12] Haroun-Díaz E, Ruíz-García M, De Luxán de la Lastra S, Pastor-Vargas C, De las Heras M, Sastre Domínguez J & Cuesta-Herranz J : Contact dermatitis to both tropicamide and phenylephrine eye drops. *Dermatitis* 2014;25: 149-150.
- [13] Shiuey Y, Eisenberg MJ: Cardiovascular effects of commonly used ophthalmic medications. *Clin Cardiol* 1996;19: 5-8.
- [14] Nota Informativa Importante sui medicinali a base di fenilefrina a uso oftalmico (29/07/2008): <http://www.agenziafarmaco.gov.it/content/nota-informativa-importante-sui-medicinali-base-di-fenilefrina-uso-oftalmico-29072008>. Last accessed: 28th February 2016.
- [15] Mapstone R : Safe mydriasis. *Br J Ophthalmol* 1970; 54: 690-692.
- [16] Virno M, Pecori Giraldi J, Taverniti L, De Gregorio F & Sedran L: L'ibopamina in oftalmologia. I.N.C. Editor, 1998, Rome (Italy).
- [17] Chang DF & Campbell JR: Intraoperative floppy iris syndrome associated with tamsulosin. *J Cataract Refract Surg* 2005;31: 664-673.
- [18] Virno M, Pecori Giraldi J, Taverniti L, et al : Effetti ipertensivi oculari dell'ibopamina somministrata per via locale in soggetti con turbe idrodinamiche endoculari (nuovo test di provocazione). *Boll Ocul* 1987;66: 5.
- [19] Chang DF, Braga-Mele R, Mamalis N, Masket S, Miller KM, Nichamin LD, Packard RB & Packer M; ASCRS Cataract Clinical Committee: Clinical experience with intraoperative floppy-iris syndrome. Results of the 2008 ASCRS member survey. *J Cataract Refract Surg* 2008a;34: 1201-1209.
- [20] Chang DF: Use of Malyugin pupil expansion device for intraoperative floppy-iris syndrome: results in 30 consecutive cases. *J Cataract Refract Surg* 2008b;34: 835-841.
- [21] Chang DF, Campbell JR, Colin J & Schweitzer C; Study Surgeon Group: Prospective masked comparison of intraoperative floppy iris syndrome severity with tamsulosin versus alfuzosin. *Ophthalmology* 2014;121: 829-834.
- [22] Yuksel N, Ozer MD, Takmaz T, Ozen U, Metin M & Akcay E: Anterior segment morphologic changes related to α -1 adrenergic receptor antagonists use. *Eur J Ophthalmol* 2015; 25: 512-515.
- [23] Agenzia Italiana del Farmaco (AIFA). Nota Informativa Importante 11/08/2006: Importanti informazioni su "Intraoperative Floppy Iris Syndrome (IFIS)" o "sindrome dell'iride a bandiera" e tamsulosin. Available at: http://www.agenziafarmaco.gov.it/sites/default/files/111_50221.1158913800728c36b.pdf. Last accessed 28th February 2016.
- [24] Zaman F, Bach C, Junaid I, Papatosis AG, Pati J, Masood J & Buchholz N (2012): The floppy iris syndrome - what urologists and ophthalmologists need to know. *Curr Urol* 2012; 6: 1-7.
- [25] Zygoura V, Kopsachilis N & Carifi G : Intraoperative floppy iris and prevalence of intraoperative complications: results from ophthalmic surgery outcomes database. *Am J Ophthalmol* 2014;158: 846-847.
- [26] Corbett MC, Buckley SA & Richards AB: Ibopamine: a new preoperative mydriatic for cataract surgery. *Eur J Ophthalmol* 1994; 4: 29-34.
- [27] Sbaraglia F, Mores N, Garra R, Giuratrabocchetta G, Lepore D, Molle F, Savino G, Piastra M, Pulitano' S, Sammartino M: Phenylephrine eye drops in pediatric patients undergoing ophthalmic surgery: incidence, presentation, and management of complications during general anesthesia. *Paediatr Anaesth* 2014;24: 400-405.
- [28] Boles Carenini B, Brogliatti B, Boles Carenini A, et al : Ibopamine: a new drug and its use as provocative test for the diagnosis of glaucoma. *New Trends Ophthalmol* 1992;7: 3.
- [29] Ullrich K, Craig JE & Landers J : Ibopamine challenge test can be used to differentiate glaucoma suspects from glaucoma patients. *Clin Experiment Ophthalmol* 2014; 42: 342-346.
- [30] Dominguez-Duenas F, Plaza-Espinosa L, Mundo-Fernandez EE, Jimenez-Reynoso CA, Barojas-Weber E & Barrientos-Gutierrez T: Early glaucoma screening using the ibopamine provocative test. *J Glaucoma*, 2016 May ; 25 (5): e441-445.
- [31] Virno M, Pecori Giraldi J, Taverniti L, De Gregorio F & Sedran L: L'ibopamina in oftalmologia. I.N.C. Editor, 1998, Rome (Italy).
- [32] Virno M, Gazzaniga A, Taverniti L et al : Dopamine, dopaminergic drugs and ocular hypertension. *Intern Ophthalmol* 1992; 16: 349-353.
- [33] Scuderi GL, Regine F, Perdicchi A, Turtoro A & Contestabile MT: Efficacy of 2% ibopamine on the dilation of patients with pseudoexfoliation syndrome. *Eur J Ophthalmol* 2010;20: 120-123.
- [34] Virno M, Sampaolesi R, Pecori Giraldi J, De Gregorio F, Taloni M, Brusini P, Di Staso S & Stecchi G : Ibopamine: D1-dopaminergic agonist in the diagnosis of glaucoma. *J Glaucoma* 2013;22: 5-9.
- [35] Landers J, Ulrich K & Craig JE : Ibopamine challenge testing becomes negative following successful trabeculectomy surgery. *Clin Experiment Ophthalmol*, 2016 Apr.; 44(3): 166-169.
- [36] Fine HF, Biscette O, Chang S & Schiff WM : Ocular hypotony: a review. *Comp Ophthalmol Update* 2007; 8: 29-37.
- [37] Rahman A, Mendonca M, Simmons RB & Simmons RJ : Hypotony after glaucoma filtration surgery. *Int Ophthalmol Clin* 2000;40: 127-136.
- [38] Blok MDV, Kok JHC, Van Mil C, Greve EL & Kijlstra A : Use of the megasoft bandage lens for treatment of complications after trabeculectomy. *Am J Ophthalmol* 1990; 110: 264-268.
- [39] Virno M, De Gregorio F, Pannarale L & Arrico L : Topical ibopamine and corticosteroids in the treatment of post-surgery ocular hypotony. *Int Ophthalmol* 1997;20: 147-150.
- [40] Di Giulio S, De Stefano B, and Boccassini B & Boccassini G: Post-trabeculectomy hypotension and hypoathalamia: efficacy of treatment with ibopamine eyedrops. *Acta Ophthalmol Scand Suppl* 2000; 232: 65-66.

Table 1. Peak and through times of the most important and widespread used mydriatic drugs in ophthalmology.

DRUG	PEAK	THROUGH
Atropine	1-2 H	10-15 D
Omatropine	1 H	6-48 H
Cyclopentolate	30 M	12 H
Tropicamide	20 M	6 H
Ibopamine	45 M	6 H

Legenda: D: day; H: hour; M: minute.

Figures

Figure 1. Chemical formulas of dopamine, epinine and ibopamine.

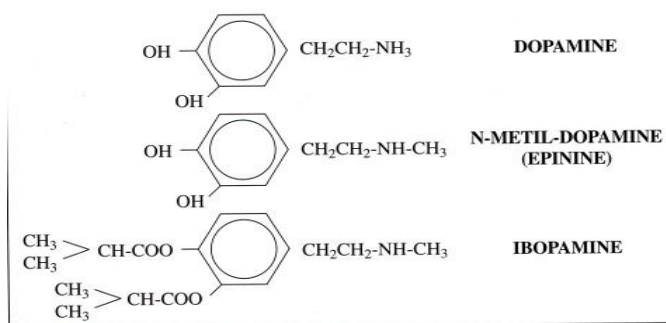


Figure 2. The effect of 2% ibopamine and 10% phenylephrine eye drops on IOP (Panel A) and mydriasis (Panel B) in glaucomatous patients compared with healthy volunteers [Giuffrè et al. 2004].

