

## Effect of Sub-Lethal Dose of Venom of *A.Mellifera* on Kidney of Rabbit

Neeta Lal&Abhijit Dutta

University Dept. of Zoology,Ranchi University,Ranchi -834008

---

**Abstract:** Honey bees are the best friends of human beings and are of immense importance to them, yet on the other hand the venom injected by them induces a number of histo-pathological changes in some of the vital organs like kidney, liver, lungs, and cardiac muscles and is responsible for large scale mortality and morbidity of men worldwide. Sub-lethal doses of lyophilized venom of *A.mellifera* (1ml of distilled water, DW contain 0.5 mg of venom) were administered intra-peritoneally in rabbits for a period of 28 days (every alternate day). After the last day of venom administration, the animals were sacrificed and kidneys were removed and processed for histological changes. Drastic histopathological alterations were observed in various aspects of Kidney both in routine and scanning electron microscopy.

**Keywords:** Bee Venom, Rabbit, kidney

---

### I. Introduction

Insect stings are commonly encountered worldwide and produce a number of pathological manifestations. Hymenopterans have venom glands containing several chemicals which are stored in their reservoirs. The study of social hymenopterans (bees, wasps, and ants) venom proteins is of great interest, since these venom trigger serious allergic reactions in humans. Most of these proteins are enzymes, specific toxins or other bioactive molecules [1]. Both toxic (local) or allergenic reactions are produced by venom secreted from such glands. Toxic or local effects are caused mostly by low molecular weight compounds resulting in pain, local inflammation, itching, irritation, etc. Mellitin, a predominant component of venom, has been reported to be the main reason for the effects. Most of the serious reactions in the victims stung by Hymenoptera are allergenic resulting in a cascade of reactions, which are mediated by other components like histamine, leucotrienes enzymes, peptides etc., and fall under late phase reactions [2]. To small victims even one sting may prove fatal and can provoke myotoxic reactions. Stings for mammals have been not only reported to be merely an unpleasant experience rather it causes severe allergic reactions producing abnormalities in various organs of the body [3,4]. The present investigation was carried out to find the effect of long term injection of sub-lethal doses of venom of *A. mellifera* on Kidney of the test animal, rabbit.

### II. Material & Methods

Lyophilized venom of *A.mellifera* was purchased from Sigma Aldrich, Kolkata (Catalogue No. V-3125) and was diluted in distilled water (DW) to get the desired concentrations and was stored at 4°C in freezer for further use.

#### 2.1 Procurement of test animal:

10 rabbits (both male and female) without any sex discrimination were purchased from the Animal Production Department, Veterinary College, Ranchi. A group of 5 rabbits was kept under control condition and another group of rabbits was kept for the conduction of the experiment.

#### 2.2 Venom administration:

Rabbits were administered intramuscular venom (0.5 mg venom in 1 ml of DW) of *A. mellifera* for a period of 28 days every third day. LC<sub>50</sub> value of *A.mellifera* venom had already been reported to be 2-4 mg in rabbit, hence a sub-lethal dose was fixed and chosen for this experiment, that showed significant pathological changes [5].

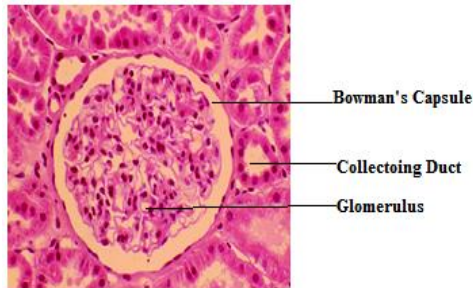
#### 2.3 Tissue processing:

The test animals were sacrificed on 29<sup>th</sup> day and the kidneys were dissected out. Kidneys were immersed in Bouin's fixative for 1 day for histological slide preparation. Thin slices of tissues were kept at 0.9 % NaCl for SEM processing after dissection.

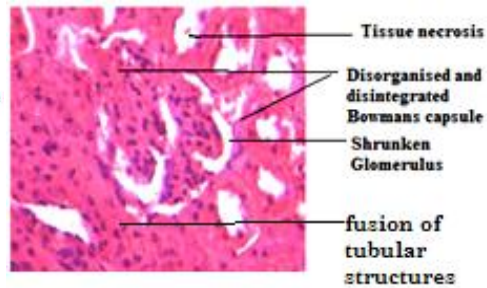
For histological studies, tissues were first washed in a graded series of alcohol and the routine paraffin tissue blocks were prepared. Thin sections of kidney tissue were stained by Eosin-Haematoxyline for predicting the changes, if any. While for SEM study, the tissues were fixed using double fixatives, Glutaraldehyde being the

primary fixative for fixation of glycogen, while Osmium Tetraoxide being the secondary, which fixes lipids. The tissues were washed with Sodium Cacodylate Buffer, then in graded alcohol series, and were carried in a ratio of 1:3 (alcohol: amyl acetate). The SEM investigations were carried out at Burdwan University.

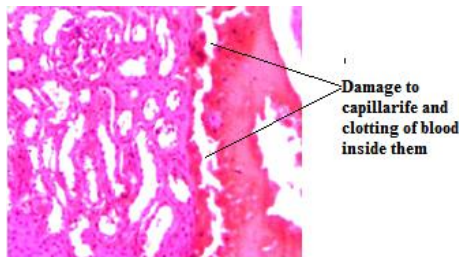
### III. Results



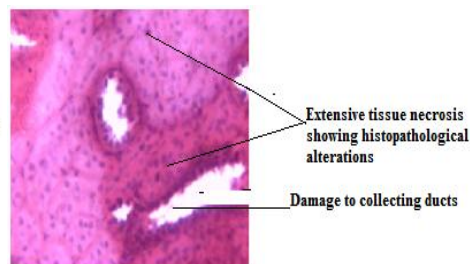**Fig-1** T.S of control Kidney



**Fig-2** T.S of treated Kidney

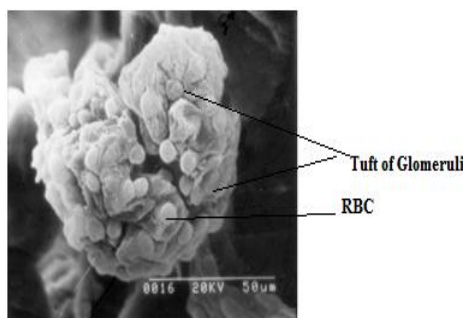


**Fig-3** T.S of treated Kidney

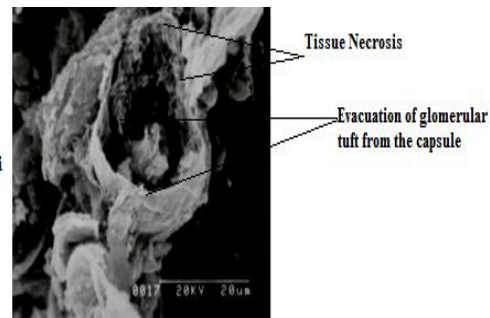


**Fig-4** T.S of treated Kidney

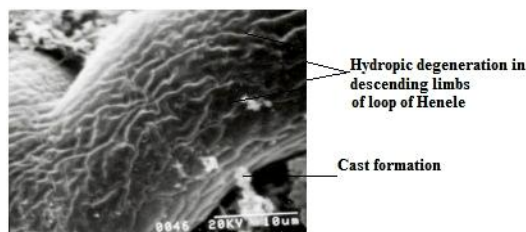
Treated sections of the kidney showed marked Histopathological alterations. Several changes deviating from normal structure were observed, including fusion of tubular structures, extensive damage to capsular wall, shrunken glomeruli, evacuation of glomerular contents, (FIGURE-2) degeneration of capillaries, and clotting of blood inside the capillaries (FIGURE-3) and damage and fusion of the collecting ducts was also seen (fig.4) in contrast to the well defined glomeruli, with intact Bowman's capsule in case of control kidney (FIGURE-1).



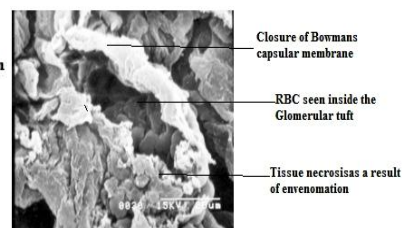
**Fig-5** SEM of glomerulus of Control animal



**Fig-6** SEM of Bowman's Capsule devoid of glomerulus



**Fig-7** SEM of descending limb of envenomated animal



**Fig-8** SEM of glomerulus of treated animal

SEM studies also revealed disruption and distortion of glomerular wall, tissue necrosis, swelling of proximal convoluted tubules, cast formation hydropic degeneration of limbs (FIGURE. 7), and closure of capsular wall (FIGURE8). Loosening of glomeruli from the Bowman's capsule, damaged and broken ducts along with disruption of capsular wall were some additional pathological changes observed (FIGURE 6 and 8)

#### IV. Discussion

Vacuolization and ejection of glomeruli from the Bowman's capsule, granuloalaline degeneration, necrosis of the kidney cells, fusion of the renal cells have been found in the present investigation and can be seen in FIGURE – 3, 4, and 8. Such alterations have also been reported due to snake envenomation in mammals[6].Haemorrhage, clotting of blood in the renal cells, vascular nephritis, and degeneration of capillary tuft, fatty degeneration of renal tubules, microvacuolar degenerations, and necrotic lesions were also noticed. All these pathological manifestations are due to presence of neurotoxins and hemolysins in the venom, as has been observed in the present investigation.

Renal failure by bee venom may thus also be related to a malfunctioning of renal transporters according to Ho Jae (2006) thus substantiating the present findings. Inhibition of the synthesis of the methyl –D- glucopyranoside by melittin and apamine found in the bee venom of *A.mellifera* acts on the apical transport activity of renal tubule cells. Inhibition of the synthesis of the methyl-D- glucopyranoside by melittin ,which is one of the important enzymes involved in renal filtration, is impaired by apamine (Ho Jae,2006) substantiates the present findings.In a study on female Wistar rats, weighing about 150 – 200 gm, injected with bee venom at a dose of 0.4 micro L/100gm, ATN (acute tubular necrosis) was found to be a frequent complication.

Envenomated rabbits showed necrosis in cortex and outer medullary region with cast formation and renal alteration under SEM. The proximal tubule segments showed an increase in intracytoplasmic vacuoles, attenuation of the brush border cells, and basolateral infoldings[4]. Thick ascending limbs of Henle's loop showed hydropic degeneration. Apoptosis or necrosis due to cellular integration too was also observed and are clearly visible FIGURE6,7,8.

ATN (acute tubular necrosis) was the most common and important histological findings in case of acute renal failure induced by wasp sting[7], as has also been noticed in the present investigation. The pathogenesis of ATN are mediated partially by pigment nephropathy caused by precipitation of myoglobin and haemoglobin casts in the renal tubule.

Acute renal failure is also believed to be dueto nephrotoxic effects of hymenoptera venoms [10]. Dead cells with apoptosis or necrosis due to cellular disintegration resulted in the membrane denudation. Intracytoplasmic necrosis have also been reported to be found as a result of interactive effects of venom components ,mainly melittin, and enzymes like phospholipases,both acting on biological membranes[4].

The present investigation, thus, clearly reveals that acute renal failure in man is likely to be due to active components like apamine which are present in the bee venom [8,9]. Clinical evidences also support that some bee venom toxins may directly damage renal tubules.

#### References

- [1]. Hoffman, DR., Wood, DL., Hudson, P. Demonstration of IgE and IgG antibodies against venoms in the blood of victims of fatal anaphylaxis. *J. Allergy Clin. Immunol.*, 1983, 73, 193-6.
- [2]. Golden DBK, Valentine MD: Insect sting allergy. In: Franklin EC, ed. Clinical immunology update. Edinburgh: Churchill Livingstone 1989; 169-96
- [3]. Dotimas EM., Hider, RC Honey bee venom. *Bee world*, 1987, 68, 51 – 71
- [4]. Nabil, ZI., Hussein, AA., Zalat, SM., Rakha, MK, Mechanism of action of honey bee (*Apis mellifera*) venom on different types of muscles. *Hum. Exp. Toxicology.*, 1998, 7, 185 – 190.
- [5]. Schumacher MJ, Schmidt JO, Egen NB, Lowry JE (1990). Quantity, analysis, and lethality of European and Africanized honey bee venoms. *Am. J. Trop. Med. Hyg.*, 43(1): 79-86
- [6]. Mitchell, S.W., and Reichert, E.T. (1886) Smithsonian Contribution to know (i) 26, 647 (Cited by Noguchi) Mitchell, S.W., and Reichert, E.T. (1886) Smithsonian Contribution to know (i) 26, 647 (Cited by Noguchi) Fidler, H.K., Glasgow, R.D., and Carmichael E.B. (1940). *Am. J. Pathol.* 16, 355 – 364.
- [7]. Thiruvethiran, T.; Goh, B.L.; Leong, C.L. *et al.* -Acute renal failure following multiple wasp stings. *Nephrol. Dial. Transplant.*, 14: 214-217, 1999.
- [8]. Hommel, D.; Bollandard, F. & Hulin, A. - Multiple African honeybee stings and acute renal failure. *Nephron*, 78: 235-236, 1998.
- [9]. Humlet, Y.; Sonnet, J. & Van Ypersele De Strihou, C. - Bee stings and acute tubular necrosis. *Nephron*, 31: 187-188, 1982.
- [10]. Franca, FOS.; Benvenuti, LA.; Fan, HW. *et al.* - Severe and fatal mass attacks by “killer” bees (Africanized honey bees *Apis mellifera scutellata*) in Brazil: clinicopathological studies with measurement of serum venom concentrations. *Quart.Fonesca, F.* (1949) “Animais Pe conhentos,” Instituto Butantan, Sao Paulo.

**Acknowledgement:**We acknowledge the help extended to us by Dr. Srikanta Chakraborty of Burdwan University in Scanning Electron Microscopy of different tissues.