

Certain Aspects Of Teratological Effects Of Retinoids On Skin Of Swiss Albino Mice.

Dr Rashmi Sharma¹, Ashok Gupta²

Department of Zoology SPC GCA AJMER M.D.S.U. Ajmer Rajasthan INDIA

Abstract: Teratology is a branch of Embryology that deals with abnormal development. The development of an organism is a complex process of embryogenesis involved cell proliferation, differentiation, migration and organogenesis. Many agents interfering the development process can cause malformations in the embryo. The study of these congenital abnormalities is called teratology and agents which are responsible for causing these malformations are called teratogens. Susceptibility to teratogens depends on the genotype of the organism, including species as well as strain differences. Etienne Geoffrey Saint Hilaire and his son in 1820 started experiments on chick embryo by disturbing its environment in different ways at different embryonic stages. They found some anomalies like Trioncephally, atrophy of eyes and spina bifida in his experiments (Tuli, 1968). In 1877 Dareste reported found some anomalies like Trioncephally, atrophy of eyes and spina bifida in his Experiments (Tuli, 1968). Retinoids are essential for spermatogenesis oogenesis, placental development, foetal morphogenesis and growth. The role of vitamin A in vision is well known. Active derivative of vitamin A (Retinoids) play an important and multiple role in Mammalian development and homeostasis (Sapin, et.al. 1997, Dup et al 1997). These essential dietary compounds are needed in very small quantities, they are not synthesized by the animals and are obtained from external sources in the form of *b* carotene (C₄₀H₅₆). In cells of intestine *b* carotene is converted into vitamin alcohol and is transported by blood to liver where it is esterified and stored as vitamin A palmitate. RA is not stored in liver but is derived from retinal and it is biologically the most potent form of vitamin A. Vitamins are organic compounds which are divided into 2 categories i Fat soluble (A,D,E,K) and ii water soluble (B and C). Vitamin A belongs to fat soluble category of vitamins. A fat soluble substance essential for life was first discovered in egg yolk in 1909 by Stepp (Pawson, 1981; Robert and Sporn, 1984). It was confirmed by Mc Collum Devis in 1913 when he found a compound with similar biological activity in butter fats, egg yolk and cod liver oil and was named fat soluble vitamin A. In the present study effects of different doses on skin on different development stages of swiss albino mice are studied.

Key Words: Retinoids, Teratological, Swiss albino mice, Skin.

I. Introduction

Teratology is a branch of Embryology that deals with abnormal development. The development of an organism is a complex process of embryogenesis involved cell proliferation, differentiation, migration and organogenesis. Many agents interfering the development process can cause malformations in the embryo. The study of these congenital abnormalities is called teratology and agents which are responsible for causing these malformations are called teratogens. Susceptibility to teratogens depends on the genotype of the organism, including species as well as strain differences. Teratological experiments were started from 1820s with the studies of Etienne Geoffrey Saint Hilaire and his son on chick embryo by disturbing its environment in different ways at different embryonic stages. They found some anomalies like Trioncephally, atrophy of eyes and spina bifida in his Experiments (Tuli, 1968). In 1877 Dareste reported some congenital malformation in the chick embryo by environmental disturbance. Retinoids are essential for spermatogenesis oogenesis, placental development, foetal morphogenesis and growth. The role of vitamin A in vision is well known. Active derivative of vitamin A (Retinoids) play an important and multiple role in Mammalian development and homeostasis (Sapin, et.al. 1997, Dup et al 1997). These essential dietary compounds are needed in very small quantities, they are not synthesized by the animals and are obtained from external sources in the form of *b* carotene (C₄₀H₅₆). In cells of intestine *b* carotene is converted into vitamin alcohol and is transported by blood to liver where it is esterified and stored as vitamin A palmitate. RA is not stored in liver but is derived from retinal and it is biologically the most potent form of vitamin A. Vitamins are organic compounds which are divided into 2 categories i Fat soluble

(A,D,E,K)and ii water soluble (B and C).Vitamin A belongs to fat soluble category of vitamins. A fat soluble substance essential for life was first discovered in egg yolk in 1909 by Stepp (Pawson, 1981; Robert and Sporn, 1984). It was confirmed by Mc Collum Devis in 1913 when he found a compound with similar biological activity in butter fats, egg yolk and cod liver oil and was named fat soluble vitamin A. The name of vitamin was given by Dummmond In 1920. The natural and synthetically obtained vitamin A is found in several forms of alcohol (Retinol), aldehyde (Retinol palmitate), acetate and retinoic acid. They were collectively known as retinoids. Retinol or alcoholic form of vitamin A is a unstable organic compound. They are easily oxidized specially in the presence of heat. The ester form of vitamin A are fairly stable. When vitamin A is taken in the form of esters (Palmitate/acetate), its converted into Alcoholic form(Retinol) in the intestinal cells to be carried to liver, where it is converted to palmitate form for storage. Retinoic acid is not stored in the liver but it is derived from retinol and it is biologically most potent form.

II. Materials and Methods

The mice were obtained from mice breeding center, Department of Zoology M.D.S.U. Ajmer. Animals were fed synthetic diet mice feed pellets (Brook Bond Lipton India Ltd.)Supplemented with germinated grains, seasonal green vegetables, multivitamin drops and water ad libitum. Tetracycline mixed in water in water was regularly given. There are four virgin female mice 25+-1gm were caged with fertile healthy male in the evening and these were examined for presence of vaginal plug, the next morning. The day appearance of vaginal plug was considered as day 0 of pregnancy.

The Vaginal Plug

After copulation a secretion of seminal vesicles in the ejaculate of the male coagulate to form a plug in the vagina extending from the cervix to the valve, where it is ordinarily Visible and is a convenient external sign that mating has occurred (Green, 1996).

Duration Of Pregnancy

The gestation period in this species is 19 days and occasionally 20 days. The youngs are most frequently born in the early hours of the morning between midnight and 4 AM.

III. Objectives

Investigation of the effects of retinoic acid on different developmental stages (5th, 8th, 11th, and 14th) of mouse embryo. To study effects of RA on organogenesis of skin, liver, heart .Effect of RA on skeletal elements.

Experimental Design

The pregnant females were divided into following groups :(6 animals per group) Group A : untreated Group B : Treated

Doses

Suitable (non lethal or sublethal) doses of RA were screened on mice embryos on different stages of developments. The following doses were found to produce various teratological defects on developing mice embryos. 1. 2mg RA /pregnant female. 2. 4 mg RA /pregnant female. Observations and results

IV. Results and Discussion

Effect of RA on skin

Skin forms external covering of the body parts. It is formed by regulated interaction of ectoderm and mesoderm. It is made up of epidermis and dermis .There are many other structure present in the skin such as pigment, skin gland, hair etc. Epidermis i have three distinct layers stratum corneum, stratum granulosum, stratum germinativum(inner layer). Stratum germinativum is also called as basal layer. Stratum germinativum or basal layer is highly proliferative and give rise to stratified shape other layers. The skin of neonet mouse has hair follicle but sweat glands and sebaceous glands are absent in newly born mouse.

Development of Hair Follicle

Hair follicle is a result of multiplication of innermost layer of epidermis and inward inversion of mesodermal cells in the dermis. Normally up to 14th day of gestation there is not much accumulation of prospective hair follicle cells in the dermis. However 14th day of gestation such accumulation of early hair follicle can be seen in the dermis. The Proliferation of follicle cells continued upto 17th day of gestation. Subsequent development result in formation of inner and outer hair sheath, hair cone, hair bulb and hair papilla. In the newly born neonet hair bulb and elongated hair follicle are quite distinct. Hair follicle consist of outer hair follicle sheath and inner hair follicle sheath. The cells of outer hair follicle sheath are elongated. Where as cells of inner hair follicle sheath are rounded. A well formed hair bulb is also present at the base of the hair follicle. Connective tissue and fiber are found in the dermal region.

2 Mg RA On 5th Day Gestation

Treatment of RA (2mg/pregnant female) were not influenced at early stage of development Mice embryo skin.

2mg RA on 8th Day Gestation

Treatment of pregnant female with 2mg RA on 8th day gestation does not inhibit formation of hair follicle. Adequate number of hair follicles are visible in dermis, hair bulbs are also distinguished. Hair cone formation is not documented, cells with more than 2 nuclei and bigger size are present at the site of accumulation of hair follicle. Dermis having loosely arranged connective tissue without any skin glands.

2mg RA 11th Day Gestation

Shows changes in structural organization of skin. In external appearance skin shows folding. Although the folds are not prominent. The epidermal layers stratum corneum, stratum granulosum and stratum germinativum normally arranged. Hair follicles cells are loosely arranged. At some places hair follicles are abnormally elongated. The cells from hair follicle shows 2-3 prominent nuclei. Development of some hair follicles inhibited indicating delayed dev of hair follicles by RA treatment.

2mg RA on 14 Day Gestation

It causes severe folding of skin. Epidermis is having 3 layers, but there is high level of cornification in outermost layer. Follicles are not present in adequate number in some part of skin, hair follicles are completely absent. Dermis is quite thick having darkly stained nuclei. Dermal glands are absent.

4mg RA on 5th Day Gestation

On 5th day gestation when 4 mg RA was given to pregnant female observed that newly born mice embryo skin was almost similar to untreated control.

4mg RA on 8th Day Gestation

4mg RA treatment to pregnant female on 8th day gestation period shows quite normal organization of the epidermis. Follicles are not prominent and there is accumulation of follicle cells on certain places in the dermis. Most of the hair follicles shows hair but hair cone is absent. At certain places follicle cells are loosely arranged. Bulb of hair follicles are also in an early stage of development. Dermis is quite thick without dermal glands.

4mg RA on 11th Day Gestation

Results in disorganization of skin architecture folds are very prominent and they appear like invagination of skin. Epidermal organization is also disrupted in these cases. The middle and upper layer generally appear on cellular whereas basal layer appears with loosely arranged cells. Follicles are present in most part of the skin they look like loosely arranged patches of cells. Hair bulb is not distinct in such cases.

4 Mg RA On 14 Day Gestation

Morphological picture of the neonet shows disruption of skin at several places of the body. The folds of skin look like over hanging skin flaps. The epidermis does not show three

distinct layer of cells. It consist of loosly arranged connective tissue fibers with occasionally hair follicles. In most hair follicles are absent, skin glands are not developed in these cases.



Image 1 Histological picture of skin of newly born mice treated with 4mg RA per pregnant female at 14th day gestation showing disrupted outer layer and inhibited hair follicle.

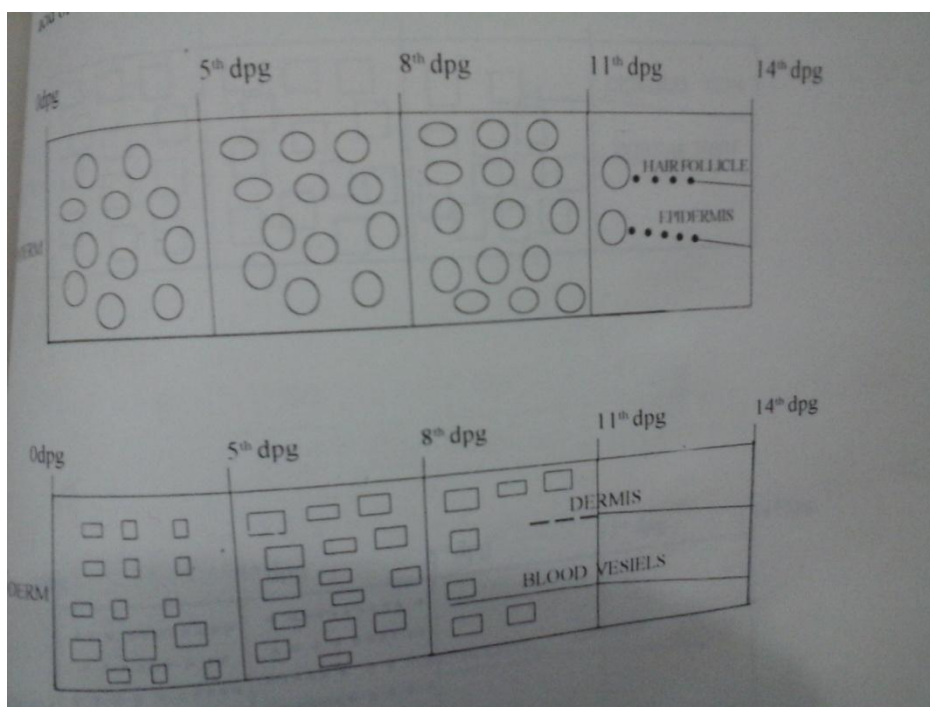


Image 2 Diagramatic representation of sensitive periods of organogenesis to RA on skin. Upper ectoderm
Lower mesoderm

V. Conclusion and Summary

Deficiency or excesscity of vitamin A (RA) produce teratogenic effects on the epithelial tissue. Retinoids can modulate differentiation in several cell types both in vitro and in vivo and are necessary for proper differentiation and maintenance of most epithelial tissues (Wolbach and Howe, 1925, Evans, 1988, Fell and Renaldini, 1965, Johnson and Scadding).The animals treated with 2mg/4mg RA on 5th, 8th, 11th, 14th day gestation showed variety defects on the developing skin. The most sensitive period observed related to alteration of skin morphogenesis was 14th day geststion stage. The skin of 5th day treated cases found to be almost similar to the untreated

control cases. This indicate the process of skin differentiation does not start on 5th day old embryos. The most common effect caused by RA on skin include disruption of epidermis , discontinuity in the basement membrane, interruption in the formation of hair follicle, folding of skin etc. The skin of 14th day treated cases did not show distinct metaplasia. Complete suppression of keratinization of epidermis and its transformation to ciliated type was observed by Sweeny and Hardy(1976).

Oral RA treatment to pregnant female on 14th day gestation interfered with differentiation of hair follicle hair sheath and bulb are interrupted by connective tissue and looks separate structure but granular transformation of hair follicle was not observed in any of treated cases.

Effects of R A on skin was not only stage dependent but dose dependent also. The vitamin A induce mucous metaplasia is dependent on doses of RA. Higher doses of RA induced rapid response than lower doses of RA.

References

- [1]. Coblan ,S.Q.(1953):Excessive intake of Vit A as a cause of congenital anomalies in Rat. *Science* 117:535-536.
- [2]. Coblan ,S.Q. (1954):Congenital anomalies in rat produced by excessive intake of vit A during pregnancy. *Pediatrics*. 13 556-557.
- [3]. Dickman ,E.D. and Smith, S.M. (1996) Selective regulation of cardiomyocyte expression and cardiac morphogenesis by RA *dev dynamics* 206(1):39-48.
- [4]. Effendy. I., (1996): Differential irritant skin responses to topical RA and sodium lauryl sulphate alone and in crossover design *British J. of Dermatology* 134: 420-430. (Abstract).
- [5]. Elmzar, M.M.A.(1996). Pattern of Retinoid induced teratogenic effect. Possible relationship with relative selectivity for nuclear retinoid receptors RAR-alpha,RAR-beta and RAR gama. *Teratology* 53(3):158-167.(Abstract).
- [6]. Fisher, G.J. and Voiegwwa, J.J. (1996): molecular mechanisms of retinoid actions in skin, *FASEB J.*10(9).1002-1013.
- [7]. Giroud, R. and Martinet,(1954): Fertes du Polasis chezl embryos de rat per hypervitaminose A., *Comp.Rend.Soc.Biol.*148:1742-1743.
- [8]. Goodman, A.B. (1996) : Congenital anomalis in relative of Schizophrenic probands may indicate a retinoid pathology. *Schizophrenia Research* 19: 2-3:169-170.(Abstract).
- [9]. Griffiths. C. E. M. (1996): Tropical RA changes the epidermal cell surface glycosylation pattern towards that of a mucosa epithelium. *British Journal of Dermatology*. 134; 431-436.
- [10]. Leelaprute. L. ; Boonpucknaving. V.; Bharmar apratuati. N., and Weerapradist. W.(1973). Hypervitaminosis A in rat *Arch. Sci* 85:42-55.
- [11]. Kalter, H.C.(1960): The teratogenic effect of hypervitaminosis upon the face and mice of inbred mice. *Ana.N.Y. Acad. Sci.*85:42-55.
- [12]. Kalter, H.C. and Warkany J. (1961): Experimental production of congenital malformation In strains of inbred mice by maternal treatment with hypervitaminosis. *Amer J. path*,381-21.
- [13]. Kochhar, D.M. (1967): Teratogenic activity of Retinoic Acid. *Acta Pathol Micro. Biol. Scand*.
- [14]. 70:398-404.
- [15]. Moore, T. (1957) : “ Vitamin A “ *Am. Elsevier*, New Delhi. Niazi, I.A. : Pescitelli M.J.; and Stocum, D.L., (1985) ; Stage dependent effects of RA on regenerating urodele limbs.