

## A Case Report on - A Rare Case of Laryngocele in a Young Male Men

Dr. Shamendra Kumar Meena<sup>1</sup>, Dr. Rajkumar Jain<sup>2</sup>, Dr. Vijay Kumar Meena<sup>3</sup>,  
Dr. Ramraj Meena<sup>4</sup>, Dr. Muniram Meena<sup>5</sup>,

---

**Abstract:** Laryngocele is a cystic dilatation of the laryngeal saccule. The saccule presents as a diverticulum from the anterior end of the ventricle and extends upwards between the vestibular fold and the inner aspect of the thyroid cartilage. Factors that increase intra laryngeal pressure can lead to the development of laryngocele. Laryngocele mainly affects males in the sixth decade and is usually unilateral and mixed. This is a report of a rare case laryngocele in a young ramratan male patient.

---

### I. Introduction

In 1741 Morgagni described the laryngeal ventricle, a small recess on the anterior wall of the larynx. In 1837 Hilton revealed a cul-de-sac extension at the bottom of the ventricle, called the laryngeal appendix or saccule. An abnormal dilatation of the saccule forming an air sac in contact with the laryngeal opening is called a laryngocele, a term coined by Virchow in 1867 although it was previously described by Larrey in 1829. In the United Kingdom, the incidence of laryngocele is approximately one per 2.5 million of the population per year. The incidence is 5:1 in favour of men and the peak age of incidence is at 50-60 years; 82% are found in Caucasians; 85% are unilateral and 15% bilateral. Laryngocele can be external (30%) where the sac arises from the laryngeal ventricle and expands into the neck through the thyrohyoid membrane, or internal (20%) where it arises from the laryngeal ventricle and stays within the larynx presenting in the vallecula, or combined (50%). Laryngoceles are lined with columnar ciliated epithelium whereas simple laryngeal cysts are lined by squamous epithelium. Congenital and acquired factors are considered to play a role in the development of laryngoceles. In view of the remote chance of malignancy, careful investigation is necessary. The structures are mostly asymptomatic, but symptoms of hoarseness, dyspnoea, dysphagia, upper airway obstruction and pain may occur. If the Valsalva maneuver is performed, swelling may appear in the neck, caused by increased intralaryngeal pressure. We describe a patient who presented with hoarseness and progressive airway obstruction, caused by a combined laryngocele. This case was successfully treated at Queen Alia Military hospital QAMH).

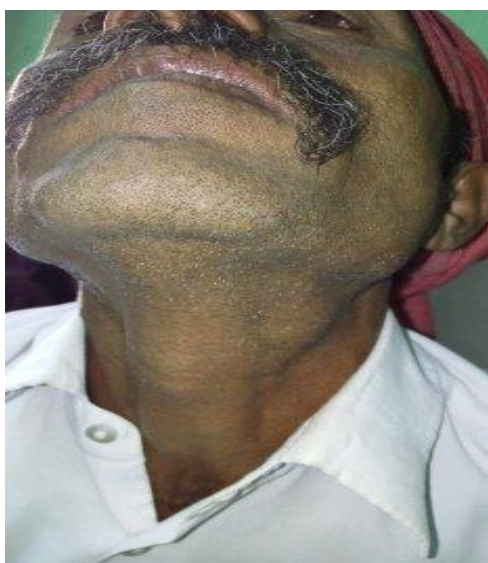

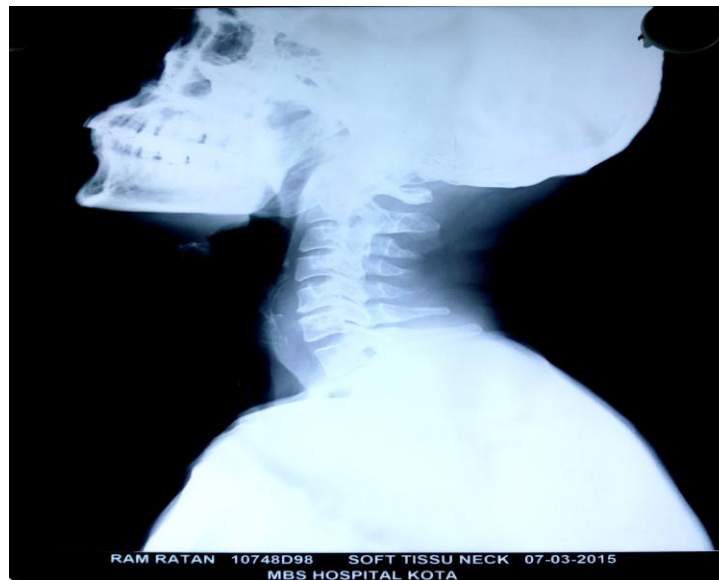fig.1 RAMRATAN 45/MALE LEFT SIDE MIXED LARYNGOCELE

### Case Report

A 45 year old male patient, smoker, farmer by profession presented to the Ear Nose Throat Out Patient Department with complaints of painless swelling in the upper part of the left side of neck. The patient have a cough, change of voice, difficulty in swallowing or difficulty in breathing.

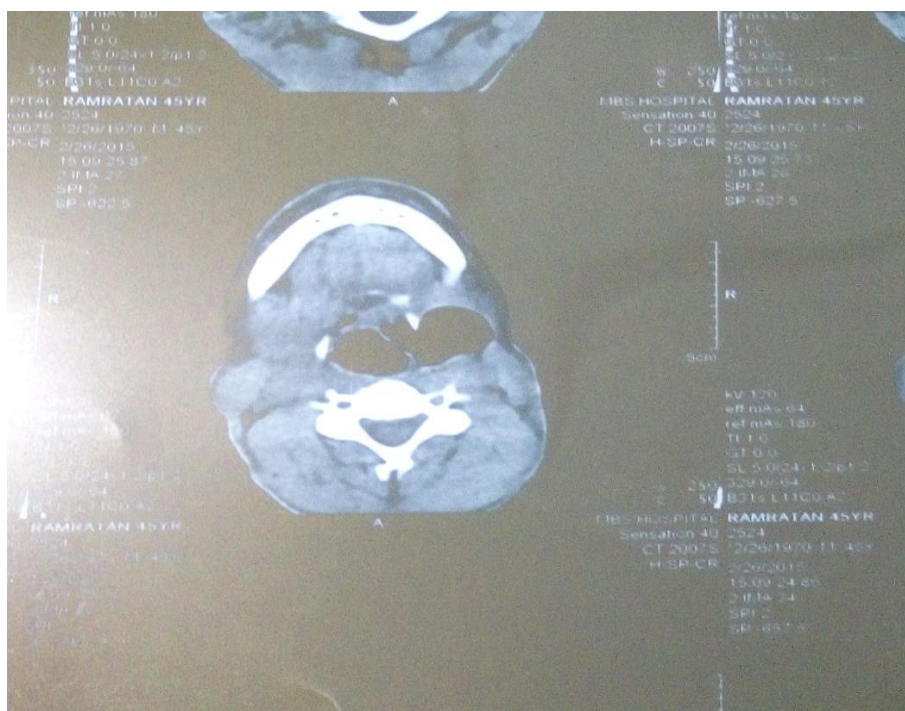
On examination the patient had a diffuse, non tender, cystic swelling in the upper part of the neck on the left side. The swelling was approximately 3.5cm x 3cm in size and extended below the lower border of the mandible to the level of the lower border of the thyroid cartilage in the anterior triangle, as seen pic. The swelling was compressible and increased in size when the patient performed the Valsalva manoeuvre and on coughing.

On 90 degree Laryngoscopy revealed a mild bulge at the level of the left false cord. The rest of the larynx and vocal cords were normal. lateral soft tissue neck X-ray showed a large air filled sac in the side of the neck, . The sac was shown to be connected to the airway by a small stalk. The internal component on the right side could also be clearly visualized.



**Figure 2:** lateral soft tissue neck x-ray

Computed Tomography Scan of the neck showed the presence of the Laryngocele as a well defined, smooth, air filled sac in the superior paralaryngeal space. The connection between the air sac and the airway helped to establish the diagnosis. The patient had a mixed Laryngocele on both sides with a large extralaryngeal component on the left side and a small extralaryngeal component on the right side.



**Fig3.** ct scan of pt showing mixed

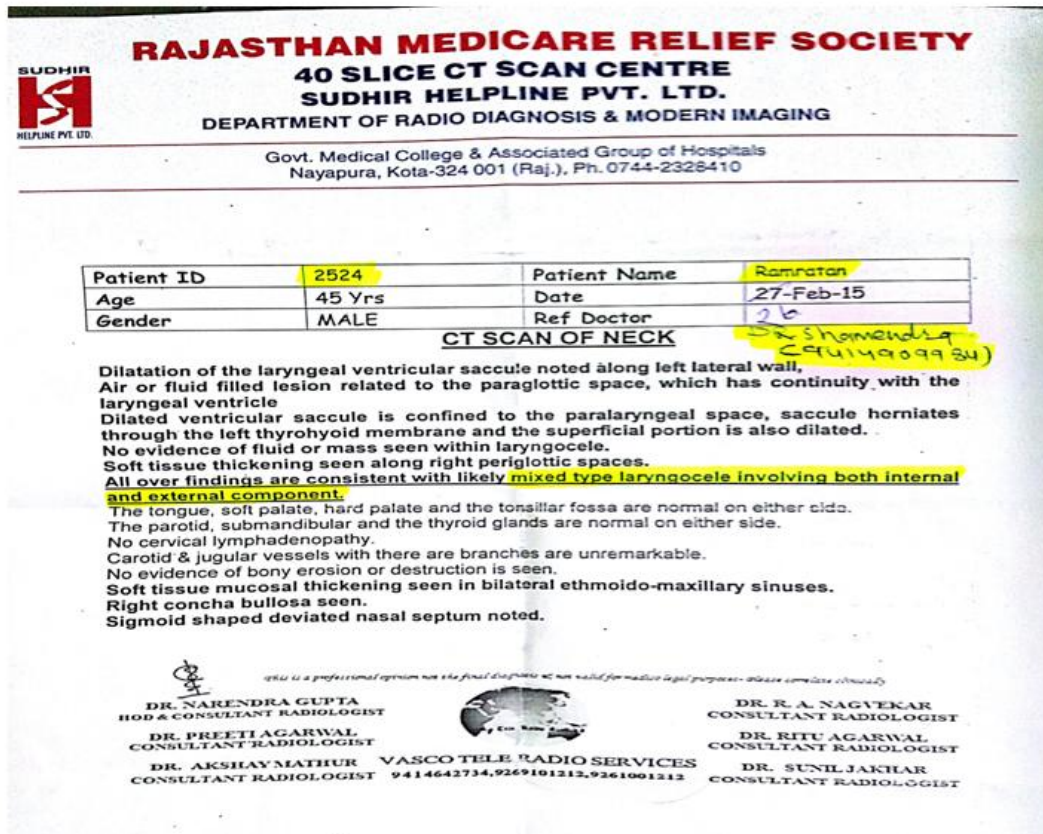


Fig4. report of ct scan

## II. Discussion

There are three types of laryngocele. An internal laryngocele remains confined to the interior of the larynx but extends into the false vocal folds and into the aryepiglottic fold. An external laryngocele extends through the thyrohyoid membrane superiorly. A combined laryngocele has internal and external components. The pathogenesis of laryngocele is uncertain. Some theories are suggested. One of these is the congenital predisposition related to embryological development of sacculle. Another theory suggests that increased intralaryngeal pressure leads to the herniation or dilatation of the sacculle; this theory is supported by the prevalence of laryngocele in patients of certain occupations such as glass blowers. In many of the laryngeal tumors, bilateral or contralateral laryngocele may form as a result of the increase in intralaryngeal pressure during speaking or clearing secretions. Laryngocele can be associated with certain conditions such as squamous cell carcinoma of the larynx (16-18%) and laryngeal amyloidosis. Derek *et al.* reported a case of bilateral external laryngocele following radioiodine ablation for Graves disease. It also has been reported as an acquired condition following neck surgery and in some patients who use ventricular phonation during speech. Laryngoceles are often asymptomatic, but present with symptoms of cough, hoarseness, foreign body sensation or a cystic swelling anterior to the sternocleidomastoid muscle. Some cases may present with dysphagia, dyspnoea, and snoring. One in 10 cases presents with infected sacs-pyocoeles. Opinion is divided regarding the use of endoscopic or external approach for laryngocele resection, with the final decision influenced by laryngocele size, risk of incomplete resection, damage to the structures of the larynx, surgeon preference, and results.

Our patient presented with symptoms of snoring, hoarseness, and stridor. He had neck swelling with Valsalva maneuver therefore the diagnosis was based on the clinical history and on the results of the radiological investigations which were all characteristic of mixed (combined) laryngocele. The patient's occupation did not include any of the mentioned risk factors predisposing him for the development of laryngocele; the only potential risk factor in this case is the chronic obstructive pulmonary disease.

The differential diagnosis mainly includes any cystic swelling in the upper part of the neck like branchial cyst, submandibular salivary gland duct cyst, cystic hygroma, saccular cyst, mucous retention cyst, thyroglossal duct cyst and neck swellings which increase in size on valsalva manoeuvre like Jugular vein phlebectasia. A saccular cyst should also be kept in mind when an internal laryngocele is diagnosed. A pharyngocele also presents as a cystic swelling in the upper part of the neck.

### III. Conclusion

The diagnosis of Laryngocele should be kept in mind in cases of upper neck swelling. Laryngocele is considered a rare condition which may present with variable symptoms ranging from mild to life threatening. Care must be taken to exclude malignancy as an etiologic factor. Endoscopic examination should be performed and biopsy can be taken to rule out malignancy. CT scan is the best choice in making a differential diagnosis between this and other neoformations. The choice and modality of surgery should be individualized according to the age and the surgeon's experience.

### Acknowledgements

The authors reported no conflict of interest and no funding was received on this work.

### References

- [1]. **Cassano L, Lombardo P, Marchese-Ragona R, et al.** Laryngopyocele: Three new clinical cases and review of the literature. *Eur Arch Otorhinolaryngol* 2000; 257(9): 507-511.
- [2]. **Maran AGD.** Benign disease of the neck. In: John Hibbert, editor. *Laryngology and head and neck surgery*. 6<sup>th</sup> ed. Great Britain by Bath press. 1997; 16: 17-18.
- [3]. **Pennings RJ, Van den Hoogen FJ, Marres HA.** Giant laryngocele: A cause of upper airway obstruction. *Eur Arch Otorhinolaryngol* 2001; 258(3): 137-140.
- [4]. **Cankaya H, Egeli E, Unal O, Kiris M.** Laryngeal amyloidosis: A rare cause of laryngocele. *Clin Imaging* 2002; 26(2): 86-88.
- [5]. **Stocker DJ, Kelly WF, Fitzpatrick TM, et al.** Bilateral external laryngoceles following radioiodine ablation for Graves disease. *Arch Intern Med* 2002; 162(17): 2007-2009.
- [6]. **Tawalbeh MI, Nawasreh O, Husban A, Momani O.** Laryngocele: A case report. *JRMS* 2003; 10(2): 54-57.
- [7]. **Harney M, Patil N, Walsh R, et al.** Laryngocele and squamous cell carcinoma of the larynx. *J Laryngol Otol* 2001; 115(7): 590-592.
- [8]. **Akbas Y, Unal M, Pata YS.** Asymptomatic bilateral mixed-type laryngocele and laryngeal carcinoma. *Eur Arch Otorhinolaryngol* 2004; 261(6): 307-309.
- [9]. **Meda, P.** Symptomatic laryngocele in cancer of larynx. *A. M. A. Arch. otolaryng.*, 1952, 56, 512-520.
- [10]. **Harney M, Patil N, Walsh R, Brennan P, Walsh M.** Laryngocele and squamous cell carcinoma of the larynx. *J Laryngol Otol* 2001; 115: 590-2.
- [11]. **Taylor, H. M.** Ventricular laryngocele. *Jr. Am. Laryng. A.*, 1944, 66, 114-126.
- [12]. **Binu R. George, Suhel Hasan, Naveen Kumar G, Salem MS. Tobook, Manjula Dhinakar.** A Rare Case of Laryngocele in a Young Omani Male. *George BR, et al. OMJ*. 25, (2010); doi: 10.5001/omj. 2010. 45.
- [13]. **J Gulia, S Yadav, A Khaowas, S Basur, A Agrawal.** Laryngocele: A Case Report and Review of Literature. *Indian Journal of otorhinolaryngology*, 14(1).
- [14]. **Prasad K C, Vijayalaxmi S, Prasad S C, Laryngoceles-** Presentations and management, *Indian J. of Otolaryngology Head Neck Surgery*, Oct-Dec 2008; 60; 303-306.
- [15]. **Nazaroglu H, Ozates M, Uyar A, Deger E, Simsek M.** Laryngopyocele: signs on computed tomography. *Eur J Radiol* 2000;33(1):63-5
- [16]. **Micheau C, Luboinski B, Lanchi P, Cachin Y.** Relationship between laryngoceles and laryngeal carcinomas. *Laryngoscope* 1978;88(6):680-8
- [17]. **Dursun G, Ozgursoy OB, Beton S, Batikhhan H.** Current diagnosis and treatment of laryngocele in adults. *Otolaryngol Head Neck Surg* 2007;136(2):211-5
- [18]. **Matino Soler E, Martinez Vecina V, et al.** Laryngocele: clinical and therapeutic study of 60 cases. *Acta Otorrinolaringol Esp* 1995;46(2):279-86.