

Influence of Ethanolic Extractives of Leaves of Mulberry, *Morus Alba* (L) On 7, 12-Dimethylbenz (A) Anthracene (Dmba) Induced Buccal Pouch Carcinoma in Syrian Hamster, *Mesocricetus auratus* (L)

Vitthalrao B. Khyade¹ Suryakant M. Mundhe² Shakir Ali Syed³

1. Department of Zoology, Shardabai Pawar Mahila Mahavidyalaya, Shardanagar; Tal. Baramati; Dist. Pune – 413115.

2. Principal, Shardabai Pawar Vidyaniketan, Shardanagar; Tal. Baramati; Dist. Pune – 413115.

3. Programme Coordinator, Krishi Vidyan Kendra, Agricultural Development Trust, Baramati; Shardanagar; Tal. Baramati; Dist. Pune – 4133115 (India).

Abstract: The study deals with investigation of the chemopreventive potential and antilipidperoxidative effects of ethanolic leaf extract of mulberry, *Morus alba* (L) (TpEt) on 7,12-dimethylbenz(a)anthracene (DMBA)-induced buccal pouch carcinoma in Syrian hamster, *Mesocricetus auratus* (L). Oral squamous cell carcinoma was developed in the buccal pouch of Syrian golden hamsters, by painting with 0.5% DMBA in liquid paraffin, thrice a week, for 14 weeks. The tumor incidence, volume and burden were determined. Oral administration of TpEt at a dose of 300 mg/kg, body weight, to DMBA (on alternate days for 14 weeks)- painted animals significantly prevented the incidence, volume and burden of the tumor. TpEt showed potent antilipidperoxidative effect, as well as enhanced the antioxidant status in DMBA- painted animals. TpEt has potent chemopreventive efficacy and significant antilipidperoxidative effect, in DMBA-induced oral carcinogenesis. The active principle of mulberry leaf may have the abilities of induction of apoptosis, which involve disruption of mitochondrial membrane potential, release of cytochrome C and activation of caspase. With its bioactive compounds, mulberry, *Morus alba* (L) may open a new avenue in the cancer prevention and treatment.

Keywords: Syrian hamster ; Buccal pouch carcinoma ; Mulberry.

I. Introduction

Most of the plants are with chemical compounds that are analogous with animal hormones and therefore they are accredited as “Healthy and Wealthy” (Vitthalrao Khyade and Vivekanand Khyade, 2013 and 2013). The plants, through their biocompounds serve to orchestrate the progression of cytological health. The mulberry, *Morus alba* (L) is with many more medicinally important constituents. Moracin is the compound isolated from mulberry fruits. This compound have been reported to cure the skin cancer in mice (Vitthalrao Khyade, et al , 2013). The mulberry leaf extractive was found excellent to cure the diabetes in the experimental mice (Vitthalrao Khyade, 2014). Oral squamous cell carcinoma, the fifth most common malignancy worldwide, is predominantly a disease of men, in the fifth to eighth decades of life. While it accounts for 3-4% of all malignancies in western countries, India has recorded the highest incidence, accounting about 30 - 40% of all cancers. Cancer of the oral cavity are frequently associated with chewing of betel quid containing tobacco, in addition to smoking and alcohol consumption (Moore, et al, 2000). 7,12-dimethylbenz(a)anthracene (DMBA)-induced hamster buccal pouch carcinogenesis, is a well suited model for studying precancerous and cancerous lesions of human oral squamous cell carcinoma, since it is morphologically and histologically similar to human tumors, as well as, it expresses many biochemical and molecular markers that are expressed in humans (Boring, et al, 1994). Lipid peroxidation, a potent reactive oxygen species (ROS)- mediated chain reaction, has been implicated in the pathogenesis of several disorders, including oral carcinoma. Overproduction of reactive oxygen species within tissues can damage DNA and possibly contribute to mutagenesis and carcinogenesis. However organisms have an array of potent adaptive antioxidant defense mechanisms [enzymatic antioxidants: superoxide dismutase (SOD), catalase (CAT) and glutathione peroxidase (GPx) and non-enzymatic antioxidants: reduced glutathione (GSH), vitamin C and vitamin E] within the cells, to combat the deleterious effects of reactive oxygen species- mediated oxidative damage (Ray and Husain, 2002). Cancer chemoprevention is a new promising strategy for prevention, inhibition or reversal of carcinogenesis, induced by specific natural or synthetic chemicals (Hans Peter, et al , 2000). For a large number of the world's rural population, medicinal plants are the only source for the prevention and treatment of various pathological diseases, from time immemorial. Several medicinal plants and their constituents have been reported, to prevent multistage carcinogenesis (Craig, 1999). The biochemical constituents of mulberry, *Morus alba* (L) serve to orchestrate the progression of life cycles of lepidopteran

insects, like silkworm, Bombyxmori (L). Mulberry leaves are cut for food for the livestock (Cattle, goat,...etc.) in the areas where dry seasons restrict the availability of ground vegetation. In traditional Chinese medicine, the mulberry fruits are used to treat the premature grey hairs, to fortify the blood and to treat the constipation and diabetes. Moracin is the compound extracted and isolated from the mature fruits of mulberry, Morusalba (L). The moracin – M; Steppogenin – 4' – o – beta – D – glucoside and mulberroside are the novel biocompounds of mulberry, which found to produce hyperglycemic effects (Zhang, et al , 2009). Ethanolic extractives of leaves of mulberry, Morus alba (L) had antihyperglycemic, antioxidant and antiglycation effects in chronic diabetic rats (Naowaboot, et al, 2009 and Vitthalrao B. Khyade, 2014). The efforts conducted to assess the protective influence of Moracin, the major constituent of fruits of mulberry, Morus alba (L) on tumor promotion in 7, 12 – dimethylbenz (alpha) anthracene (DMBA) – initiated and 12 – O – tetradecanoylphorbol 13 – acetate (TPA) – promoted skin tumorigenesis in mice was found most significant effects (Vitthalrao B. Khyade, et al , 2013). The expression of tumor necrosis factor (TNF) – alpha protein and the level of 4 – hydroxynoneal (4HNF) in the normal epidermis were significantly reduced in moracin treated mice (UjwalaLonkar and Vitthalrao B. Khyade, 2013). Moracin treatment furthermore significantly suppressed the elevation in 4 – HNE level and elevated expression of c – fos;c – myc and cyclooxygenase – 2 (COX – 2) in epidermal tumorigenesis induced by double application of TPA (BabitaSakdeo and Vitthalrao, 2013).To our best knowledge, there is no scientific report on the chemopreventive efficacy and antilipidperoxidative effects of leaves of mulberry, Morusalna (L) in DMBA – induced , hamster buccal pouch carcinogenesis. Hence, the present study is designed to evaluate the effectiveness of ethanolic leaf extract of Morusalba (TpEt) in modifying the carcinogenic process, as well as oxidative alterations in DMBA- induced hamster buccal pouch carcinoma.

II. Material And Methods

7,12-dimethylbenz(a)anthracene (DMBA) was obtained from Sigma-Aldrich Chemical Pvt. Ltd., Bangalore, India. All other chemicals used were of analytical grade. Male, golden Syrian hamsters, Mesocricetusauratus (L) 8-10 weeks old, weighing 80-120 g, were purchased from National Institute of Nutrition, Hyderabad, India and maintained in the domestic cages, made up of polypropylene. The animals were housed in groups of four or five in polypropylene cages and provided standard pellet diet and water ad libitum and maintained under controlled conditions of temperature and humidity, with a 12 h light/dark cycle.

The fresh leaves of mulberry, Morus alba (L) were collected from the mulberry garden at the sheti (Malegaon) farm of Agriculture Development Trust, Baramati(India). The leaves washed in running tap water and allowed for drying in shade. Shade dried leaves of mulberry were powdered through the use of domestic mixture. 500 g of dried finely powdered mulberry leaves were soaked with 1500 ml of 95% ethanol, overnight. The residue obtained was again resuspended in equal volume of 95% ethanol for 48 h and filtered again. The above two filtrates were mixed and the solvents were evaporated in a rotovapour at 40-50°C, under reduced pressure. A dark semisolid material (13%) obtained, was stored at -4°C, until use. For experimental studies, a known volume of the extract was suspended in distilled water and orally administered to the experimental animals by gastric intubation, using force-feeding needle.

The institutional animal ethics committee approved the experimental design. The hamsters were randomized into four groups of 10 animals each. Group I served as untreated control. Groups II and III were painted with 0.5% DMBA in liquid paraffin thrice a week, for 14 weeks on the left buccal pouches. Group II received no other treatment. Group III were administered TpEt (300 mg/kg, b.w.) orally starting 1 week before the exposure to the carcinogen and continued on days alternate to DMBA painting, until the animals are sacrificed. Group IV received oral TpEt, only throughout the experimental period. The experiment was terminated at the end of 14 weeks and all the animals were sacrificed by cervical dislocation. Biochemical studies were conducted on blood and buccal mucosa of control and experimental animals, in each group. For histopathological examination, buccal mucosal tissues were fixed in 10% formalin and embedded with paraffin, 2-3 µm sections were cut in a rotary microtome and stained with haematoxylin and eosin.

The erythrocyte membrane was prepared by the method of Dodge et al (1968) modified by Quist (1980). Thiobarbituricacid reactive substances (TBARS) was assayed in plasma, erythrocytes and buccal mucosa, according to the methods of Yagi(1978) Donnan (1950) and Ohkawaet al (1979)respectively. Reduced glutathione (GSH) was determined by the method of Beutler and Kelley (1963). Vitamin C and E were measured according to the methods of Omayeet al (1979) and Desai (1984) respectively. The enzymatic antioxidant activities were estimated by the methods of Kakkaret al(1984) (SOD), Sinha (1972) (CAT) and Rotrucket al (1973) (GPx), respectively.

Collected data was expressed as mean with standard deviation and subjected for statistical analysis. Statistical analysis was performed by one-way analysis of variance (ANOVA), followed by Duncan's multiple range test (DMRT). The values were considered statistically significant, if P was less than 0.05.

III. Results And Discussion

The results of present study has been categorized in the parameters, which include: Incidence, volume and burden of tumor; Histopathological changes; TBARS and antioxidant status of Plasma; Erythrocytes; and Buccal mucosa.

- A. Incidence, volume and burden of tumor: The effect of TpEt on the incidence, volume and burden of tumor in DMBA- induced hamster buccal pouch carcinoma are summerised in table - 1. In DMBA- painted hamsters (Group II), a 100% tumor formation with mean tumor volume (472 mm³) and tumor burden (2029 mm³), was observed. Oral TpEt (300 mg/kg, b.w.) significantly prevented the incidence, volume and burden of tumor in DMBA- painted hamsters (Group III). No tumor was observed in control (Group I) as well as TpEt alone- treated animals (Group IV).
- B. Histopathological Changes: The histopathological features of control and experimental animals in each group are summarized in table – 2. A myriad of histopathological changes (severe keratosis, hyperplasia, dysplasia and squamous cell carcinoma of the epithelium), were observed in hamsters painted with DMBA alone (Group II). A mild to moderate preneoplastic lesions [hyperplasia (++) , keratosis (+) and dysplasia (+)], were noticed in Group III animals (DMBA + TpEt).
- C. Plasma TBARS and antioxidant status: The status of TBARS and antioxidant in plasma and erythrocytes of the control and experimental groups is summarized in table - 3. The concentration of TBARS was increased, whereas the levels of nonenzymatic antioxidants (GSH, Vitamin C and Vitamin E) and activities of enzymatic antioxidants (SOD, CAT and GPx), were significantly decreased in group II (DMBA alone), as compared to control animals. Oral administration of TpEt significantly decreased the levels of TBARS and improved the antioxidants status in DMBA- painted hamsters. TpEt alone- treated hamsters showed no significant difference in TBARS and antioxidants status, as compared to control animals.
- D. Erythrocyte TBARS and antioxidant status: The status of TBARS and antioxidant in plasma and erythrocytes of the control and experimental groups is summarized in table - 4. The concentration of TBARS was increased, whereas the levels of nonenzymatic antioxidants (GSH, Vitamin C and Vitamin E) and activities of enzymatic antioxidants (SOD, CAT and GPx), were significantly decreased in group II (DMBA alone), as compared to control animals. Oral administration of TpEt significantly decreased the levels of TBARS and improved the antioxidants status in DMBA- painted hamsters. TpEt alone- treated hamsters showed no significant difference in TBARS and antioxidants status, in comparison with the control group.
- E. Buccal Mucosa TBARS and antioxidant status: The changes in TBARS and antioxidant properties of buccal mucosa are summarized in table – 5. Decrease in TBARS concentration and alterations in the antioxidant status (Vitamin E, GSH and GPx were increased; SOD and CAT were decreased), were noticed in cancer animals (Group II) as compared to control (Group I). However oral administration of TpEt (Group III), reverted the concentration of TBARS and antioxidants to near normal range in DMBA- painted animals. Hamsters treated with TpEt alone (Group IV) showed no significant difference in TBARS and antioxidants status, as compared to control animals.

The incidence and mortality rates of oral cancer vary widely across the world, but the highest rates were reported every year from developing countries, particularly from India. Oral cancer is one among the few human cancers, with the vast potential for prevention. A major target of reactive oxygen species is cell membrane, due to the high content of polyunsaturated fatty acids. Reactive oxygen species mediated lipid peroxidation causes damage to cellular DNA, membrane structure and inhibition of functions several enzymes and alterations in the immune system (Thirunavukkarasu, et al , 2001). In cancer, enormous production of free radicals in the system has been reported. A close relationship between free radical activity and neoplastic transformation, has been shown (McCord, 2000). Antioxidants (enzymatic and non-enzymatic) play a vital role in scavenging reactive oxygen species and protect the cells from oxidative damage. Vitamin E, Vitamin C and reduced glutathione, are primary defense antioxidants. They provide protection against several reactive oxygen species, development of cancer and other oxidative stress- mediated dysfunctions (Ray and Hussain, 2002). SOD, CAT and GPx, are important antioxidant enzymes that protect cell and tissue damage from enhanced lipid peroxidation, via elimination of reactive oxygen species. Elevated lipid peroxidation and poor antioxidant systems, have been reported in oral cancer patients. Sabitha and Shyamaladevi(1999) have suggested, that a lack of antioxidant defense is responsible for the elevated lipid peroxidation in erythrocytes. Altered activities of enzymatic antioxidants are reported during carcinogenesis or after tumor formation. Hence, the elevated lipid peroxidation in the circulation of cancer animals, is due to poor antioxidant defense mechanism. Lowered non - enzymatic antioxidants (Vitamin C, Vitamin E and GSH) in the circulation, are probably due to elevated lipid peroxidation or sequestration by the tumor tissues for their rapid growth. Diminished lipid peroxidation and disturbed antioxidants status (GSH and GPx were increased, whereas SOD and CAT were decreased), were observed in tumor tissues, as compared to normal tissues. Cancer cells showed decreased susceptibility to lipid

peroxidation, compared to normal tissues. An inverse relationship between the lipid peroxidation process and the rate of cell proliferation, has been reported (Subapriya, et al , 2002). Glutathione, a biologically important tripeptide, is essential for maintaining cell integrity, due to its reducing properties and participation in the cell metabolism. Glutathione peroxidase and its co-substrate glutathione, are reported to have regulatory effects on cell proliferation. Elevated glutathione and GPx activity, have been demonstrated in several tumor tissues, including oral cancer. It has been postulated that diminished lipid peroxidation combined with enhanced glutathione-dependent antioxidant capacity of oral tumors, facilitates cell- proliferation, offering selective growth advantage in tumor cells over their surrounding normal cells. Our results lend credibility to the above observations (Subapriya et al, 2002 and Vitthalrao B. Khyade, et al , 2013). Decrease in SOD and catalase activities described in tumors, is regarded as markers of malignant transformation. Lowered activities of SOD and CAT were reported in several cancers, including skin tumorigenesis and oral cavity cancer (Sabita and Shymaladevi, 1999 ; Subapriya et al, 2002 and Babita Sakdeo and Vitthalrao Khyade, 2013). The results of present study seems to parallel with these observations. The application of 0.5% DMBA in liquid paraffin thrice a week, for 14 weeks to the hamster buccal pouch, induced oral carcinoma. We have also noticed the precancerous lesions in DMBA- painted hamsters, from the 10th week of the experimental period. In the present study oral administration of TpEt at a dose of 300 mg/kg, b.w., reduced tumor incidence, volume, burden and the number in DMBA- painted hamsters. Our results thus indicate, that TpEt possess significant chemopreventive potential against DMBA- induced buccal pouch carcinoma. Furthermore, TpEt significantly reduced the levels of TBARS and enhanced the status of antioxidants in the circulation of DMBA- painted hamsters. We also noticed an elevation of TBARS level and improvement in antioxidant defense system in the buccal mucosa of DMBA-painted hamsters, after treatment with TpEt. It has reported that the chemopreventive properties of plant anticarcinogens are either due to antilipidperoxidative action, modulating carcinogen detoxification or by improving the antioxidant defense system (Johnson, 1997 and Ujjwala Lonkar and Vitthalrao Khyade, 2013). Most of the plants are with chemical compounds that are analogous with animal hormones, which accredited them for medicinal plants (Vitthalrao Khyade and Vivekanand Khyade, 2013 and 2013). The medicinal plants and their constituents, probably exert their chemopreventive effect, by scavenging reactive oxygen species and improving the antioxidant defense systems. The present study reveals, that the chemopreventive effect of TpEt in DMBA- painted animals, is probably due to its antilipidperoxidative and antioxidant properties.

Acknowledgements

The author express sincere thanks to National Chemical Laboratory, Pune for the valuable support. The help received from Agriculture Development Trust, Baramati for the study is acknowledged. The first author express his thanks to M. S. Shejul for excellent treatment on 13 December, 2014 (1.30 p.m. to 2.20 p.m.); which availed the academic speed in handling the process of publication of present paper.

References

- [1]. Babita M. Sakdeo and Vitthalrao B. Khyade (2013). Effect of Moracin on DMBA – TPA induced skin tumor formation in the mice. International Journal Advanced Biological Research Vol. 3 (4): 576 – 583. www.scienceandnature.org Index 20 IJBR pdf.
- [2]. Beutler, E. and Kelley, B. M. (1963). The effect of sodium nitrate on RBC glutathione. *Experientia* 29:96-102.
- [3]. Boring, C. C. ; Squire, T. S. and Tong, T. ; Montgomery, S. (1994). Cancer Statistics. *Calif. Cancer J. Clin.* 44: 7 – 26.
- [4]. Craig, W. J. (1999). Health Promoting Properties of Common Herbs. *American Journal Clinical Nutrition* 70: 491 – 499. PUBMED.
- [5]. Desai, F. D. (1984). Vitamin E analysis methods for animal tissues. Fischer, S. and Packer, L. editors. New York: Methods in enzymology; Academic Press.
- [6]. Deshpande, S. S. ; Shah, G. B. and Parmar, N. S. (2003). Antiulcer activity to Tephrosiapurpurea in rats. *Indian Journal of Pharmacology* 35: 631 – 37.
- [7]. Dodge, J. F. ; Michell, G. and Hanahan, D. J. (1968). The preparation of haemoglobin free ghosts of human red blood cells. *Arch. Biochem. Biophys.* 110: 119 – 48.
- [8]. Donnan, S. K. (1950). The thiobarbituric acid test applied to tissues from rats treated in various way. *J. Biol. Chem.* 182: 415 – 23.
- [9]. Hans peter, W. ; Deuter, M. and Imilda, E. (2002). Chemoprevention of tobacco smoke induced lung carcinogenesis in mice 21: 1977 – 2058.
- [10]. Johnson, I. T. (1997). Plant anticarcinogens. *Eur. J. Cancer Prev.* 6: 15 – 21.
- [11]. Joshi, S. G. (2000). Oleaceae. In: *Medicinal Plants*. New Delhi: Oxford and IBH publishing Co. Pvt. Ltd. Page: 211.
- [12]. Kakkar, D. ; Das, B. and Viswanathan, P. N. (1984). A modified spectrophotometric assay of superoxide dismutase. *Indian J. Biochem. Biophys.* 21: 130 -131.
- [13]. McCord, J. M. (2000). The evolution of free radicals and oxidative stress. *Am. J. Med.* 108: 652. PUBMED.
- [14]. Moore, S. R. ; Johnson, N. W. ; Pierce, A. M. and Wilson, D. F. (2000). The epidemiology of mouth cancer: A review of global incidence. *Oral Dis.* 6: 65 – 74.
- [15]. Ohkawa, H. ; Ohishi, N. and Yagi, K. (1979). Assay for lipid peroxides in animal tissues by thiobarbituric acid reaction. *Annal Biochem.* 95: 351 – 358.
- [16]. Omaye, S. T. and Turnbull, J. D. (1979). Selected methods for the determination of ascorbic acid in animal cells, tissues and fluids. In: *McCormic, D. B. and Wright, D. C. editors. New York: Methods in Enzymology*, Academic Press.
- [17]. Quist, E. H. (1980). Regulation of erythrocyte membrane shape by calcium ion. *Biochem Biophys. Res. Commun.* 92: 631 – 637.

- [18]. Ray, G. and Husain, S. A. (2002). Oxidant, antioxidants and carcinogenesis. *Indian Journal of Experimental Biology* 40: 1213 – 1244.
- [19]. Rotruck, J. T. ; Pope, A. L. ; Ganther, H. E. ; Swanson, A. B. ; Hafeman, D. G. and Hoekstra, W. G. (1973). Selenium : Biochemical role as a component of glutathione peroxidase. *Science* 179: 588 – 590.
- [20]. Sabitha, K. E. and Shyamaladevi, C. S. (1999). Oxidant and antioxidant activity changes in patients with oral cancer and treated with radiotherapy. *Oral Oncology* 35: 273 – 279.
- [21]. Saleem, M. ; Ahmed, S. ; Alam, A. and Sultana, S. (1999). Tephrosiapurpurea alleviates phorbol ester – induced tumor promotion response in murine skin. *Pharm. Pharmacol. Comm.* 5: 455 – 461.
- [22]. Sharma, S. ;Stutzman, I. D. ; Kelloff, G. J. and Steele, V. E. (1994). Screening of potential chemopreventive agents using biochemical markers of carcinogenesis. *Cancer Research* 54: 5848 – 5855.
- [23]. Sinha, K. A. (1972). Colorimetric assay of catalase. *Anal Biochem.* 47: 389 – 394.
- [24]. Subapriya, R. ;Kumaraguruparan, R. ; Ram Chandran, C. R. and Nagini, S. (2002). Oxidant – antioxidant status in patients with oral squamous cell carcinomas at different intraoral sites. *Clinical Biochemistry* 35: 489 – 493.
- [25]. Thirunavukkarasu, C. ; Prince Vijeyasingh, J. ; Selvendiran, K. and Sakthisekaran, D. (2001). Chemopreventive efficacy of selenium against DEN – induced hepatoma in albino rats. *Cell Biochem. Funct.* 19: 265 – 271.
- [26]. Ujjwala D. Lonkar and Vitthalrao B. Khyade (2013). Effect of Moracin on DMBA – TPA induced cancer in mice, *Musmusculus (L)*. *Annals of Plant Sciences* Vol. 2 No. 10 : 412 – 419. <http://ebioscholar.com/ojs/index.php/ap/article/view/628/528>
- [27]. Vitthalrao B. Khyade; Vivekanand V. Khyade and Sunanda V. Khyade (2013). Use of Moracin in preventing the cancer. *Journal of Environmental Science, Toxicology and Food Technology (IOSR-JESTFT)* e-ISSN: 2319 – 2402, p-ISSN: 2319 – 2399. Volume 4, Issue 5 (May – June 2013), PP 96 – 104. www.Iosrjournals.org
- [28]. Vitthalrao B. Khyade and Vivekanand V. Khyade (2013). *Plants : The Source of Animal Hormones*. “Frontiers in Life Sciences”, the book published by Science Impact publication, Ahmedpur (Latur) – 413515 (India): 151 – 168. Editor: Dr. SayyedIliyasUsman (Poona College, Camp Pune). ISBN: 978 – 93 – 5067 – 394 – 2.
- [29]. Vitthalrao B. Khyade and Vivekanand V. Khyade (2013). The Phytochemicals of Animal Hormone Analogues. *Annals of Plant Sciences* Vol. 2 (5): 125 – 137. <http://annalsofplantsciences.com/index.php/aps/issue/view/10> ISSN: 2287 – 688X.
- [30]. Vitthalrao B. Khyade (2014). Effect of leaf extractives of Mulberry, *Morusalba (L)* on biochemical parameters in diabetic rats. *International Multidisciplinary* Vol. – III, Issue – III, March – 2014. *Ejournal* ISSN 2277 – 4262: 21 – 33 (www.shreeprakashan.com)
- [31]. Yagi, K. (1978). Lipid peroxides and human disease. *Chem. Physiol. Lipids* 45: 337 – 351.

Table – 1: Influence of treatment with leaf extract of mulberry, *Morus alba (L)* on oral squamous cell carcinoma in 0.5 percent DMBA painted Syrian hamster, *Mesocricetusauratus(L)*.

Groups	Control	0.5 % DMBA	0.5 % DMBA + Mulberry Extract (300 mg / Kg)	Mulberry Extract (Alone) (300 mg / Kg)
Parameters				
Tumor Incidence	00.00	100 %	20 %	00.00
Total No. of Tumors	00.00	43 %	4.00 %	00.00
Tumor volume (cubic mm)	00.00	472.41 (± 57.33)	97.96 (± 13.07)	00.00
Tumor Burden (cubic mm)	00.00	2029.61(± 178.60)	194.92 (± 38.18)	00.00

Each value is the mean of three replications. Figures in parenthesis with(±) signs are the standard deviations. Tumor volume was measured through the use of formula : $V = (4 \text{ divided by } 3) \times \text{Pi} \times (\text{D1 divided by } 2) \times (\text{D2 divided by } 2) \times (\text{D3 divided by } 2)$, where D1 ; D2 and D3 are the three diameters of tumor. Tumor burden was calculated by multiplying tumor volume and number of tumors per animal. Mulberry leaf extract was administered orally (300 mg / kg body weight of expt. Animal) one week before BMBA painting and continued on alternate days to DMBA paintings until sacrifice. DMBA (0.5 % in liquid paraffin) was painted on the left buccal pouch thrice a week for 14 weeks.

Table – 2: Histopathological changes in oral cheek mucosa of mulberry leaf extract treated, 0.5 percent DMBA painted Syrian hamster, *Mesocricetusauratus(L)*.

Groups	Control	0.5 % DMBA	0.5 % DMBA + Mulberry Extract (300 mg / Kg)	Mulberry Extract (Alone) (300 mg / Kg)
Parameters				
Keratosis	Absent	Severe	Moderate	Absent
Hyperplasia	Absent	Severe	Mild	Absent
Dysplasia	Absent	Severe	Mild	Absent
Squamous Cell Carcinoma	Undifferentiated	Moderately Differentiated	No	Undifferentiated

Table – 3 : Plasma TBARS and antioxidant status in mulberry leaf extract treated, 0.5 percent DMBA painted Syrian hamster, *Mesocricetusauratus(L)*.

Parameters	TBARS	GSH	Vitamin C	Vitamin E	SOD	CAT	GPx
Groups	(nmoles / ml)	(mg/dl)	(mg/dl)	(mg/dl)	(U*/ml)	(U**/ml)	(U***/ml)
Control	2.97 (± 0.25)	28.88 (± 2.4)	1.48(± 0.12)	1.21(± 0.12)	2.87(± 0.12)	0.43 (± 0.12)	133.8 (± 0.1)
DMBA	4.64(± 0.41)	19.71(± 1.31)	0.86(± 0.08)	0.70 (± 2.4)	1.76 (± 0.07)	0.27 (± 2.4)	98.3(± 8.6)
DMBA+Mul.	3.41(± 0.36)	25.65(± 2.2)	1.25(± 0.11)	1.08(± 0.10)	2.58(± 0.20)	0.38(± 0.03)	126.4 (± 11.8)
Mul. alone	2.84 (± 0.16)	30.21(± 2.8)	1.50(± 0.12)	1.28(± 0.17)	2.96(± 0.23)	0.45(± 0.04)	138.2 (± 12.3)
One – Way F	63.431	39.239	70.251	58.215	60.312	56.575	22.246
ANOVA df	3,36	3,36	3,36	3,36	3,36	3,36	3,36
P<0.05	< 0.05	< 0.05	< 0.05	< 0.05	< 0.05	< 0.05	< 0.05

Each value is the mean of three replications. Figures in parenthesis with sign are the standard deviations. * indicate the amount of enzyme required to inhibit fifty percent NBT reaction. ** indicate micromoles of hydrogenperoxide utilized per second. *** indicate micromoles of glutathione utilized per minute. 0.5 % DMBA in liquid paraffin was painted on the left buccal pouches thrice a week for total 14 weeks. Table – 4 : Erythrocytes TBARS and antioxidant status in mulberry leaf extract treated, 0.5 percent DMBA painted Syrian hamster, *Mesocricetusauratus*(L).

Parameters	Erythrocyte	Erythrocyte	Erythrocyte	Erythrocyte	CAT	GPx		
	TBARS	TBARS	Vitamin E	GSH	Lysate SOD	(U [*] /mg Hb)	(U ^{**} /mg Hb)	(U ^{***} /mg Hb)
Groups	(pmoles / mg Hb)	(n moles / mg protein)	(microgram / mg protein)	(mg / dl)	(U [*] /mg Hb)	(U ^{**} /mg Hb)	(U ^{***} /mg Hb)	
Control	1.91 (± 0.18)	0.34 (± 0.03)	2.32(± 0.12)	42.35(± 3.81)	2.17(± 0.22)	1.24 (± 0.13)	14.63 (± 0.11)	
DMBA	2.65(± 0.22)	1.2(± 0.11)	1.48(± 0.09)	29.67 (± 2.6)	1.46 (± 0.17)	0.82 (± 0.08)	7.58(± 1.63)	
DMBA+Mul.	2.16(± 0.19)	00.92(± 0.06)	2.12(± 0.20)	38.21(± 3.51)	1.92(± 0.19)	1.12(± 0.09)	11.32 (± 1.08)	
Mul. alone	1.82 (± 0.16)	00.51(± 0.04)	2.40(± 0.19)	44.56(± 3.27)	2.28(± 0.23)	1.31(± 0.14)	15.74 (± 1.26)	
One – Way F	29.207	388.58	60.27	35.942	37.141	41.394	111.79	
ANOVA df	3,36	3,36	3,36	3,36	3,36	3,36	3,36	
P<0.05	< 0.05	< 0.05	< 0.05	< 0.05	< 0.05	< 0.05	< 0.05	

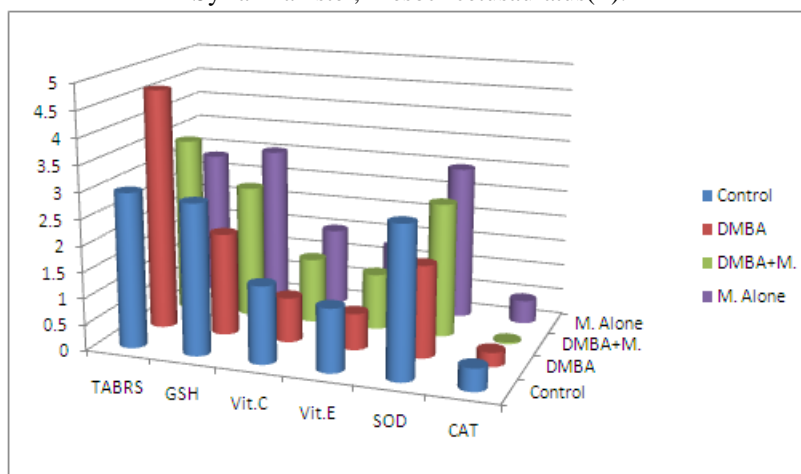
Each value is the mean of three replications. Figures in parenthesis with sign are the standard deviations. * indicate the amount of enzyme required to inhibit fifty percent NBT reaction. ** indicate micromoles of hydrogenperoxide utilized per second. *** indicate micromoles of glutathione utilized per minute. 0.5 % DMBA in liquid paraffin was painted on the left buccal pouches thrice a week for total 14 weeks.

Table – 5 :Buccal Mucosa TBARS and antioxidant status in mulberry leaf extract treated, 0.5 percent DMBA painted Syrian hamster, *Mesocricetusauratus*(L).

Parameters	TBARS	GSH	Vitamin E	SOD	CAT	GPx
Group	(nmoles / 100gm Protein)	(mg/ 100gm tissue)	(mg/ 100gm tissue)	(U [*] /gm Protein)	(U ^{**} /gmProtein)	(U ^{***} /gm Protein)
Control	76.431 (± 5.45)	8.54 (± 3.73)	1.94(± 0.17)	5.43(± 1.36)	38.2(± 2.9)	6.36 (± 1.59)
DMBA	51.5(± 3.62)	12.02(± 3.96)	2.85(± 0.19)	3.81 (± 0.68)	24.4 (± 1.18)	9.37 (± 1.78)
DMBA+Mul.	69.2(± 5.23)	9.32(± 1.74)	2.28(± 0.27)	4.86(± 1.38)	33.93(± 2.13)	7.04(± 1.49)
Mul. alone	77.821 (± 6.29)	8.48(± 1.85)	1.87(± 0.19)	5.62(± 1.43)	39.51(± 4.219)	6.38(± 1.61)
One – Way F	48.467	36.858	45.992	43.533	80.143	63.868
ANOVA df	3,36	3,36	3,36	3,36	3,36	3,36
P<0.05	< 0.05	< 0.05	< 0.05	< 0.05	< 0.05	< 0.05

Each value is the mean of three replications. Figures in parenthesis with sign are the standard deviations. * indicate the amount of enzyme required to inhibit fifty percent NBT reaction. ** indicate micromoles of hydrogenperoxide utilized per second. *** indicate micromoles of glutathione utilized per minute. 0.5 % DMBA in liquid paraffin was painted on the left buccal pouches thrice a week for total 14 weeks.

Fig. 1: Plasma TBARS and antioxidant status in mulberry leaf extract treated, 0.5 percent DMBA painted Syrian hamster, *Mesocricetusauratus*(L).



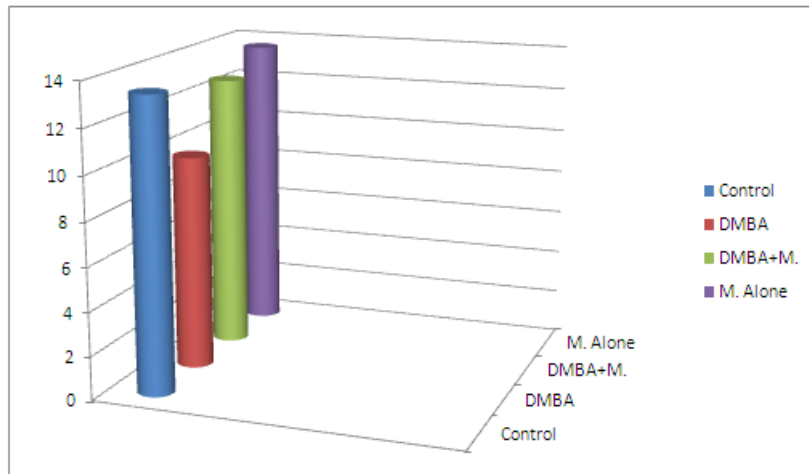


Fig. 2: Erythrocytes TBARS and antioxidant status in mulberry leaf extract treated, 0.5 percent DMBA painted Syrian hamster, *Mesocricetus auratus*(L).

