

Rare Case of an Ophthalmic Rosacea in a Child with Acquired Immunodeficiency Syndrome

I.ER-RACHIQ, Y.Moursli,R.Boubsir, B.Jatik , A.Mchachi , L.Benhmidoune
,A.Chakib , R.Rachid , M.Elbelhadji

Department of Adult ophthalmology , Faculty of Medicine and Pharmacy , Hassan II University-Casablanca ,
Hospital 20 August 1953 , IBN ROCHD UHC , Morocco

M.Nassid, N.Amenzoui, A.A.Bousfiha

Clinical immunology unit, department of pediatric infectious diseases, Casablanca Children's hospital, IBN
ROCHD medical school, king Hassan II university, Casablanca, Morocco

Abstract

Introduction: Infantile rosacea is a rare, but most probably under diagnosed affection with heterogeneous clinical manifestations. Visual impairment is not uncommon, especially in severely affected children. The aim of our work is to report a rare case of rosacea with severe ocular involvement in a child with acquired immunodeficiency syndrome.

Observation: A 5 years old HIV infected child; who had been receiving highly active antiretroviral therapy since birth; had a history of recurrent red eyes. He complained from the last week of painful foreign body sensation in the eyes, photophobia and tearing. The slit lamp examination noted in both eyes a conjunctival hyperemia, keratitis with punctate epitheliopathy and multiple round corneal infiltrates, neovascular pannus and ulceration of the cornea.

In front of the appearance of catarrhal infiltrates mimicking aseptic abscesses, we made the diagnosis of isolated ocular rosacea.

Conclusion: The isolated ocular form of rosacea is most underreported and underdiagnosed. it is a treatable affection which makes its recognition of a great importance.

Key words: Infantile rosacea, ocular rosacea, acquired immunodeficiency syndrome, catarrhal infiltrates

Date of Submission: 28-11-2020

Date of acceptance: 13-12-2020

I. Introduction

Rosacea is a chronic skin disorder of vasomotor instability (1). It's a disease of fair-skinned adults, young or middle-aged, and its prevalence in children is rare (2-3). However, infantile rosacea is probably underreported (4). Visual impairment is not uncommon, especially in severely affected children (5-6), but eye damage is not necessarily associated with inflammatory skin rosacea, often delaying appropriate anti-inflammatory therapy (7).

Due to the low prevalence of rosacea in childhood, as well as often missing skin stigmas, the diagnosis of ocular rosacea in this age group is often delayed. We report a rare case of rosacea with severe ocular involvement in a child with acquired immunodeficiency syndrome.

II. Case Report

A 5 years old HIV-infected child; who had been receiving highly active antiretroviral therapy since birth; had a history of recurrent digestive infection and recurrent red eyes, that had been treated with a variety of topical agents, most recently with ciprofloxacin eye drop. He complained from the last week of painful foreign body sensation in the eyes, photophobia and tearing. His best corrected visual acuity was 2/10 in the right eye and 1/10 on the left. The slit lamp examination noted in both eyes a conjunctival hyperemia, keratitis with punctate epitheliopathy and multiple round corneal infiltrates, neovascular pannus (fig 1) and ulceration of the cornea (fig 2). The corneal sensitivity was conserved and the rest of the eye examination was within normal limits.

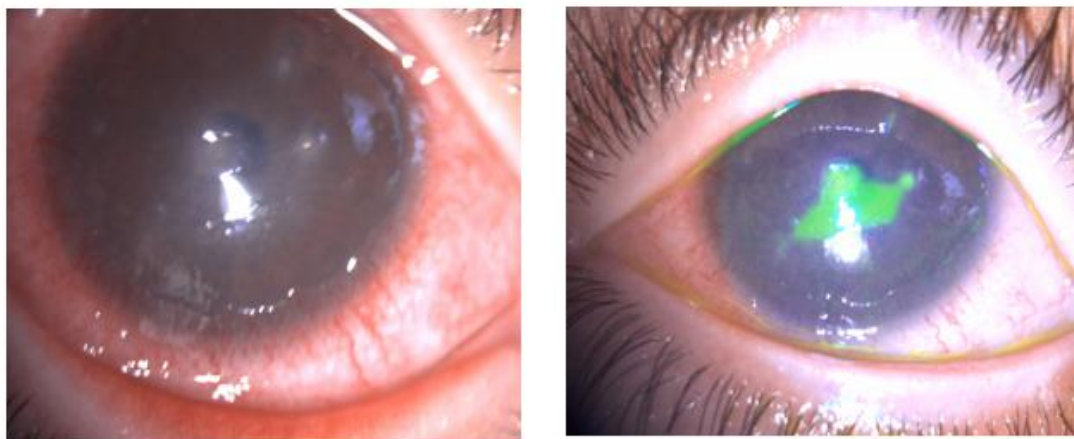


Fig.1 Keratoconjunctivitis with catarrhal infiltrates, conjunctival pannus and central corneal ulcer in the right eye

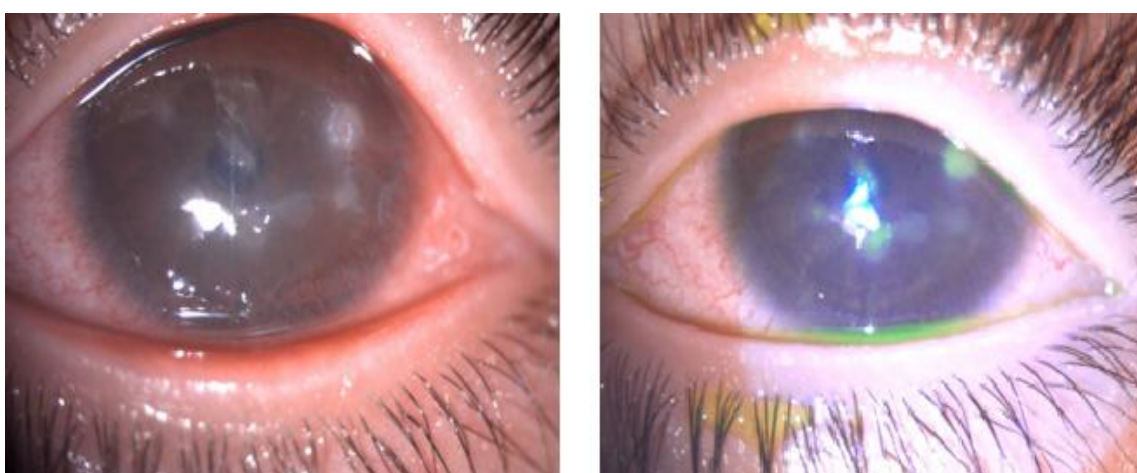


Fig.2 Keratoconjunctivitis with catarrhal infiltrates, conjunctival pannus with temporal neovascularization in the left eye

Because of the appearance of multiple abscesses, a corneal scrapping was done for bacteriological, mycological and parasitic study and a reinforced antibiotic eye drop (ceftazidime + vancomycin) was started. the result of the sampling was sterile and the evolution after 48 hours of treatment was unfavorable.

In front of the appearance of catarrhal infiltrates mimicking aseptic abscesses and after exclusion of herpes simplex virus infection, we made the diagnosis of isolated ocular rosacea, and we initiated a treatment with antibiotic and steroidal ointment (ciprofloxacin and dexamethasone), artificial tears and systemic medication by Josamicine 50 mg/kg/day.

The dermatological examination did not show signs in favor of a cutaneous rosacea.

the evolution , with a follow up of six months , was marked by the regression of the functional signs, a cicatrization of the corneal ulcers (fig 3) but a persistence of some catarrhal infiltrates (fig 4) , so we started a mild digression of local corticoids with maintains of artificial tears.

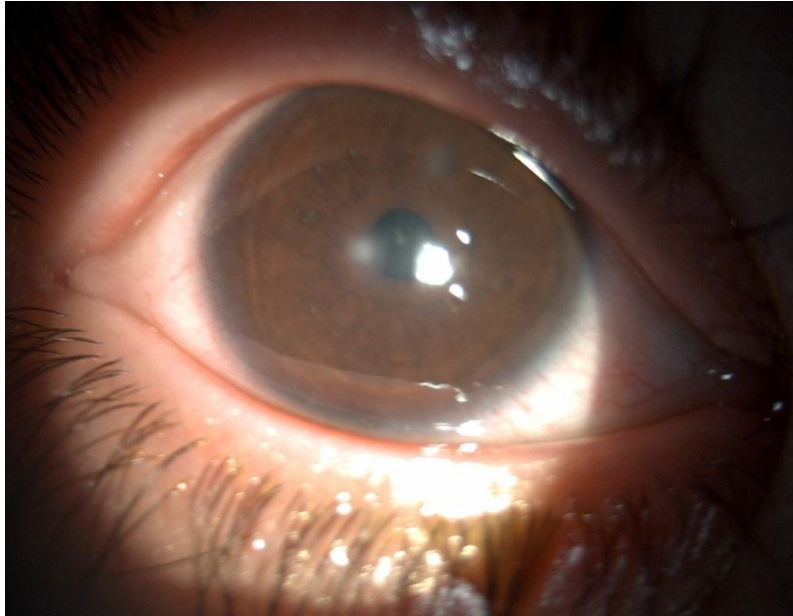


Fig.3 Cicatrization of the corneal ulcer with disappearance of the conjunctival pannus and persistence of some cicatricial infiltrates in the right eye

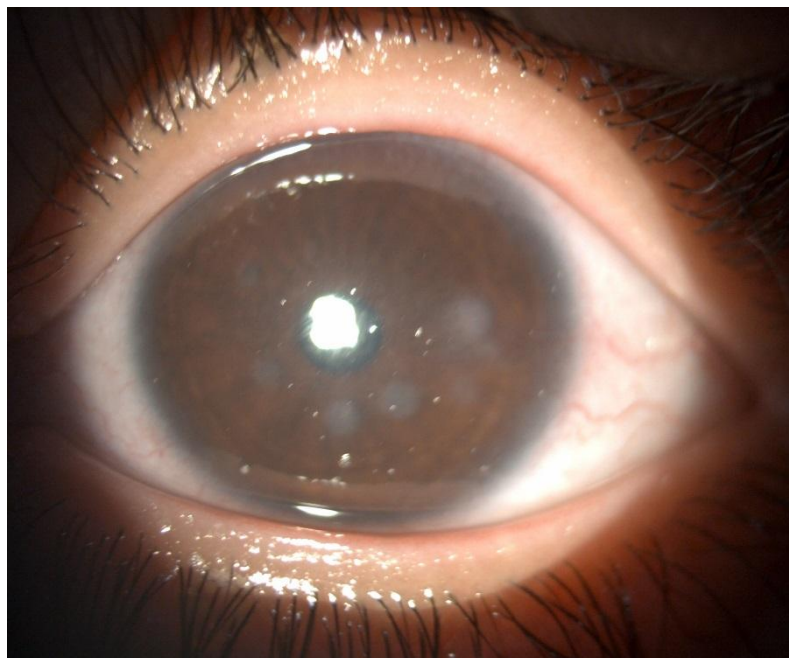


Fig.4Regression of conjunctival pannus and temporal neovascularization with persistence of some cicatricial infiltrates

III. Discussion

Ocular manifestations of pediatric rosacea are frequently underdiagnosed or misdiagnosed, leading to ophthalmologic complications (2-8). The reported prevalence of ocular involvement in rosacea varies from 30% to 50% in adults (5). In approximately 20% of these individuals, ocular complaints precede cutaneous finding (9). Ocular symptoms in childhood may be present, especially in girls with cutaneous rosacea, and are associated with significantly higher rate of complications than in adults (10). Ocular involvement includes blepharitis with meibomian gland inflammation and relapsing chalazia, ocular redness, photophobia, episcleritis or keratoconjunctivitis, and, in rare cases, corneal ulcers (8-11-12). The pathophysiologic mechanisms of rosacea remain unclear, but various factors have been implicated in both ocular and cutaneous rosacea, such as climatic exposures, vascular changes, matrix degeneration, pilosebaceous unit abnormalities or microbial organisms, and more recently, inflammatory mediators (1-4). In HIV positive children, rosacea manifestations may seem exaggerated (13). Multiple factors have been proposed to explain this reaction: First,

hyperimmunoglobulinemia is a constant feature in HIV infection (14), however, hypersensitive reactions have been described in gammaglobulinemia as well (15). Second, the T-cell receptor 2 lymphocyte cell population, with alpha and beta receptors, is mostly affected in HIV infection. Those cells express CD4 or CD8 on the surface and are the only cells able to develop immunological memory which is necessary to diminish reactions in repeated exposures by stimulating suppressor T cells in HIV infection TCR 1 cells which are nonregulating cells predominant (13). One may speculate that this group of patients did not have sufficient time or had lost the ability to develop the TCR2 memory cells (16).

The therapeutic approach in adults depends on the severity of symptoms. Treatment of mild ocular rosacea with blepharconjunctivitis should include regular lid and eye hygiene consisting of warm compresses, cleaning of the lid margin, and the use of lipid-containing artificial tears. Persistent blepharitis, corneal neovascularization, or marginal infiltration require topical antibiotics and at least 6 months of systemic anti-inflammatory antibiotic therapy. In patients with keratitis or scarring, steroid eye drops are important, and if anti-inflammatory maintenance therapy is necessary, topical cyclosporine A may be a useful alternative (7). Systemic antibiotics, primarily the tetracyclines, particularly doxycycline and minocycline, are the drugs of choice for most individuals with rosacea. Tetracyclines should not be used in children younger than 8 years, because they can lead to discoloration of teeth and susceptibility to fracture by incorporation into bones and teeth (7). In younger age, macrolides are the preferred agents (7). Azithromycin can produce marked improvement, even when administered for only 5 days (17). Chamaillard et al treated 10 children with ocular rosacea with metronidazole for 3 to 6 months, it has the same effect as tetracycline and produces longer lasting remissions (18).

IV. Conclusion

Cutaneous Rosacea is the most frequent presentation of childhood rosacea. If a diagnosis of cutaneous rosacea is suspected, an ophthalmologic follow up is necessary to detect ocular involvement and to prevent complications. The isolated ocular form is most probably underdiagnosed and it is a treatable affection which makes its recognition of a great importance.

References

- [1]. Wilkin J, Dahl M, Detmar M, et al. Standard classification of rosacea: report of the national rosacea society. Expert committee on the classification and staging of rosacea. *J Am Acad Dermatol.* 2002;46(4):584-587.
- [2]. Lacz NL, Schwartz RA. Rosacea in the pediatric population. *Cutis.* 2004;74(2):99-103.
- [3]. Bourrat E, Rybojad M, Deplus S, Morel P. Rosacea with ocular involvement in a child [in French]. *Ann Dermatol Venereol.* 1996;123(10):664-665.
- [4]. Buechner SA. Rosacea: an update. *Dermatology.* 2005;210(2):100-108.
- [5]. Stone DU, Chodosh J. Ocular rosacea : an update on pathogenesis and therapy. *Curr Opin Ophthalmol* 2004; 15:499-502.
- [6]. Hong E, Fischer G. Childhood ocular rosacea: considerations for diagnosis and treatment. *Australas J Dermatol* 2009; 50:272-275.
- [7]. Christiane P. B et al. Ophthalmic Rosacea: Case report in a child and treatment recommendations. *Pediatric dermatology* 2014; 1-4.
- [8]. Nazir SA, Murphy S, Siatkowski RM, Chodosh J, Siatkowski RL. Ocular rosacea in childhood. *Am J Ophthalmol.* 2004;137(1):138-144.
- [9]. Keshtcar-Jafari A, Akhyani M, Ehsani AH et al. Correlation of the severity of cutaneous rosacea with ocular rosacea. *Indian J Dermatol Venereol Leprol* 2009 ;75:405-406.
- [10]. Nazir SA, Murphy S, Siatkowski RM et al. Ocular rosacea in childhood. *Am J Ophthalmol* 2004; 137:138-144.
- [11]. Goldsmith AJB. The ocular manifestations of rosacea. *Br J Dermatol.* 1953;65(12):448-457.
- [12]. Kligman AM. Ocular rosacea: current concepts and therapy. *Arch Dermatol.* 1997; 133(1):89-90.
- [13]. Smith KJ, Skelton HG, Vogel P, Yeager J, Baxter D, Wegner KF : Exaggerated insect bite reactions in patients positive for HIV . *Jam Acad Dermatol* 1993, 29:269-272.
- [14]. Penneys NS, Nayer JK, Bernstein H Knight JK: Chronic pruritic eruption in patients with acquired immunodeficiency syndrome associated with increased antibody titers to mosquito salivary gland antigens. *J Am Acad Dermatol* 1989; 21:421-425.
- [15]. Shibasaki M, Sumazaki R, Takita H: Hypersensitive reactions to mosquito bites in congenital agammaglobulinemia. *Am Allergy* 1986; 56:81-84
- [16]. Barrio J, Ilerona M, Hernandez JM et al: Rosacea-Like demodicosis in an HIV-positive child. *Dermatology* 1996; 192:143-145. Donaldson KE, Karp CL, Dunbar MT:
- [17]. Evaluation and treatment of children with ocular rosacea. *Cornea* 2007; 26:42-46
- [18]. Chamaillard M, Mortemousque B, Boralevi F et al. Cutaneous and ocular signs of childhood rosacea. *Arch Dermatol* 2008; 144:167-171.

I.ER-RACHIQ, et. al. "Rare Case of an Ophthalmic Rosacea in a Child with Acquired Immunodeficiency Syndrome." *IOSR Journal of Nursing and Health Science (IOSR-JNHS)*, 9(6), 2020, pp. 48-51.