

Neuroendocrine Tumours of The Ampulla Of Vater

HejjaneLoubna¹, Benbrahim Zineb¹, Ahalli Ibtihal¹, Lhlou Mimi Anass²,
Dkhissi Yassine³, Efred Boubacar⁴, Oualla karima¹, Aarifi Samia¹,
Mellas Nawef¹.

¹Department of OncologyMedical, Hassan II UniversityHospital, Fez, Morocco.

²Department of Radiology, Hassan II UniversityHospital, Fez, Morocco.

³Department of Visceral surgery, Hassan II UniversityHospital, Fez, Morocco.

⁴Department of Pathology, Hassan II UniversityHospital, Fez,

Corresponding Author : HejjaneLoubna

Abstract

Background

Neuroendocrine tumors rarely occur in ampulla of Vater and their incidence in current increase, in particular malignant forms. The final diagnosis is done on histology, and sometimes it can be difficult to diagnose them preoperatively, as they present a clinical picture similar to the adenocarcinomas of this region.

Case presentation

Case 1

A 43-year-old woman with epigastric pain, serum alkaline phosphatase and γ -glutamine transferase high, endoscopic retrograde cholangiopancreatography (ERCP) showed choledochal metastasis on suspicious ampullary stenosis. Surgical exploration has demonstrated the presence of a mass of 4 cm at the expense of the ampulla of Vater. An ampullectomy was carried out, histological and immunological aspect was in favor of a well differentiated neuroendocrine carcinoma with expression of synaptophysin and chromogranin with a Ki 67 at 2%. The patient remained under good control with complete cure and without disease for 51 months.

Case 2

a 28-year-old female consultant for cholestatic jaundice associated with general asthenia, abdominal computed tomography-scanner (CT scan) has objectified a tissue lesional process of the vater bulb protruding into the duodenal lumen, a pancreaticoduodenectomy was performed, pathologic examination and immunohistochemistry of the surgical specimen was in favor of a well-differentiated neuroendocrine tumor with expression of synaptophysin, chromogranin A and CKAE1/AE3 with a Ki 67 at 2%. The patient remained under good control with complete recovery and no signs of illness 19 months after the surgical procedure.

Conclusions : Ampullary neuroendocrine tumors (ANETs) are distinct entities that present clinically with jaundice. They positively stain chromogranin A and synaptophysin immunohistochemistry. The Pancreaticoduodenal resection appears to be the procedure of choice for most patients with ANET because this procedure removes all the potential tumor-bearing tissue.

Keywords

Neuroendocrine carcinoma - Ampulla of Vater- pancreaticoduodenectomy – prognosis.

Date of Submission: 17-11-2018

Date of acceptance: 02-12-2018

I. Background

Neuroendocrine tumors of the ampulla of Vater are very rare, (Less than 100 published cases) [1, 2, 3]. In 2000, the World Health Organization revised the histopathological classification system for gastroenteropancreatic neuroendocrine tumors [4, 5]. The tumor neuroendocrine replaced the carcinoid term, which evokes a broader spectrum of appearance and of behavior histological and it is subdivided in two categories: benign, potentially malignant and malignant. They have a better prognosis than adenocarcinomas and good results have been reported for pancreaticoduodenectomy and local resection [2]. We report two new cases with ampullary neuroendocrine tumors and through the data of the literature we take stock of the various aspects of this rare entity.

II. Case presentation

Case 1

A 43-year-old woman followed for goiter, who presented 1 year before her admission chronic epigastric pain. Hepatic function tests showed marked elevations of alkaline phosphatase and γ -glutamine

transferase. The bili-Magnetic resonance imaging (bili-MRI) has objectified a choledochal enhancement. Endoscopic retrograde cholangiopancreatography (ERCP) showed choledochal metastasis on suspected ampullary stenosis. The duodenoscopy showed a polyploid rounded ampullar ulcer formation measuring 4 cm. An ampullectomy was carried out, the anatomopathological and immunohistochemical examination returned in favor of a well differentiated neuroendocrine carcinoma of 2.3 cm with expression of synaptophysin, chromogranin and CKAE1/AE3 with a Ki 67 at 2%, with tumor free margin. No adjuvant treatment was indicated. A thoraco-abdominopelvic CT scan was produced two months later objectified an aerobilie with persistence of the 10 mm dilatation of the main bile duct. The patient presented a complete recovery and disease-free recovery 51 months after the surgery.

Case 2

A 28-year-old woman presented 4 months before admission with a generalized asthenia associated with cholestatic jaundice, abdominal CT showed a tissue lesional process of the vater bulb protruding into the duodenal lumen with thickening of the inner wall of the D1, it measures 35x27 mm (Fig. 1). Histopathologic examination of the biopsy in favor of an interstitial duodenitis with calcification. A pancreaticoduodenectomy was performed (Fig. 3), the anatomopathological and immunohistochemical examination of the surgical specimen was in favor of a well differentiated neuroendocrine tumor of 2.7 cm with expression of synaptophysin, chromogranin A and CKAE1/AE3 with a Ki 67 at 3% (Figs 4 and 5). one of the twenty examined ganglions was involved. An abdominal computed tomography of control was performed 3 months later, which showed an infiltration of the operating area without mass or visible pathological contrast enhancement (Fig. 2). She remained disease free 19 months after surgery.

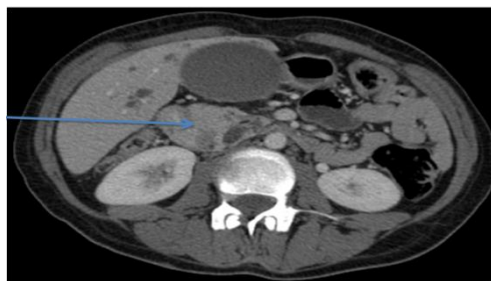

Figure 1: Scannographic axial sections showing a tissue process centred on the bulb of Vater enhanced after contrast, bending in the duodenal lumen with thickening of the internal wall of D1, it measures 35x27 mm

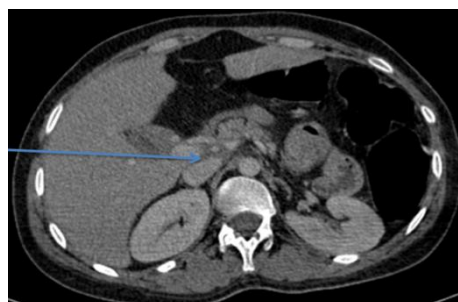

Figure 2: Scannographic axial sections showed an infiltration of the operating area without mass or visible pathological contrast enhancement

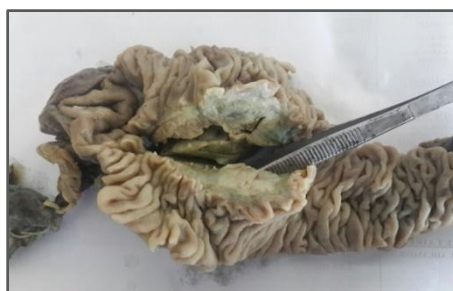

Figure 3: Macroscopic appearance of the CDP patch with a beige nodular ampullary tumor (forceps).

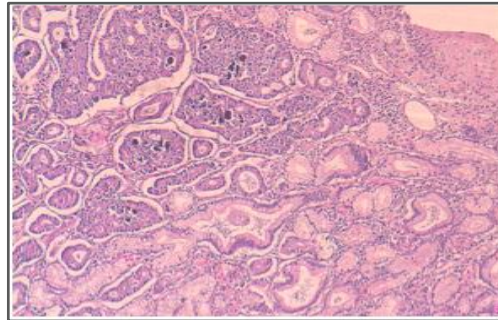


Figure 4: Morphological aspect showing tumor proliferation arranged in cribriform masses and pseudo-acinar structures centered in places by calcifications (HES x 40).

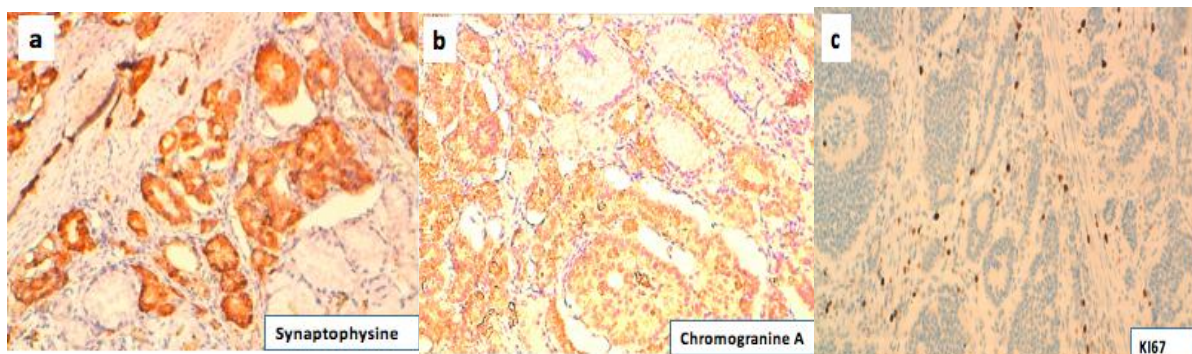


Figure 5 : (a) Immunohistochemistry showed Synaptophysin positivity in the tumor cells (x100 magnification). (b) Immunohistochemistry showed chromogranin positivity in the tumor cells (x200 magnification). (c) Immunohistochemistry showed tumor proliferation index estimated by Ki67 at 3% (x200 magnification).

III. Discussion

Neuroendocrine tumours of the ampulla of Vater are very rare gastrointestinal malignancy, they are less than 2% of tumours ampullary and less than 1% of the gastrointestinal tumours neuroendocrines. The World Health Organization (WHO) published in 2000 the latest classification which advocates distinguishing 3 categories: poorly differentiated endocrine carcinomas called small cell carcinomas, well-differentiated endocrine carcinomas called malignant carcinoids and well-differentiated endocrine tumors which are carcinoids [4]. The first two categories are considered to be malignant neoplasms, while well-differentiated endocrine tumors may have malignant or benign clinical signs. Our patients had well-differentiated endocrine carcinoma.

There is another method of classifying neuroendocrine tumors (NET) which is based on two criteria which are the presence of necrosis and mitotic activity. [6, 7] The well differentiated NETs, low-grade (G1) which reveal a lack of necrotic areas and less than 2 mitotic figures per 10 HPF. Neuroendocrine carcinoma moderately differentiated, intermediate grade (G2) that show the presence of necrotic foci or 2 to 20 mitotic figures per 10 HPF. While, the poorly differentiated neuroendocrine carcinomas, high Grade (G3) show the presence of necrotic foci and more than 20 mitotic figures per 10 HPF and [7].

The median age is 48.6 years and the sex ratio of women and men is 2.8: 1 based on data from 105 published cases in the literature. [8, 9, 10, 11, 12, 13, 14] The main symptom on the day of the consultation is Jaundice (60%), followed by pain (40%) and weight loss (10%). One of our patients presented with jaundice. Other signs may be observed such as acute pancreatitis in 3 to 6%, upper gastrointestinal bleeding in 3% [15, 16, 17]. The carcinoid syndrome is rare in patients with carcinoid of the ampulla of Vater without liver metastasis and this can be explained by made that the majority of the hormones produced by functional tumors are eliminated by the metabolism of the first passage in the portal system [18]. In 25.9% carcinoids of the ampulla of Vater are often associated with the von Recklinghausen disease [1,19]. Contrary to our 2 cases, the disease of von Recklinghausen was not associated.

Patients followed for carcinoid tumors of ampulla of Vater are different from those with carcinoid tumors of the jejunum and the ileum because they are in the majority of cases devoid of clinical and biological signs of the carcinoid syndrome. Symptoms of carcinoid syndrome such as flushing, asthma and diarrhea are described in only 2.8% (2 out of 71) of patients followed for papillary carcinoids.[1]Our patients have no symptoms of carcinoid syndrome.

The preoperative diagnosis of carcinoid tumors is only correct in 10 out of 71 patients that is 14% according to the data of the literature.[1]The diagnosis of carcinoid tumors is based on ERCP coupled with deep biopsies. The detection of lymph node metastases and the depth of invasion is essentially done by endoscopic

ultrasound. Once the diagnosis of ANET has been established, the demonstration of metastases is done by computed tomography and octreotidescintigraphy[20,1]. It should be noted that on imaging there are no specific features that can distinguish ANET from adenocarcinoma. In our cases the diagnosis was made by the biopsy of the ampoule.

Histologically, ANETs are small, solitary, polypoid and are covered with flattened mucosa. Microscopically the tumor is arranged in nests, microglandular, trabecular and rarely insular pattern. The tumor cells are small, uniform with scanty granular cytoplasm. The nuclei are regular, normochromic with scanty mitosis. The signs in favor of malignant behavior are vascular invasion, gross local invasion or metastasis[6, 21]. Immunohistochemical staining is the main diagnostic method for ANET, they stain positively with chromogranin A in 92% of cases and neuron-specific enolase, synaptophysin and cytokeratin in 100%. Somatostatin is found in 58 to 67% of cases. Serotonin is secreted in 17% of cases as well as CCK. Insulin will stain positive in 25% of tumors. However, 13% are negative for any hormonal staining[20].

One of the prognostic factors of perinampullary adenocarcinoma is tumor size. Unlike ANETs in size does not predict the metastatic potential. In a study, on patients with 2 cm ampullary NET, showed that the diagnosis of lymphoid node disease was positive in more than half of them. Metastases were present in 46% of tumors of 2 cm, in 50% of tumors of 1-2 cm and in 66% of tumors of 1 cm [22, 23]. Other cases reported by Makhlouf et Al [24] of two tumors measuring less than 2 cm demonstrate metastases, while a 5 cm tumor did not show any evidence of metastatic disease. The conclusion of these two reports is that ANET metastasize in approximately 50% of the time independently of the size of the tumor.

In general, non-angio-invasive tumors less than or equal to 1 cm with 2 or fewer mitoses per 10 high-power fields (HPF) are considered benign, whereas the others show a high risk of malignancy. [4] ANETs are not angio-invasive, they measure 1 cm and show up to two mitoses per 10 HPF. [25] Contrariwise, the spread of the neoplasm to the muscularis, with a high degree of mitotic activity (3 or more mitoses per 10 HPF) and a diameter of 2 cm are considered as risk factors for the occurrence of metastases. [26, 27, 28]

The treatment of ANET is controversial and there is no general rule regarding their optimal treatment, as they are very rare tumors with unpredictable biological behavior and prognosis [22]. As it has been shown that the relationship between tumor size and the presence of metastatic ganglion has not been clearly established and therefore pancreatoduodenectomy remains the treatment of choice for ANETs regardless of tumor size outside of metastasis at a distance [17, 29, 26]. Pancreaticoduodenectomy has been adopted in more than 50% of patients, according to a review of 105 reported cases of literature. [30] As has been described in the most recent series in which pancreaticoduodenectomy has often been adopted [17, 31]. Radical excision was performed in one of our patients in this report, with a well differentiated NET and she remained free of illness for 19 months after surgery.

Reduction surgery has an important place in large tumors and should be indicated for patients with hypersecreting tumors of hormones, even in cases of local or distant metastasis, as it has shown an improvement in survival rates of up to 80%. at 5 years old [21]. the main disadvantage of local ANET resection is that it is technically difficult and associated with significant morbidity [22, 32]. Therefore, it is primordial to avoid the risk of exposing patients to the risk of missing the resection of their metastatic lymph nodes, thus missing their cure by a reliable oncological surgery. In general, local excision is limited for tumors <2 cm, highly differentiated and slow-growing, and this for patients with high surgical risk and unable to tolerate further surgery. [16, 17]

The serum chromogranin A level is a tumor marker that reflects the tumor burden of NETs, and is a tool for detecting tumoral relapses, disease response to treatment, and progression. [33, 22, 34]

The most important prognostic factors that determine the survival of ANET are grade and distant metastases. Other features are incriminated but less important in long-term survival such as lymph node involvement, tumor size and resection margins. [6, 35] High-grade tumors show a 10-year survival rate of 15%, while low-grade NETs have a 5-year survival rate of 80% and a 10-year survival rate of 71%. [15, 33] Overall survival the resected ampullary NETs also vary according to the grade of the tumor, whose overall survival at 5 years of well-differentiated tumor patients is 90% and which decreases markedly for low-grade tumors. [6, 15, 35, 33]

NET of the ampulla of Vater are distinct entities that present clinically with jaundice. They positively stain chromogranin A and synaptophysin immunohistochemistry. ANETs without invasion and a diameter of less than 2 cm are considered a better prognosis tumor. Pancreatoduodenectomy should be the standard treatment for ANETs because of the poor accuracy of preoperative and intraoperative assessment of lymph node involvement and the high incidence of lymph node metastasis, even in small tumors smaller than 2 cm.

Abbreviations

ERCP: Endoscopic retrograde cholangiopancreatography.

CT scan: Computer tomography scanner.

ANET: Ampullary neuroendocrine tumor.

WHO : World Health Organization

Bili-MRI: Bili-Magnetic resonance imaging

NET: Neuroendocrine tumor.

Declarations

Acknowledgements

Not applicable.

Funding

The authors received no specific funding for this study.

Availability of data and materials

All data generated or analyzed during this study are included in this published article.

Authors' contributions

HL wrote the article ; AI, AM, LMA, DY, OK, EF, AS, and MN made critical assessment of the article; BZ supervised the work. All authors read and approved the final version of the manuscript.

Competing interests

The authors declare that they have no competing interests.

Consent for publication

Written informed consent was obtained from the patients for publication of this case report and any accompanying images. A copy of the written consent is available for review by the Editor-in-Chief of this journal.

Ethics approval and consent to participate

Not applicable.

Authors' information

Not applicable.

Email addresses :

Hejjane Loubna: Benbrahim Zineb

Ahali Ibtihal

Lahlou Mimi Anas

Dkhissi Yassine

Efared Boubacar

Ouallakarima

Aarifi Samia

Mellas Nawef

IV. References

- [1]. Hatzitheoklitos E, Buchler MW, Friess H, Poch B, Ebert M, Mohr W, et al. Carcinoid of the ampulla of Vater. Clinical characteristics and morphologic features. *Cancer* 1994;73:1580-8.
- [2]. Walton GF, Gibbs ER, Spencer GO, Laws HL. Carcinoid tumors of the ampulla of Vater. *Am Surg* 1997;63:302-4.
- [3]. Partensky C, Berger F, Owono P, Scoazec JY, Ponchon T, Lombard-Bohas C. Duodéno pancréatectomie céphalique pour tumeur endocrine de l'ampoule de Vater et de la petite caroncule. *Gastroenterol Clin Biol* 1999;23:832-6.
- [4]. Solcia EKG, Sobin LH. *Histological Typing of Endocrine Tumors*. Heidelberg, Germany: Springer; 2000.
- [5]. Klöppel G, Heitz PU, Capella C, Solcia E. Pathology and nomenclature of human gastrointestinal neuroendocrine (carcinoid) tumors and related lesions. *World J Surg*. 1996;20(2):132-141.
- [6]. Albores-Saavedra J, Hart A, Chablé-Montero F, Henson DE. Carcinoids and high-grade neuroendocrine carcinomas of the ampulla of Vater: a comparative analysis of 139 cases from the surveillance, epidemiology, and end results program—a population based study. *Arch Pathol Lab Med* 2010; 134:1692-6. [PMID: 21043824].
- [7]. Washington MK, Tang LH, Berlin J, Branton PA, Burgart LJ, Carter DK, Compton CC et al. Protocol for the examination of specimens from patients with neuroendocrine tumors (carcinoid tumors) of the small intestine and ampulla. *Arch Pathol Lab Med* 2010; 134:181-6. [PMID: 20121604]
- [8]. Ricci JL. Carcinoid of the ampulla of Vater. Local resection or pancreaticoduodenectomy. *Cancer* 1993;71:686-90.
- [9]. Makhlof HR, Burke AP, Sobin LH. Carcinoid tumors of the ampulla of Vater: A comparison with duodenal carcinoid tumors. *Cancer* 1999;85:1241-9.
- [10]. Bornstein-Quevedo L, Gamboa-Dominguez A. Carcinoid tumors of the duodenum and ampulla of Vater: A clinicomorphologic, immunohistochemical and cell kinetic comparison. *Hum Pathol* 2001;32:1252-6.
- [11]. Alex WR, Auerbach HE, Pezzi CM. Adenocarcinoid tumor of the ampulla of Vater. *Am Surg* 1998;64:355-9.
- [12]. Asbun HJ, Rossi RL, Munson JL. Local resection for ampullary tumors. Is there a place for it? *Arch Surg* 1993;128:515-20.
- [13]. Hardt PD, Doppl WE, Klor HU, Hinrichs B. A rare combination of pheochromocytoma and somatostatin-rich neuroendocrine tumor of Vater's papilla (carcinoid) in a patient with von Recklinghausen neurofibromatosis. *Z Gastroenterol* 1998;36:233-8.

- [14]. Karatzas G, Kouraklis G, Karayiannakis A, Patapis P, Givalos N, Kaperonis E. Ampullary carcinoid and jejunal stromal tumour associated with von Recklinghausen's disease presenting as gastrointestinal bleeding and jaundice. *Eur J Surg Oncol*2000;26:428-9.
- [15]. Jayant M, Punia R, Kaushik R, Sharma R, Sachdev A, Nadkarni NK, Attri A. Neuroendocrine tumors of the ampulla of Vater:presentation, pathology and prognosis. *JOP* 2012; 13:263-7. [PMID: 22572129].
- [16]. Karagiannis S, Eshagzaïy K, Duecker C, Feyerabend B, Mozdzanowski E, Faiss S. Endoscopicresectionwith the cap technique of a carcinoidtumor in the duodenal bulb. *Endoscopy*2009; 41(Suppl 2):E288-9. [PMID: 19899043]
- [17]. Carter JT, Grenert JP, Rubenstein L, Stewart L, Way LW. Neuroendocrine tumors of the ampulla of Vater:biologicalbehavior and surgical management. *Arch Surg*2009; 144:527-31. [PMID: 19528385].
- [18]. Andrew Ofosu, Michael Taccone, LaskhmiPotakamuri, Sanjay Jagannath. Ampullary Neuroendocrine Tumor: A Rare Cause of Recurrent Abdominal Pain. *Case Reports in ClinicalMedicine*. [DOI :10.4236/crcm.2014.33034].
- [19]. Van Basten JP, Van Hoek B, de Bruine A, Arends JW, Stockbrugger RW. Ampullarycarcinoid and neurofibromatosis : case report and review of the literature. *Neth J Med* 1994;44:202-6.
- [20]. Singhal, D., Vasdev, N., Soin, A., Gupta, S. and Nundy, S. (2006) DistinguishingbetweenPeriampullaryCarcinoid and Carcinomas—Is This Possible Preoperatively? *Indian Journal of Gastroenterology*, 25, 206-207. [Citation Time(s):3]
- [21]. Klimstra D, Modlin IR, Coppola D, Loyd R, Suster S. The pathologic classification of neuroendocrine tumors, A review of nomenclature, grading and staging systems. *Pancreas* 2010;39:707-12.
- [22]. Krishna SG, Lamps LW, Rego RF. Ampullarycarcinoid: diagnostic challenges and update on management. *Clin GastroenterolHepatol*2010; 8:e5-6. [PMID: 19643204]
- [23]. Hwang S, Lee SG, Lee YJ, Han DJ, Kim SC, Kwon SH, Ryu JH et al. Radical surgicalresection for carcinoidtumors of the ampulla. *J GastrointestSurg*2008; 12:713-7. [PMID: 17992565]
- [24]. Bosman, F., Carneiro, F., Hruban, R. and Theise, N. (2010) WHO Classification of Tumors of the Digestive System. IARC Press, Lyon. [Citation Time(s):2]
- [25]. Washington MK, Tang LH, Berlin J, Branton PA, Burgart LJ, Carter DK, Compton CC et al. Protocol for the examination of specimensfrom patients with neuroendocrine tumors (carcinoidtumors) of the small intestine and ampulla. *Arch PatholLab Med* 2010; 134:181-6. [PMID: 20121604]
- [26]. Poultsides GA, Frederick WA. Carcinoid of the ampulla of Vater:morphologicfeatures and clinical implications. *World J Gastroenterol*2006; 12:7058-60. [PMID: 17109507]
- [27]. Watanabe Y, Yamada D, Ogawa Y, Fujino M, Kobayashi K, Ryu S, Tanaka M. Long-termsurvival of a patient with neuroendocrine carcinoma of the ampulla of Vater withlymphnodemicrometastasis. *Am Surg*2013; 79:E199-201. [PMID: 23635569]
- [28]. Beggs RE, Kelly ME, Eltayeb O, Crotty P, McDermott R, Ridgway PF. Large cell neuroendocrine carcinoma of the ampulla of Vater. *JOP* 2012; 13:470-5. [PMID: 22964952].
- [29]. Norton, J.A.,Kivlen, M., Li, M., Schneider, D., Chuter, T. and Jensen, R.T. (2003) Morbidity and Mortality of AggressiveResection in Patients with Advanced Neuroendocrine Tumors. *Archives of Surgery*, 138, 859-866. <http://dx.doi.org/10.1001/archsurg.138.8.859> [Citation Time(s):1]
- [30]. Hartel M, Wente MN, Sido B, Friess H, Buchler MW. Carcinoid of the ampulla of Vater. *J GastroenterolHepatol*. 2005;20(5):676–681. doi: 10.1111/j.1440-1746.2005.03744.x. [PubMed] [Cross Ref]
- [31]. Kim J, Lee WJ, Lee SH, Lee KB, Ryu JK, Kim YT, et al. Clinicalfeatures of 20 patients withcurativelyresectedbiliary neuroendocrine tumours. *DigLiver Dis*. 2011;43(12):965–970. doi: 10.1016/j.dld.2011.07.010. [PubMed] [Cross Ref]
- [32]. Senda E, Fujimoto K, Ohnishi K, Higashida A, Ashida C, Okutani T, Sakano S et al. Minute ampullarycarcinoidtumorwithlymphnodemetastases: a case report and review of literature. *World J SurgOncol*2009; 7:9. [PMID: 19159493].
- [33]. Dumitrascu T, Dima S, Herlea V, Tomulescu V, Ionescu M, Popescu I. Neuroendocrine tumours of the ampulla of Vater:clincopathologicalfeatures, surgicalapproach and assessment of prognosis. *Langenbecks Arch Surg*2012; 397:933-43. [PMID: 21215338].
- [34]. Yao JC, Hassan M, Phan A, Dagohoy C, Leary C, Mares JE, Abdalla EK et al. One hundredyearsafter "carcinoid":epidemiology of and prognosticfactors for neuroendocrine tumors in 35, 825 cases in the United States. *J Clin Oncol*2008; 26:3063-72. [PMID: 18565894].
- [35]. Selvakumar E, Rajendran S, Balachandar TG, Kannan DG, Jeswanth S, Ravichandran P, Surendran R. Neuroendocrine carcinoma of the ampulla of Vater: a clinicopathologicévaluation. *HepatobiliaryPancreat Dis Int* 2008; 7:422-5. [PMID: 18693180].

HejjaneLoubna. “ Neuroendocrine Tumours of The Ampulla Of Vater“ *IOSR Journal of Nursing and Health Science (IOSR-JNHS)* , vol. 7, no.6 , 2018, pp. 50-55.