

Osteoarthritis Hip In A Case Of Alkaptonuria

Dr.Maunil Jadav,Dr Nitin Chaudhari,Dr Dixit Patel

Abstract

Alkaptonuria is a rare disorder of tyrosine metabolism, characterized by the excretion of homogentisic acid with urine, which causes darkening when exposed to air and the deposition in certain tissues, especially in joint cartilage. Ochronosis or ochronotic arthropathy, first described by Virchow in 1866,1 demonstrates a rare expression of alkaptonuria. In our case report we report a case of 71 year old male patient with osteoarthritis of right hip who was treated with right total hip replacement during which we had found severe osteoarthritis with blackish discolouration of femoral head,acetabular cavity and surrounding tendons and tissue. Patient was diagnosed with alkaptonuria based on clinical and laboratory investigations

Date of submission: 06-04-2024

Date of acceptance: 16-04-2024

I. Background

Alkaptonuria is an extremely rare metabolic disease and is defined as an autosomal recessive inherited deficiency of the hepatic enzyme oxidase of the homogentisic acid^{1,2} (Figure 1). Deficiency of the enzyme causes accumulation of the homogentisic acid in the cells and the body fluids. The disease is characterized by the following three specific conditions, excretion of homogentisic acid in the urine, arthritis and ochronosis. Homogentisic acid accumulates and is polymerized into a blue-black pigment that is ultimately deposited in the skin, cartilage and collagenous tissues. Specifically, pigment deposition can be seen in skin, bones, articular cartilages, ear and sclera, heart endocardium and valves, and kidneys (the so called ochronosis).³ The accumulation eventually causes severe degeneration of the spine and peripheral joints, like knees, hips and shoulders.

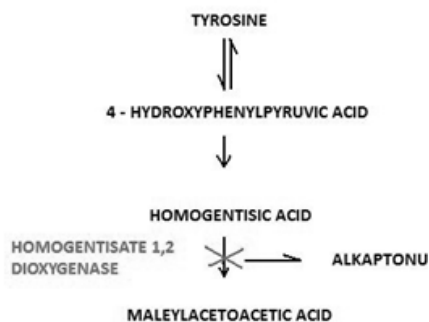


Figure 1 The catabolic path of tyrosine. Deficiency of the hepatic enzyme oxidase of the homogentisic acid causes alkaptonuria due to the accumulation of homogentisic acid.

II. Case Presentation

In our case a 71 year old male who presented to our out patient department with complain of persistant right hip pain with difficulty in walking at sleeping, patient did not suffer from any chronic disease and was not on any medication on regular basis.

On clinical examination patient had severe pain on flexion,extension internal rotation and external rotation of hip. Patient also had bilateral lower limb edema for which USG guided Doppler study of right lower limb was advised which was suggestive of bilateral lower limb stasis and multiple perforator incompetence. Patient was then subjected to radiological investigation which revealed severe osteoarthritis of right hip.

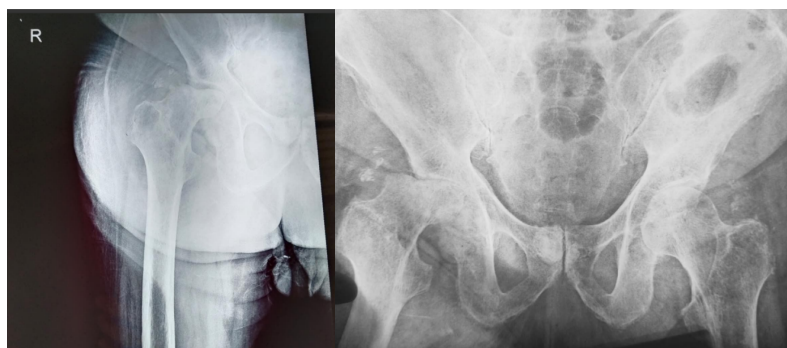


Figure 2: Radiographs suggestive of right side osteoarthritis of hip

Patient was then after primary investigations posted for right sided total hip arthroplasty, during the surgical approach we observed dark pigmentation of synovium, femoral head, acetabular cavity and tendons inserting over the greater trochanter of femur. We performed a right total hip replacement and sent the soft tissue and femoral head for histological examination.

Patient's urine homogentisic acid test was positive. Histological and laboratory diagnosis confirmed the diagnosis of ochronotic arthropathy/ Alkaptonuria.

On general overview of patient, patient had blackish pigmentation of sclera and blackish pigmentation of skin over hand and foot.

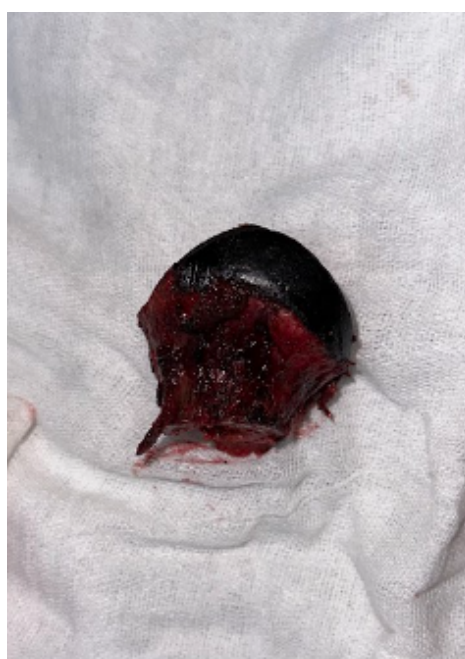

Figure 3: Blackish discolouration of femoral head

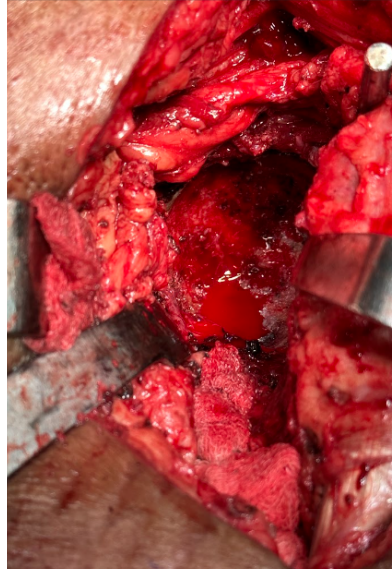


Figure 4: Black discolouration of acetabular cavity

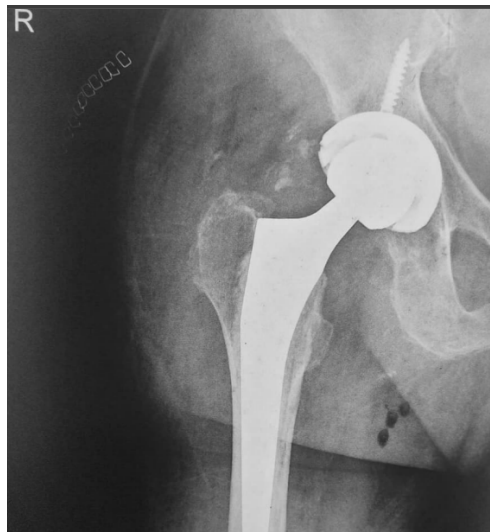

Figure 5: post operative xray



Figure 6: Black pigmentation of face and sclera

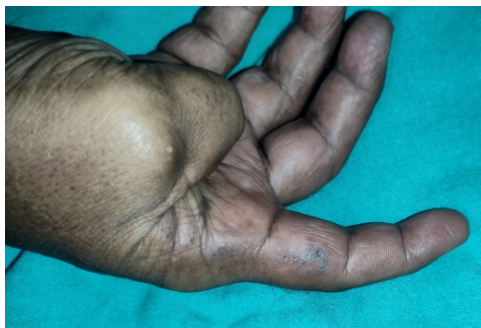

Figure 7: Black pigmentation over hand

III. Outcome And Follow-Up

Patients post operative period was uneventful and was started on physiotherapy and The patient walks normally and without the help of crutches, performs complete flexion and extension of the knees and complete movements of the right hip not accompanied by pain during the flexion, internal and external rotation. Comparison of the length of the two extremities showed no difference, the patient did not mention any pain in daily life activities

IV. Discussion

The ochronotic arthropathy is a common expression of alkaptonuria, an extremely rare metabolic disease, defined as an autosomal recessive inherited deficiency of the hepatic enzyme ‘oxidase of the homogentistic acid’. Patients with alkaptonuria are usually free of symptoms in childhood and adolescence, however the hyper pigmentation of the urine can be observed even in childhood. A percentage of 25% do not present dark hue of the urine and, thus, many patients with ochronosis remain undiagnosed until adulthood. The insufficiency of sucrose – isomaltase as well as the neonatal hyperparathyroidism can be inherited together with alkaptonuria. Ochronosis can be exogenous, induced by several harmful substances such as phenol, trinitrophenol, benzene and hydroquinone. In exogenous ochronosis the arthropathy observed in alkaptonuria is absent.

Ochronotic arthropathy appears usually during the third or fourth decade of life and is more severe in males. It has been suggested that clinical manifestations of alkaptonuric ochronosis are usually delayed, not appearing until the fourth decade of life because with ageing the renal clearance of homogentistic acid decreases.¹⁴ Mild and extremely rare, extensive ochronotic arthropathy has been reported in children. The most frequent manifestations of the disease are diffuse calcification of the intervertebral disk followed by narrowing of the intervertebral space and specific type of arthropathy of the axial skeleton and the peripheral joints. Peripheral arthritis is observed in almost all patients, as they grow in age. It first appears in knees, hips, shoulders, seldom in small joints of hands, and it is manifested by pain, limited morbidity and hydrarthrosis. Bibliography mentions appearance of intervertebral disc herniation as well as spontaneous tendon rupture both as first manifestations of the disease.

Apart from the musculoskeletal system, alkaptonuria affects other systems, such as cardiovascular, by secondary calcification of the aortic valve, being probably so severe that requires urgent replacement of the aortic valve, aortic stenosis and ischemic heart disease, leading to myocardial infarction. Nevertheless, there are references mentioning attack of the urinary system with the presence of swelling and calculus of the prostate, nephrolithiasis, renal failure, usually in late stages, as well as attack of the respiratory system with the appearance of throat dryness, dysphagia and dyspnea.

Until now, no specific therapy has been found. The recommended therapy is the reduction of the intake of phenylalanine and tyrosine and the increase of the intake of ascorbic acid, without strong clinical evidence. The destruction of the cartilaginous joint surfaces is extensive and appears at a young age, so that the patient requires a total arthroplasty before the age of 60. The total arthroplasty constitutes the unique solution to improve the quality of life for those patients.

Total joint replacement in published cases of ochronotic osteoarthritis report good results similar to osteoarthritic patients without ochronosis. Because all these are reports, no guideline is available for replacement of the knee or hip joints in ochronotic patient. In our review of the world literature we found very few studies upon the subject of early loosening of the arthroplasty in patients with ochronotic arthropathy. Spencer et al.²⁸ reported that they met no complication following arthroplasty on 11 joints of 3 patients diagnosed with osteoarthritis attributable to ochronosis. They reported no implant deficiency including total hip arthroplasty or any problem in 12 years follow up period. As in the whole spectrum of the metabolic bone

diseases, the potential of early failure of the arthroplasty is increased. In our research in the literature, we found no reports mentioning cases of revision of knee and hip arthroplasty.

Konttinen et al.31	1989	58 / M	Bilateral Knees	Cement less	---	Good
Carrier and Harris32	1990	70/m	Bilateral Knees and Hips	----	---	Improvement
Ramsperger et al.33	1994	57/M	Left Knee	---	---	---
Aydogdou et al.34	2000	48/M	Left Knee	Cement less	4 Years	Good
Demir35	2003	70/M	Bilateral Knees	Cemented	14 Months	Good
Moslovac et al.36	2003	70/M	Bilateral Knees and Hip	Cemented	7 Years	Excellent
Fisher and Davis37	2004	69/M	Bilateral Knees and Hip	---	5 Years	Improvement
Spencer et al.38	2004	53/F	Knee	---	7 Years	Good
Kotela et al.39	2008	59/M	Bilateral Knees	Cemented	---	Good
Kefeli et al.40	2008	60/F	Bilateral Knees	Cemented	10 Months	Good
Araki et al.41	2009	56/M	Bilateral Knees	Cement less	---	Good
Babak Siavashi et al.42	2009	54/F	Right Hip	Cemented	---	---
Fontao - Fernandez et al.43	2010	68/F	Left Knee	---	---	Good
Abimbola et al.44	2011	48/M	Left Knee	Cemented	2 Years	Excellent
Varvitsiotis et al.45	2014	53/M	Bilateral Shoulder	---	6 Years	Good
A.Malakasi et al.46	2012	77/M	Right Knee	Cemented	---	Good

Mehmet Ali Acar et al.47	2013	62/F	Right Hip and Left Knee	Cemented hip and cement less knee	18 Months	Good
Ramadan et al.48	2013	69/M	Bilatera l Knees	Cemented	1 year	Excellent

References

- [1] Garrod Ae. The Incidence Of Alkaptonuria: A Study In Chemical Individuality. *Lancet*. 1902;2(3):274–282.
- [2] Siavashi B, Zehtab Mj, Pendar E. Ochronosis Of Hip Joint; A Case Report. *Cases J*. 2009;2:9337.
- [3] O'brien Wm, La Du Bn, Bunim Jj. Biochemical, Pathologic And Clinical Aspects Of Alkaptonuria, Ochronosis And Ochronotic Arthropathy: A Review Of World Literature (1584–1962). *Am J Med*. 1963;34(6):813–838.
- [4] Milch Ra. Studies Of Alkaptonuria: Inheritance Of 47 Cases In Eight Highly Inter–Related Dominican Kindreds. *Am J Hum Genet*. 1960;12(1):76–85.
- [5] Harrold Aj. Alkaptonuric Arthritis. *J Bone Joint Surg Br*. 1956;38–B(2):532–538.
- [6] Fisher Aa. Exogenous Ochronosis From Hydroquinone Bleaching Cream. *Cutis*. 1998;62(1):11–12.
- [7] Cooper Pa. Alkaptonuria With Ochronosis. *Proc R Soc Med*. 1951;44(11):917.
- [8] Bunim Jj, Mcguire Js, Hilbish Tf, Et Al. Alkaptonuria, Clinical Staff Conference At The National Institutes Of Health. *Ann Intern Med*. 1957;47(6):1210–1224.
- [9] Minno Am, Rogers Ja. Ochronosis: Report Of A Case. *Ann Intern Med*. 1957;46(1):179–183.
- [10] Fisher Aa, Davis Mw. Alkaptonuric Ochronosis With Aortic Valve And Joint Replacements And Femoral Fracture: A Case Report And Literature Review. *Clin Med Res*. 2004;2(4):209–215.
- [11] O'brien Wm, Banfield Wg, Sokoloff L. Studies On The Pathogenesis Of Ochronotic Arthropathy. *Arthritis Rheum*. 1961;4:137–152.
- [12] Xu H, Wang J, Chen F, Et Al. Ochronotic Arthritis Of Bilateral Knees: A Case Report. *Int J Clin Exp Med*. 2015;8(5):8185–8189.
- [13] Reddy Dr, Prasad Vs. Alkaptonuria Presenting Lumbar Disc Prolapse: Case Report And Review Of Literature. *Spinal Cord*. 1998;36(7):523–524.
- [14] Venkateshan Vs, Chandra B, Graziano V, Et Al. Alkaptonuria And Renal Failure: A Case Report And Review Of The Literature. *Mod Pathol*. 1992;5(4):464–471.
- [15] Kazancioglu R, Taylan I, Aksak F, Et Al. Alkaptonuria And Renal Failure: A Case Report. *J Nephrol*. 2004;17(3):441–445.
- [16] Smith R. Disorders Of The Skeleton: The Oxford Textbook Of Medicine. In: Weatherall Et Al. (Eds.), Oxford University Press, Lincoln, Uk. 1996;Pp.3085–3086.
- [17] Ozmanevra R, Güran O, Karatosun V, Et Al. Total Knee Arthroplasty In Ochronosis: A Case Report And Critical Review Of The Literature. *Ekleml Hastalik Cerrahisi*. 2013;24(3):169–172.
- [18] Spencer Jm, Gibbons Cl, Sharp Rj, Et Al. Arthroplasty For Ochronotic Arthritis: No Failure Of 11 Replacements In 3 Patients Followed Up 6–12 Years. *Acta Orthop Scand*. 2004;75(3):335–338.
- [19] Kefeli M, Tomak Y, Can B, Et Al. Arthroplasty For The Treatment Of Joint Degeneration Caused By Ochronosis In Two Cases. *Acta Orthop Traumatol Turc*. 2008;42(2):139–144.
- [20] Yilmaz A, Egilmez E. Knee Arthroplasty For Ochronotic Arthropathy. *J Knee Surg*. 2002;15(4):231–232.
- [21] Fisher Aa, Davis Mw. Alkaptonuric Ochronosis With Aortic Valve And Joint Replacements And Femoral Fracture: A Case Report And Literature Review. *Clin Med Res*. 2004;2(4):209–215.
- [22] Kontinen Yt, Hoikka V, Landtman M, Et Al. Ochronosis: A Report Of A Case And A Review Of Literature. *Clin Exp Rheumatol*. 1989;7(4):435–444.
- [23] Carrier Da, Harris Cm. Bilateral Hip And Bilateral Knee Arthroplasties In A Patient With Ochronotic Arthropathy. *Orthop Rev*. 1990;19(11):1005–1009.
- [24] Ramsperger R, Lubinus P, Lubinus Hh. Alkaptonuria And Ochronotic Arthropathy. Arthroscopic And Intraoperative Findings In Implantation Of A Knee Joint Surface Replacing Prosthesis. *Chirurg*. 1994;65(11):1061–1065.
- [25] Aydođdu S, Cullu E, Ozsoy Mh, Et Al. Cementless Total Knee Arthroplasty In Ochronotic Arthropathy: A Case Report With A 4–Year Follow–Up. *J Arthroplasty*. 2000;15(4):539–543.
- [26] Demir S. Alkaptonuric Ochronosis: A Case With Multiple Joint Replacement Arthroplasties. *Clin Rheumatol*. 2003;22(6):437–439.
- [27] Moslavac A, Moslavac S, Cop R. Case Report Of A Patient With Ochronosis And Arthroplasty Of The Hip And Both Knees. *Reumatizam*. 2003;50(1):26–28.
- [28] Fisher Aa, Davis Mw. Alkaptonuric Ochronosis With Aortic Valve And Joint Replacements And Femoral Fracture: A Case Report And Literature Review. *Clin Med Res*. 2004;2(4):209–215.
- [29] Kotela A, Pirko K, Kotela I. Ochronosis As A Cause Of Multiple Joint Osteoarthritis In One Patient. *Przegł Lek*. 2010;67(5):427–431.
- [30] Kefeli M, Tomak Y, Can B, Et Al. Arthroplasty For The Treatment Of Joint Degeneration Caused By Ochronosis In Two Cases. *Acta Orthop Traumatol Turc*. 2008;42(2):139–144.
- [31] Araki K, Sudo A, Hasegawa M, Et Al. Devastating Ochronotic Arthropathy With Successful Bilateral Hip And Knee Arthroplasties. *J Clin Rheumatol*. 2009;15(3):138–140.
- [32] Siavashi B, Zehtab Mj, Pendar E. Ochronosis Of Hip Joint; A Case Report. *Cases J*. 2009;2:9337.
- [33] Fontao–Fernández L, Ferreirós–Conde Mj, Otero–Villar J. Ochronotic Arthropathy: A Presentation Of 2 Cases. *Rev Esp Cir Ortop Traumatol*. 2010;54(6):396–398.
- [34] Abimbola O, Hall G, Zuckerman Jd. Degenerative Arthritis Of The Knee Secondary To Ochronosis. *Bull Nyu Hosp Jt Dis*. 2011;69(4):331–334.
- [35] Dimitrios V, Emmanouil D, Christoforos T, Et Al. Patient Suffering From Ochronotic Arthropathy Treated With Bilateral Total Shoulder Arthroplasty. Presentation Of This Case Report With 6 Years Follow Up. *Acta Orthopædica Hellenica*. 2014;65(1):33–36.

- [36] Malakasi I, Skagias I, Vrasami I, Et Al. Total Knee Arthroplasty In A Patient With Ochronotic Arthritis. Case Report And Review Of The Literature. Scientific Chronicles. 2012;17(2):98–99.
- [37] Acar Ma, Erkocak Of, Aydin Bk, Et Al. Patients With Black Hip And Black Knee Due To Ochronotic Arthropathy: Case Report And Review Of Literature. Oman Medical J. 2013;28(6):448–449.
- [38] Ozmanevra R, Güran O, Karatosun V, Et Al. Total Knee Arthroplasty In Ochronosis: A Case Report And Critical Review Of The Literature. Eklem Hastalık Cerrahisi. 2013;24(3):169–172.