

# Kartagener's Syndrome: A Nursing Case Presentation

\*Renuga Devi,

M.Sc (N)

<sup>1</sup>Fatima College of Health Sciences, Al Ain, Abu Dhabi, United Arab Emirates

---

## ABSTRACT

Kartagener's syndrome (KS) is a rare hereditary disease which is also known as Kartagener Afzelius syndrome. It is caused by mutations in many different genes that are inherited in an autosomal recessive manner<sup>5</sup>. It is a subset of Primary Ciliary Defect (PCD), formerly known as immotile cilia syndrome. The clinical triad of KS includes situs inversus, sinusitis and bronchiectasis<sup>8</sup>. Usually diagnosed with history, physical examination, laboratory and radiological investigations. Management of KS is as per the presentation of the symptoms. The recently used trend of management is the airway clearance therapy or pulmonary hygiene in order to maintain a patent airway.

**Keywords:** Kartagener syndrome(KS), Primary Ciliary Defect (PCD), Situs Inversus (SI), Bronchiectasis, Sinusitis

---

Date of Submission: 25-04-2023

Date of Acceptance: 07-05-2023

---

## I. INTRODUCTION

Kartagener's syndrome is a congenital syndrome consists of a clinical triad which was discovered by Manes Kartagener, a Zurich pulmonologist in 1933. However Siewert described it earlier in 1904<sup>2</sup>. Later in 1970's Bjorn Afzelius, a cell biologist investigated a rare case of me with immotile spermatozoa and identified it to be in connection with the KS<sup>2</sup>.

It is a rare autosomal recessive hereditary disease affecting majorly the respiratory system with bronchiectasis due to ciliary immotility<sup>10</sup>. According to the Indian Journal of Human genetics it is estimated that 1 in 30,000 people are born with KS.the prevalence of PCD is 1 in 12,000 to 60,000. Majority of male gender with KS are infertile due to various ultrastructural defects in sperm tail<sup>8</sup>.

## II. DEFINITION

KS is a subset of PCD, characterized by abnormal ciliary structure or function leading to impaired mucociliary clearance<sup>8</sup>. Situs Inversus is another triad of KS but it does not cause any symptoms in itself

- Situs inversus totalis
- Situs inversus abdominalis
- Situs inversus thoracalis


## III. ETIOLOGY

No gender predilection is recognized. DNA 11 and DNA H5 which encode the components of outer dynein arm in cilia are the two most common genes leading to PCD<sup>5</sup>. Two other rare X linked genes are RPGR & OFD1 have also been identified.

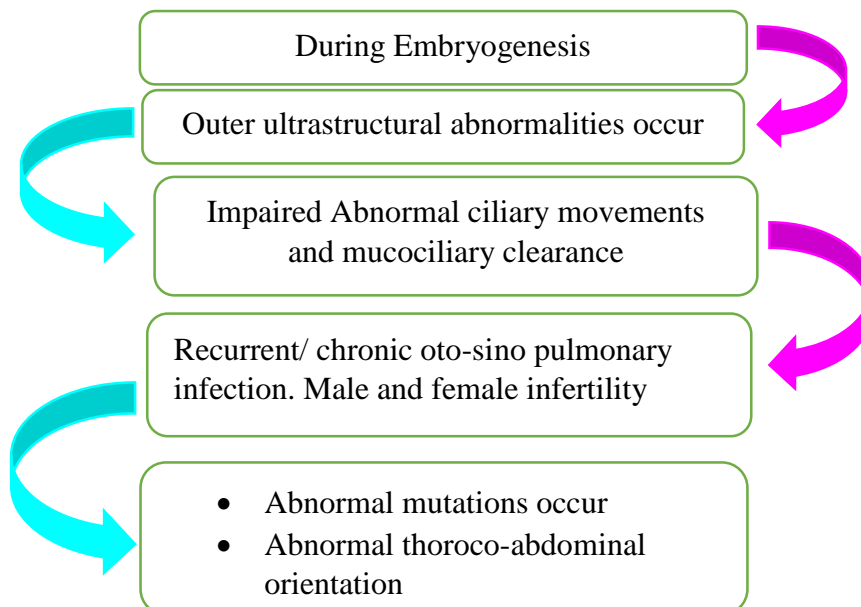
#### IV. PATHOPHYSIOLOGY

Almost 50% of PCD population acquire SI, since normal ciliary movement is essential for visceral rotation<sup>6</sup>.

##### *In Primary Ciliary Defect:*



##### *In Situs Inversus:*



#### V. CLINICAL MANIFESTATIONS

It consists of a clinical triad<sup>4</sup>

- Chronic sinusitis
- Bronchiectasis
- Situs Inversus
- Telecanthus - widened pupillary distance due to a nasal polyp<sup>1</sup>
- Infertility in males and sub-fertility in females
- Ectopic pregnancy due to abnormal fallopian tube transit of oocytes<sup>9</sup>
- Frequent ear infections leading to hearing loss
- Clubbing

##### *In Neonates*

- ✚ Respiratory distress
- Four main features are
  - Unexplained neonatal distress

- Early onset year round wet cough
- Nasal congestion
- Laterality defects

## VI. DIAGNOSTIC TESTS

KS is typically suspected based on its symptoms.

Diagnosis is achieved with a combination of clinical features in conjunction with testing.

### **History:**

This indicates that the patient has chronic and recurrent infections.

### **Physical Examination:**

The findings varies as per the presentation of symptoms.

The physician may evaluate for signs of

- Nasal polyps
- Reduced sense of smell
- Hearing loss
- Clubbed fingers and toes due to hypoxemia

### **In newborns**

Unlike other respiratory distress, this occurs after 12-24 hours of birth in term infants.

If any 3 features out of the four main features are present then 96% of the OCD is to be confirmed.

#### 1. Nasal or bronchial brush biopsy

Under an electron microscope it reveals abnormal ciliary ultrastructure and motility.

#### 2. Nasal Nitric oxide measurements<sup>11</sup> (Breathing test)

Usually the paranasal sinus epithelium produces nitric oxide. But for PCD patients it is less than 100 nl/min

- Done for the age above 5 years<sup>3</sup>
- It is a sensitive and specific test for PCD

The values can be altered even during viral respiratory infections and cystic fibrosis so the patient must be fully recovered from infections before analyzing for PCD.

#### 3. High speed video microscopy<sup>3</sup>

Used to analyze ciliary motility

#### 4. Genetic testing

#### 5. Semen analysis shows structural abnormality and low motility.

#### 6. X-ray chest PA view reveals

- Paranasitis
- Bronchiectasis- bronchial wall thickening and bronchial dilatation
- Finger in glove sign – mucus plug is visible
- Situs inversus- cardiac apex and aortic arch on the right side

#### 7. CT chest reveals<sup>1</sup>

- Severity of bronchiectasis but milder than cystic fibrosis
- Consolidation
- Mucocele
- Tree in bud pattern/ centrilobular nodules
- Mosaic perfusion/air trapping
- Eventual scarring
- Bronchial arterial enlargement

#### 8. 2D ECHO

- Consistent with dextrocardia

#### 9. Ultrasound reveals presence of liver, spleen and gall bladder in left side

10. ECG – normal on right sided chest leads

11. Hematological and biochemical parameters – semen analysis shows oligospermia with immotile live sperms

12. Doppler – transposition of aorta and IVC

## **VII. TREATMENT**

There is no known cure. Symptom based treatment is followed.

### **Goals:**

Mainly to lower the risk of complication.

- Long term low dose antibiotics either inhaled or oral<sup>11</sup>
- Immunization- influenza and pneumococcal<sup>5</sup>
- Inhaled corticosteroids
- Pulmonary hygiene/Airway clearance therapy – Bronchoscopy and tracheotomy to suction out the mucus.
- Recombinant DNA's<sup>12</sup>
- Bronchodilators and mucolytics
- Chest physiotherapy
- FESS- functional endoscopic sinus surgery<sup>12</sup>
- Tympanoplasty – for chronic ear infections
- Lung transplant<sup>7</sup>

Taina and associates found it to be effective in a 25yr old man<sup>9</sup>.

## **VIII. COMPLICATIONS**

Varied as per the involvement of organs

- Hearing loss
- Respiratory failure
- Chronic infections
- Infertility

## **IX. NURSING MANAGEMENT**

The nursing management of a patient with KS is discussed using a case report.

Mrs. A, a 43 year old non-smoker female came with the complaints of productive cough, rhinorrhea and shortness of breath for last 25 years with episodic fever and worsened symptoms. She has been married for the past 20 years but had no children. She had been previously treated with antibiotics, bronchodilators and inhaled corticosteroids for past 12 years. She has relapse in medication intake. She was also treated with anti-tubercular drugs before 15 years, but showed no relief. Her past history reveals recurrent chest infections since childhood. She verbalizes of taking homeopathy medications 20 years back. Her family history reveals no consanguinity. Since her symptoms kept aggravating she was referred to tertiary care center.

On examination she was febrile, temperature was 100.6<sup>0</sup>F, her BP was 100/62 mm Hg, PR= 88/mt, SpO<sub>2</sub> 78% on room air, RR=32/mt and she uses sternocleidomastoid muscle, abdominal muscles for respiration. Chest auscultation revealed B/L crackles with wheezy chest. Her heart sounds were heard at the right side of the chest. Had grade 3 clubbing of the nails.

## **X. NURSING CARE OF MRS. A IS DISCUSSED USING THE NURSING PROCESS APPROACH.**

1) *Nursing Diagnosis:* Ineffective airway clearance related to pooling of tracheobronchial secretions as evidenced by presence of thick secretions.

*Expected outcome:* She maintains patent airway as evidenced by equal air entry bilaterally and absence of secretions.

### **Interventions:**

- Assessed the color, amount and consistency of secretions. She expectorated thick, copious white sputum.
- On auscultation, bilateral air entry with bilateral crackles and wheezy chest was present. Performed chest physiotherapy and Nebulization (Salbutamol 5mg) was administered every Q4h.

- Changed position every Q2h to enhance mobilization of the secretions. Administered IV fluids- Normal saline at 40ml/hr to maintain adequate hydration.

**Evaluation:** She maintained patent airway as evidenced by decrease in thick copious secretions and absence of wheezing sounds.

- 2) **Nursing Diagnosis:** Impaired breathing pattern related to inflammation and infection of the bronchi as evidenced by tachypnea and use of accessory muscles for breathing.

**Expected outcome:** She maintains effective breathing pattern as evidenced by normal respiratory rate and absence of accessory muscle use.

**Interventions:**

- Assessed the respiratory rate (RR), rhythm, depth and use of accessory muscles and lung sounds. The RR was 32/mt and she was using the sternocleidomastoid muscle and abdominal muscles for respiration. Bilateral crackles and wheeze was present.
- Administered 6 L of Oxygen via face mask. Her SpO<sub>2</sub> improved to 90%.
- Placed her in fowler's position
- Administered bronchodilators (Salbutamol 5mg) and corticosteroids (Hydrocortisone 100mg).
- Administered antipyretics to reduce high temperature thereby reducing the high metabolic needs.
- Provided comfortable and calm environment.

**Evaluation:** She maintained effective breathing pattern as evidenced by normal breath sounds, respiratory rate of 22/mt, SpO<sub>2</sub> 95%.

- 3) **Nursing Diagnosis:** Impaired gas exchange related to decreased oxygen carrying capacity and accumulation of secretions as evidenced by SpO<sub>2</sub> 78%

**Expected outcome:** She maintains effective gas exchange as evidenced by SpO<sub>2</sub> more than 90%

**Interventions:**

- Assessed her SpO<sub>2</sub> levels, RR, orientation status, clubbing of nails.
- Administered 6L of oxygen via face mask.
- Positioned her in fowler'.
- Paced her activities with adequate rest periods.
- Administered mucolytics to remove the thick copious secretions.
- Monitored for signs of hypoxemia.
- Performed ABG, shows no hypoxemia.
- Educated to perform deep breathing and coughing exercises.

**Evaluation:**

She maintained effective gas exchange as evidenced by SpO<sub>2</sub> of 95%

- 4) **Nursing Diagnosis :** Hyperthermia related to infection and inflammation of the airways as evidenced by increase in body temperature to 100.4<sup>0</sup>F

**Expected Outcome:** She maintains normal body temperature as evidenced by Temperature within normal range.

**Interventions:**

- Assessed the temperature, heart rate and respiratory rate.
- Increase in temperature may alter the RR and HR.
- Administered antipyretics as per the physician's order (Tab. Paracetamol 1000mg PRN).
- Administered IV fluids (Normal saline) to replace fluids due to hyperthermia.
- Loosened and change to thin comfortable clothing.
- Switched on the fan to enhance radiation of the heat.
- Started on cold applications since she did not have chills.

**Evaluation:** She maintained normal body temperature as evidenced by temperature of 98.2<sup>0</sup>F

5) **Nursing Diagnosis:** Imbalanced nutrition less than the body requirement related to tachypnea and anorexia as evidenced by weight loss

**Expected outcome:** Her nutritional status is improved as evidenced by increase in intake and gradual weight gain.

**Interventions:**

- Assessed her body weight, serum albumin levels. Her body weight is 65 Kgs, Height is 170cms and serum albumin levels are 2.0gm%.
- She was started on anti-emetics (Inj. Emeset 4mg IV).
- Was on 6 L oxygen.
- She was administered 5% dextrose as continuous infusion at the rate of 50ml/hr.
- She was started on liquid diet once her dyspnea subsided.

**Evaluation:** Her nutritional status marginally improved as evidenced by tolerance to liquid diet.

## XI. CONCLUSION

In majority of cases, Kartagener syndrome and cystic fibrosis can be detected in early childhood whereas in few it can stay concealed until the symptoms become severe leading to complications. To throw the limelight, early detection is very essential for a better prognosis.

## REFERENCES

- [1]. Chang, W. J., Kung, W. C., & Chiu, W. Y. (2017). Kartagener syndrome. *QJM: An International Journal of Medicine*, 110(8), 523-523, <https://doi.org/10.1093/qjmed/hcx083>
- [2]. Ciancio, N., de Santi, M.M., Campisi, R. et al. Kartagener's syndrome: review of a case series. *Multidiscip Respir Med* 10, 18 (2015). <https://doi.org/10.1186/s40248-015-0015-2>
- [3]. Corbelli, R., Bringolf-Isler, B., Amacher, A., Sasse, B., Spycher, M., & Hammer, J. (2004). Nasal nitric oxide measurements to screen children for primary ciliary dyskinesia. *Chest*, 126(4), 1054-1059. <https://doi.org/10.1378/chest.126.4.1054>
- [4]. Gupta, S., Handa, K. K., Kasliwal, R. R., & Bajpai, P. (2012). A case of Kartagener's syndrome: Importance of early diagnosis and treatment. *Indian journal of human genetics*, 18(2), 263–267. <https://doi.org/10.4103/0971-6866.100787>
- [5]. Ibrahim, R., & Daoood, H. (2021). Kartagener syndrome: A case report. *Canadian journal of respiratory therapy: CJRT = Revue canadienne de la therapie respiratoire: RCTR*, 57, 44–48. <https://doi.org/10.29390/cjrt-2020-064>
- [6]. Lu, S.J., Loo, S.W. Kartagener syndrome. *Intern Emerg Med* 10, 639–640 (2015). <https://doi.org/10.1007/s11739-015-1201-0>
- [7]. Macchiarini, P., Chapelier, A., Vouhé, P., Cerrina, J., Ladurie, F. L. R., Parquin, F., & Darteville, P. (1994). Double lung transplantation in situs inversus with Kartagener's syndrome. *The Journal of Thoracic and Cardiovascular Surgery*, 108(1), 86-91. [https://doi.org/10.1016/S0022-5223\(94\)70223-3](https://doi.org/10.1016/S0022-5223(94)70223-3)
- [8]. Palange AA, Shahid AM, Sisode MS, Vaishnav B. Kartagener's syndrome: case report. *Int J Healthcare Biomed Res*. 2013;2(1):67–69
- [9]. Sahu, S., Ranganatha, R., Batura, U., Choubey, U., Meghana, D. R., Menon, V. R., & Harshith, M. (2022). A Case of Unusual Presentation of Kartagener's Syndrome in a 22-Year-Old Female Patient. *Cureus*, 14(8). DOI: 10.7759/cureus.28119
- [10]. Skeik, N., & Jabr, F. I. (2011). Kartagener syndrome. *International Journal of General Medicine*, 41–43.
- [11]. Tadesse, A., Alemu, H., Silamsaw, M. et al. Kartagener's syndrome: a case report. *J Med Case Reports* 12, 5 (2018). <https://doi.org/10.1186/s13256-017-1538-2> 10 Jan 2018
- [12]. Willim, H. A., Pebriadi, D., Munthe, E. L., Cipta, H., Mujono, W., & Muin, A. (2023). Kartagener Syndrome: A Case Report. *Archives of The Medicine and1 Case Reports*, 4(1), 319-324.

Renuga Devi. "Kartagener's Syndrome: A Nursing Case Presentation." *IOSR Journal of Nursing and Health Science (IOSR-JNHS)* 12(3), 2023, pp. 45-50.