

# COVID severe pneumonia in children: a rare clinical presentation and uncommon radiological finding

A. DAOUDI<sup>1</sup>, H. BAZHAR<sup>1</sup>, K.NAINIA<sup>1</sup>, S.Tizki<sup>1</sup>

<sup>1</sup>(Departement of pediatrics, University hospital of Souss-Massa, Faculty of Medicine of Agadir, Ibn-Zohr University, Agadir, Morocco)

## Abstract:

Since the outbreak of COVID 19, it has quickly spread worldwide affecting millions of people of all ages, however, the data on its clinical impact on the pediatric population is still lacking. We follow the case of an infant of 8 months, COVID 19 patient who presented a spontaneous pneumothorax, pneumomediastinum and sub-cutaneous emphysema during his hospitalization, the presumed etiology of the pneumothorax was the alveolar damage, since he didn't undergo any invasive ventilation and his supplemental oxygenation via high flow-nasal cannula was regularly interrupted to prevent any iatrogenic complications. Pneumothorax, pneumomediastinum and subcutaneous emphysema must be known as a possible complication of COVID pulmonary infection of both adults and children, as soon as these complications occurs a careful monitoring should be implemented in order to prevent any respiratory deterioration.

**Key Word:** COVID-19; Children; Spontaneous pneumothorax; Subcutaneous emphysema; Pneumomediastinum.

Date of Submission: 02-01-2023

Date of Acceptance: 14-01-2023

## I. Introduction

The COVID 19 pandemic has been responsible so far for an enormous number of cases worldwide, which can be explained by its rapidity of spreading especially among the adult population, this later has been comprised most of the serious cases due to the virus and associated with a high profile of morbidity and mortality. Nevertheless, its impact among the pediatric population remains unclear as diverse clinical presentations emerge going from low and mild intense symptoms to critical cases that require high intensity care. We describe a case of 8 months old child presented with spontaneous pneumomediastinum pneumothorax and sub-cutaneous emphysema associated with COVID19. Our objective is to reveal a rare COVID 19 presentation potentially life-threatening that many health professionals may not be aware of.

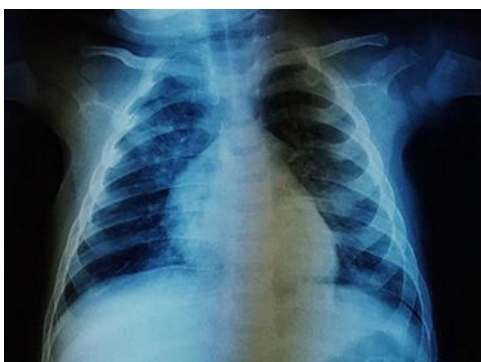## II. Case report

We report the case of an 8 months old child with no medical history. Admitted to the pediatric department in May 2021 with 2 days of fever and expiratory dyspnea. On physical examination he had a fever of 38.5°C, he was tachycardiac at 130bpm, normal blood oxygen level at 97%, yet he had a high breathing rate (46cpm) and upper chest retraction, with a rhonchus on the upper right lobe during his chest auscultation. A chest X-ray showed a thoracic distension with right superior interstitial infiltrates and an opacity on the lower left lobe (Figure1).

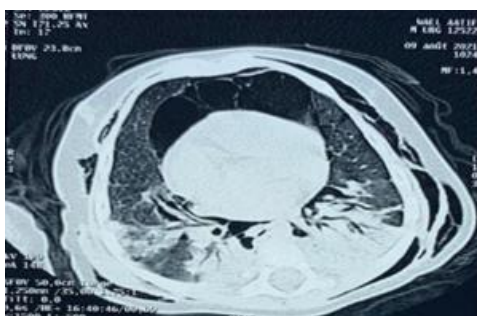
Following his admission, he was put under supportive care with supplemental oxygen (3 l/min) via nasal canula while assuring a good hydration. On the next day (day 2), he appeared to be tired on examination and presented signs of acute respiratory distress with nasal flaring, worsening of his dyspnea and persistence of chest retraction despite the oxygen therapy, in addition to sweating and cyanosis, motivated by this evolution a PCR test for COVID-19 was performed and revealed positive, as a result the patient was isolated and the treatment was initiated (Zinc 10mg/kg/day, Vit C 5mg/kg/day, Vit D 400 UI/day, Azithromycin 20mg/kg/day). On the following day (day 3), there was no significant evolution in comparison to his previous condition, as the results of the laboratory tests were obtained and it has shown a good hemoglobin level (12g/dl), 14210 leucocytes/mm<sup>3</sup>, normal levels of inflammatory markers (CRP of 9.2mg/l, ferritin moderately elevated at 250ng/ml).

Methylprednisolone 2mg/kg/day and Hydroxychloroquine (5mg/kg/day) were initiated. The 5th day of hospitalization marks the apparition of a remarkable subcutaneous emphysema on the upper body of the patient (thorax and neck) contrasting to a relative stabilization of his oxygen levels at 87% while remaining under the same conditions of oxygen and treatment. A chest computer tomography (CT) was performed and showed

ground glass opacities which suggest the COVID origin, a left mild sized pneumothorax and a pneumomediastinum (Figure 2). The subcutaneous emphysema was extended causing face swelling and disappearance of body reliefs such as sub-clavicular area. There is no indication of chest drainage. The evolution was favorable marked by a progressive amelioration of his subcutaneous emphysema and the child was discharged in good general condition and a normal chest X ray.



**Figure 1:** Chest X-ray with interstitial infiltrates on the right superior lobe



**Figure 2:** CT scan showing ground glass opacities, a mild sized pneumothorax, pneumomediastinum and thoracic sub-cutaneous emphysema.

### **III. Discussion**

Previous studies state that children affected by COVID-19 present in general, low to milder clinical symptoms that range from being asymptomatic to acute upper respiratory tract infection, which may explain the reduced number of children hospitalizations and low mortality due to COVID 19 compared with the adults, often presenting complicated forms [1]. However, despite the limited number of severe cases, complications among COVID19-infected children may occur, which leads to increase the knowledge regarding this potentially dangerous infection, in terms of its possible clinical and imaging features among the pediatric population [2].

In the literature, it has been reported, some cases of adults patients especially with severe or critical disease, who developed, like our case, a spontaneous pneumothorax, pneumomediastinum and subcutaneous emphysema, either associated or not, and only secondary to COVID 19 pneumonia [3, 4].

The apparition of the spontaneous pneumothorax can be explained by the diffuse alveolar damage due to the inflammation associated with COVID 19 disease that leads eventually to rupture, and then the air spreading to the pleural cavity [3].

Spontaneous pneumothorax especially at a small size like our case is considered to be a benign disease that may only need supplemental oxygen to be absorbed spontaneously, the pneumomediastinum and the emphysema disappearance is following the same principle, therefore it may not always be the case, as there were some patients who needed needle compression or chest drainage [4, 5].

Supportive care is recommended for the majority of children with mild disease. In children with more severe disease, and despite the absence of safety and efficacy data, several guidelines suggest the consideration of antiviral therapy remdesivir with corticosteroids (dexamethasone) or biologic agents (tocilizumab). Moreover, It has been approved the efficiency of monoclonal antibody therapy Sotrovimab in children aged 12 years and above with risk factors for progression to severe COVID-19 disease [6].

#### **IV. Conclusion**

The rapid deterioration of respiratory status in COVID 19 pediatric patient should suggest the possibility of a pneumothorax or pneumomediastinum even if the patient didn't receive any invasive ventilation.

#### **References**

- [1]. Ludvigsson J. Systematic review of COVID-19 in children shows milder cases and a better prognosis than adults. *Acta Paediatr.* 2020; 109:1088-95.
- [2]. Di Nardo M, van Leeuwen G, Loreti A, Barbieri M, Guner Y, Locatelli F, and al. Literature review of 2019 novel coronavirus (SARS-CoV-2) infection in neonates and children. *Pediatr Pediatric Research*; volume 89;101–1108. 2020.
- [3]. Lemmers D, Abu Hilal M, Bnà C, Prezioso C, et al. Pneumomediastinum and subcutaneous emphysema in COVID-19: barotrauma or lung fragility?. *ERJ Open Research* 2020: 00385-2020.
- [4]. Elhakim TS, Abdul HS, Pelaez Romero C, and al. Spontaneous pneumomediastinum, pneumothorax and subcutaneous emphysema in COVID-19 pneumonia: a rare case and literature review. *BMJ Case Reports CP* 2020.
- [5]. Janssen ML, van Manen MJG, Cretier SE, Braunstahl G-J. Pneumothorax in patients with prior or current COVID-19 pneumonia. *Respir Med Case Rep* 2020; 31: 101187.
- [6]. Howard-Jones A.R., Burgner D.P., Crawford N.W., Goeman E., E Gray P., et al. COVID-19 in children. II: Pathogenesis, disease spectrum and management. *J. Paediatr. Child Health.* 2022;58:46–53

A. DAOUDI, et. al. "COVID severe pneumonia in children: a rare clinical presentation and uncommon radiological finding." *IOSR Journal of Nursing and Health Science (IOSR-JNHS)*, 12(1), 2023, pp. 04-06.