

Epithelial Downgrowth after Open Globe Injury in a Pediatric.

Benchakroun S¹, Taouri N², H.LAZAAR², boutimzine N², Amazouzi A2, Cherkaoui LO².

¹ Department A of Ophthalmology, Mohammed V University Souissi, Rabat, Morocco.

² Department A of Ophthalmology, Mohammed V University Souissi, Rabat, Morocco.

Corresponding author: BENCHAKROUN S, Department A of Ophthalmology, Mohammed V University Souissi, Rabat, Morocco.

Date of Submission: 01-09-2021

Date of acceptance: 15-09-2021

We report a case of a 12 years old girl with no medical history, who presented for penetrating ocular trauma of her right eye. The clinical examination at that time found a penetrating limballaceration from 11 to 2 o'clock position, shallow anterior chamber, hyphaema with aniridia and traumatic cataract. The patient underwent an uncomplicated cataract surgery and IOL implantation with suture of of her right eye. Her postoperative course was unremarkable for the first 6 months. She then presented to routine follow-up reporting a painless progressively decreased vision in her right eye. Her visual acuity was 3/10 in the right eye. The intraocular pressure (IOP) was 14 mmHg OS. Slit-lamp examination of the left eye revealed a translucent fibrovascular membrane around the capsulorhexis, with neovascularization, coming from the angle left was noted to have also a superonasal white membrane behind the IOL (Fig. 1). The diagnosis of epithelial downgrowth was made. We indicated surgical ablation of the epithelial membrane with Intracameral 5-fluorouracil (FU) injections.

Epithelial downgrowth is a rare pathology, due to epithelial cells that invade the anterior chamber may cause irreversible loss of vision[1,2]. This condition was classified into three major forms: epithelial pearls, cysts, and sheets[2].

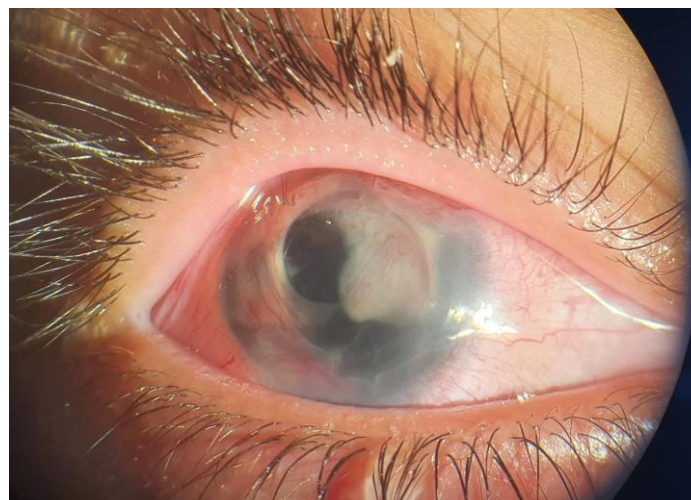And it has been reported after many types of surgery, and open globe injury.also, after glaucoma implant surgery as retro corneal membranes[1,2,3,4].

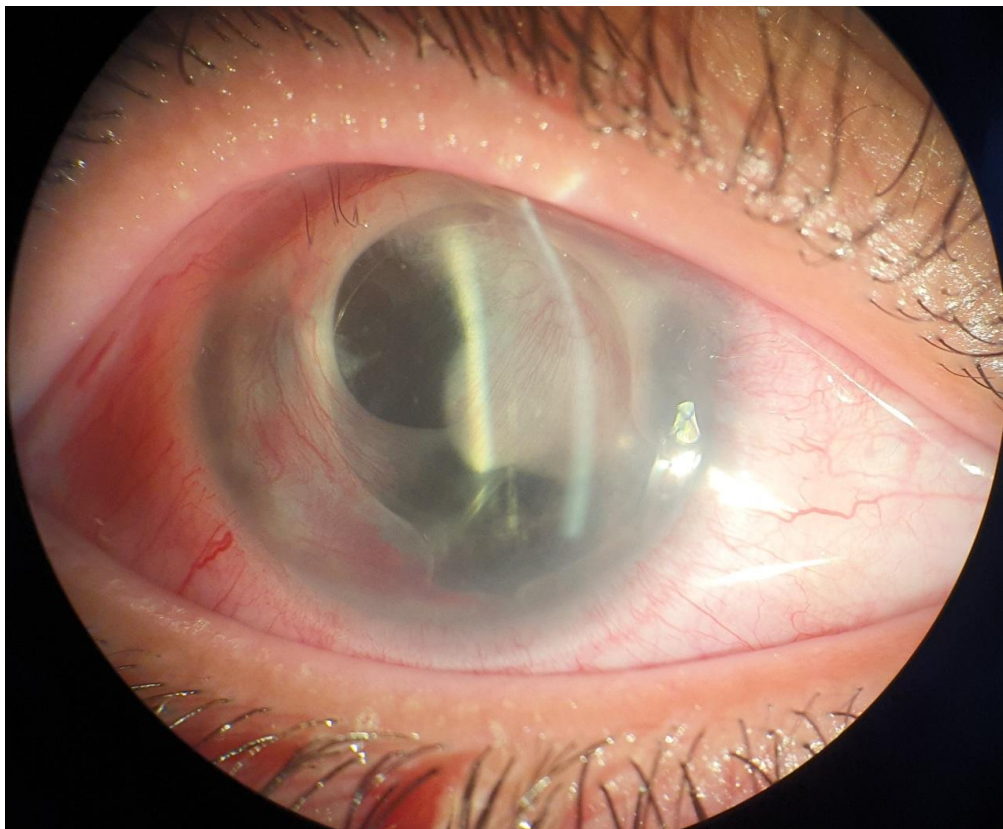
The cells penetrate the anterior chamber and proliferate, causing serious damage of ocular tissues: corneal decompensation, corectopia, ectropionuveae, or secondary glaucoma[1,2].

Many treatment strategies were suggested by several authors, such as surgical resection of the involved tissues, and the antimetabolite therapy agent 5-fluorouracil (5FU) intracameral injection[1,2].

Figure:

figure :Slit lamp photograph of the right eye showing epithelial downgrowth and demonstrating a neovascular membrane





References:

- [1]. Han Kim, Michele C. Lim*, Mark J. Mannis, Esther S. Kim. Epithelial downgrowth after femtosecond laser-assisted cataract surgery Epithelialdowngrowth after femtosecond laser-assisted cataract surgerymerican. *Journal of Ophthalmology Case Reports* 15 (2019) 100507
- [2]. Le, Viet Nhat Hung, et al. "Epithelial downgrowth after Descemet membrane endothelial keratoplasty." *European journal of ophthalmology* 31.2 (2021): NP27-NP32.
- [3]. Viestenz, Arne, et al. "Epithelial invasion after open globe injury." *Clinical Anatomy* 31.1 (2018): 68-71.
- [4]. Hu, Jennifer, et al. "Epithelial downgrowth after Ahmed implantation presenting as a peritubularfibrovascular membrane." *Journal of glaucoma* 22.6 (2013): e11-e13.

Conflict of interest:The author declares that there is no conflict of interest.

BENCHAKROUN S, et. al. " Epithelial Downgrowth after Open Globe Injury in a Pediatric." *IOSR Journal of Nursing and Health Science (IOSR-JNHS)*, 10(5), 2021, pp. 62-63.