

Investigations of the Effects of Ethanolic and Aqueous Extracts of The Leaves of Common Milkweed (*Asclepiassyriaca*) on Loperamide Induced Constipation and Histology of the Large and Small Intestine of the GIT of Wistar Rats

¹Preyor E, ²Sanni, G.P

¹Department of Human Anatomy, Madonna University, Elele, Nigeria.

²Department of Human Anatomy, University of Ibadan, Nigeria.

ABSTRACT

This study accessed the effects of ethanol and aqueous extract of *Asclepiassyriaca* on loperamide induced constipation and its histological effects on some gastrointestinal tracts (small and large intestines). Twenty eight (28) adult wistar rats weighing 120g-200g were used for this study; the animals were weighed and sorted into two sets (A and B). set A consists of three groups (2-4) for ethanol extracts and set B also consists of 3 groups (5-7) for aqueous extract. While group one serves as control for both sets. Prior to extracts administration, the experimental groups (2-7) were given 3mg/kg body weight of loperamide for 3 days to induce constipation. The control received feed mash and water liberally, while the treated groups in set A; 2-4 were given 10mg/ml, 15mg/ml and 20mg/ml of ethanol extracts of *Asclepiassyriaca* respectively. Set B; 5-7 were given 10mg/ml, 15mg/ml and 20mg/ml of aqueous extracts of *Asclepiassyriaca* respectively. Both sets also received feed mash and water liberally. At the end of the two weeks (14 days) experiment, animals were sacrificed, organs harvested and fixed in 10% formal saline for histological studies. The results showed normal histological features in both small and large intestines of group 2 and 5 treated with 10mg/ml of ethanol and aqueous extracts respectively. There was degeneration of crypts of mucosa in the large intestine and loss of villi in the small intestine of the other groups treated with 15mg/ml and 20mg/ml of ethanol and aqueous extracts (3,4,6, and 7). The study also showed that the leaves of *Asclepiassyriaca* relieved constipation in all experimental groups. However, it had a dose-dependent histological effect on the large and small intestines of GIT.

Keywords: constipation; *Asclepiassyriaca*; common milkweed; small intestine, large intestine

Date of Submission: 14-02-2023

Date of Acceptance: 28-02-2023

I. INTRODUCTION

Constipation is one of the most common community problems and it is commonly defined as lack of satisfactory defecation (Werth & Christopher, 2021). Chronic constipation is a common disorder with a reported prevalence ranging from 3% to 27% in the general population (Schmidt & Santos, 2014). The most common cause of constipation has been reported to be diets with little fibre as well as inadequate fluid intake (Annells & Koch 2003). Several management strategies, including diagnostic tests, empiric treatments, and specific treatments, have been developed (Mearin et al., 2016)

Asclepiassyriaca which is known as "Common Milkweed" is said to have many medicinal uses (Everitt et al, 2009). It had a fairly significant action on the digestive tract. It stimulates general circulation and is useful to produce adequate hydrochloric acid (Margret, 2010). It helps in chronic constipation and is a fairly detoxifying herb, and it supports the removal of toxins from the body through its action on the blood, lymphatic circulation, and digestive system (Adelmanet & Schwartz, 2011).

II. MATERIALS AND METHODS

Study Location: This research was conducted in the Department of Anatomy, Madonna University, Elele, Rivers State, Nigeria.

Preparation of the Aqueous and Ethanol Plant Extracts: Fresh leaf samples of *Asclepiassyriaca* were collected from the backyard of a compound in Kpakiamia Town, Bomadi LGA, Delta State, Nigeria. The leaves

were authenticated at the department of Pharmacognosy, Madonna University, Elele. The fresh leaf (*Asclepiassyriaca*) were washed in clean water, dried to remove water content and pounded into a paste form, which was transferred into a soxhlet apparatus (Surya, 2012).The mixtures (active agent of *Asclepiassyriaca* + water) and (active agent of *Asclepiassyriaca* + ethanol) were about 500ml each using the soxhlet apparatus. The mixtures were concentrated with a hot air oven at a temperature of about 45⁰C. The yield of the crude aqueous and ethanol plant extracts were 80g each. The extracts was stored in the refrigerator until required for use. 8g of extract was dissolved in 80ml of normal saline (desired concentration).

Experimental Animals and Design: Twenty Eight (28) adult wistar rats were purchased from the animal unit, Faculty of Basic Medical Science, Madonna University, Elele, Rivers State, Nigeria. The 28 rats weighing 120g-200g were divided into 2 sets. set A consists of groups (2-4) for ethanol extracts and set B consists of groups (5-7) for aqueous extract. While group (1) serves as control for both sets. All the animals were acclimatized for two weeks, thereafter were weighed and sorted into seven groups (1-7) with respect to their weight (with 4rats in each group), this applies to rats in set A and B. Each group was housed in a well-ventilated cage at room temperature.

Constipation Induction: The experimental groups (2-7) were given 3mg/kg body weight of loperamide for 3 days to induce constipation and then treated for 14 days.

Extract Administration: Ethanol extract of *Asclepiassyriaca* was administered orally using an orogastric tube for fourteen (14) days. Administration is as follows; group one served as control and given feed (Mayer's mash) and water, group 2, 3 and 4 were administered 10mg/ml, 15mg/ml and 20mg/ml respectively of ethanol extract of *Asclepiassyriaca*. Group 5, 6, and 7 were administered 10mg/ml, 15mg/ml and 20mg/ml respectively of aqueous extract of *Asclepiassyriaca*, this was done once a day plus feed (Mayer's mash) + water. The aqueous extracts. During the course of the experiment, the rat's stools were checked daily to see if there were any changes in the colour, consistency and odour and their body weight was measured every week.

Sample Collection and Histological Examination: At the end of the experimental period, animals were sacrificed with the aid of chloroform and the small and large intestines were quickly harvested and fixed using 10% formal saline and processed in the histology lab for histological examinations. For histological research, these tissues went through the standard stages of tissue processing (H&E staining)

III. RESULT

Table 1 below shows the weekly total body weight differences in animal models treated with different doses of ethanol extracts of the leaves of *Asclepiassyriaca*. There was no statistically significant difference ($p>0.05$).

Table 2 below shows the weekly total body weight differences in animal models treated with different doses of aqueous extracts of the leaves of *Asclepiassyriaca*. There was no statistically significant difference

Table 3 below shows the effect of ethanol extracts of the leaves of *Asclepiassyriaca* on constipation in animal models treated with different doses of ethanol extracts of the leaves of *Asclepiassyriaca* and the control.

Table 4 below shows the effect of aqueous extracts of the leaves of *Asclepiassyriaca* on constipation in animal models treated with different doses of aqueous extracts of the leaves of *Asclepiassyriaca* and the control.

Table 1: Total body weight differences in animal treated with ethanol extract

GROUPS	WEEK 1	WEEK 2
Group 1 (Control)	148.3 ± 8.58	150 ± 1.41
Group 2 (10mg)	155 ± 8.60	152 ± 6.18
Group 3 (15mg)	181 ± 6.48	177.3 ± 5.32
Group 4 (20mg)	216.7 ± 3.4	212.67 ± 4.97

Values were expressed as mean ± SD; $p>0.05$

Table 2: Total body weight differences in animal treated with aqueous extract

GROUPS	WEEK 1	WEEK 2
Group 1 (Control)	148.3 ± 8.58	150 ± 1.41
Group 5 (10mg)	155 ± 3.56	153.7 ± 3.74
Group 6 (15mg)	177.3 ± 5.25	175.3 ± 5.44
Group 7 (20mg)	220.7 ± 4.92	215 ± 7.34

Values were expressed as mean ± SD; p>0.05

Table 3: Stool characteristics treated with ethanol extract

	WEEKS	GRP 1	GRP 2	GRP 3	GRP 4
Stool Consistency	week 1	Bulky	Bulky	Bulky	Slightly loose
	week 2	Bulky	Loose	Loose	Watery
Stool Colour	week 1	Normal	Normal	Light green	Light green
	week 2	Normal	Dark green	Dark green	Dark green
Stool Odour	week 1	Normal	Normal	Normal	Normal
	week 2	Normal	Normal	Pungent	Pungent

Table 4: Stool characteristics treated with aqueous extract

	WEEKS	GRP 1	GRP 5	GRP 6	GRP 7
Stool Consistency	week 1	Bulky	Bulky	Bulky	Slightly loose
	week 2	Bulky	Loose	Loose	Watery
Stool Colour	week 1	Normal	Normal	Light green	Light green
	week 2	Normal	Dark green	Dark green	Dark green
Stool Odour	week 1	Normal	Normal	Normal	Normal
	week 2	Normal	Normal	Pungent	Pungent

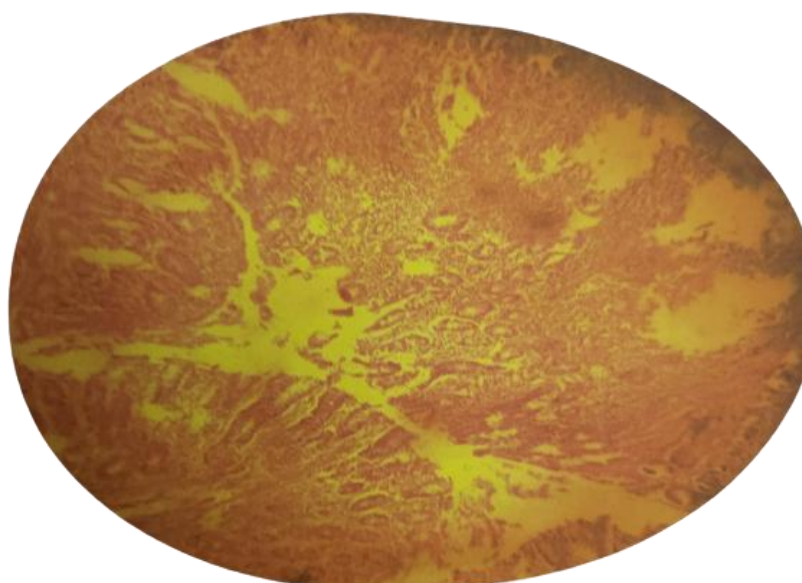


Plate 1: Photomicrograph of normal features of large intestine of (control group 1)

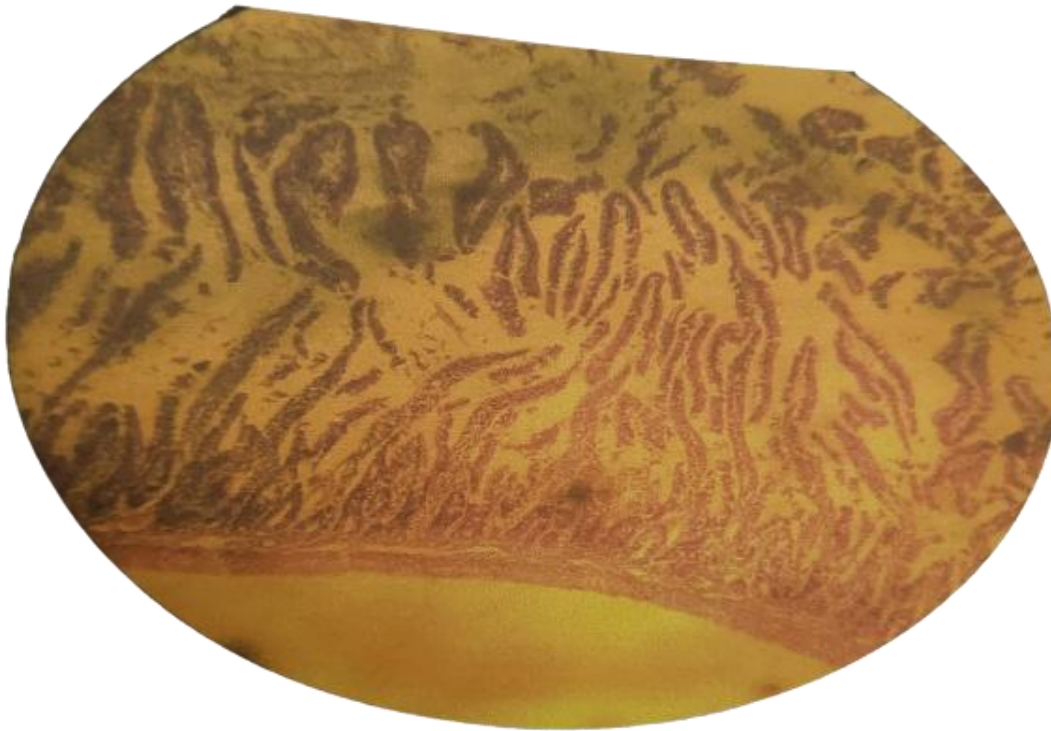


Plate 2: Photomicrograph of small intestine showing prominent villi and crypts of Lieberkuhn (control group 1)

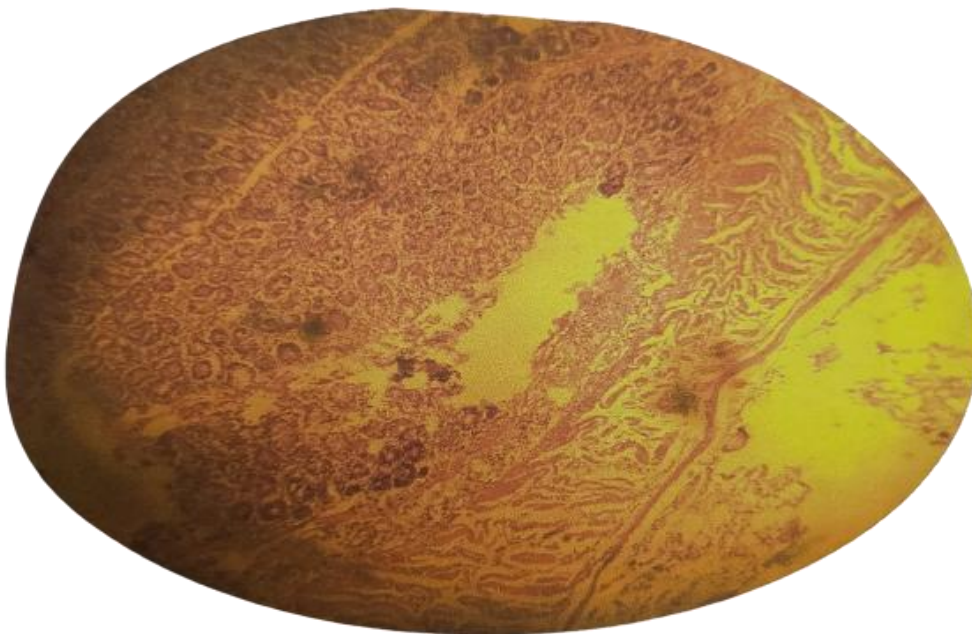


Plate 3: Photomicrograph of Large Intestine treated with 10mg/ml of ethanol extract of *Asclepiassyriaca* (group 2) for 14days showing prominent crypts of mucosa (H&E x 10)



Plate 4: Photomicrograph of Small Intestine treated with 10mg/ml of ethanol extract of *Asclepiassyriaca* (group 2) for 14days showing tall cylinder of villi and crypts of Lieberkuhn (H&E x 10)



Plate 5: Photomicrograph of Large Intestine treated with 15mg/ml of ethanol extract of *Asclepiassyriaca* (group 3) for 14days showing degeneration of crypts of mucosa (H&E x 10)

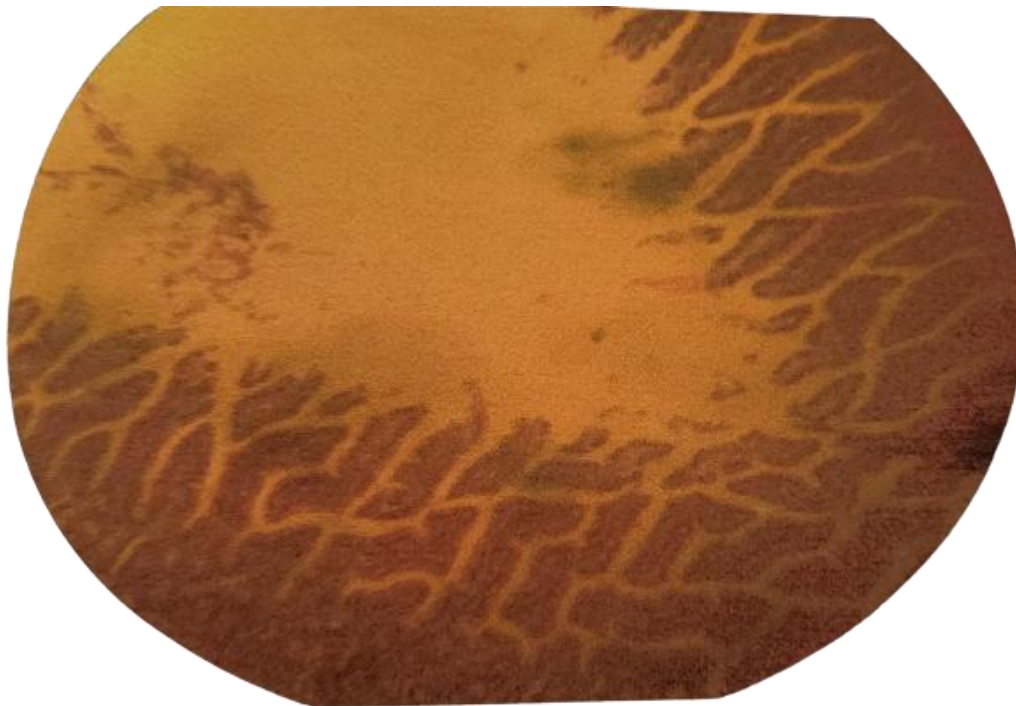


Plate 6: Photomicrograph of Small Intestine treated with 15mg/ml of ethanol extract of *Asclepiassyriaca* (group 3) for 14days showing loss of villi (H&E x 10)

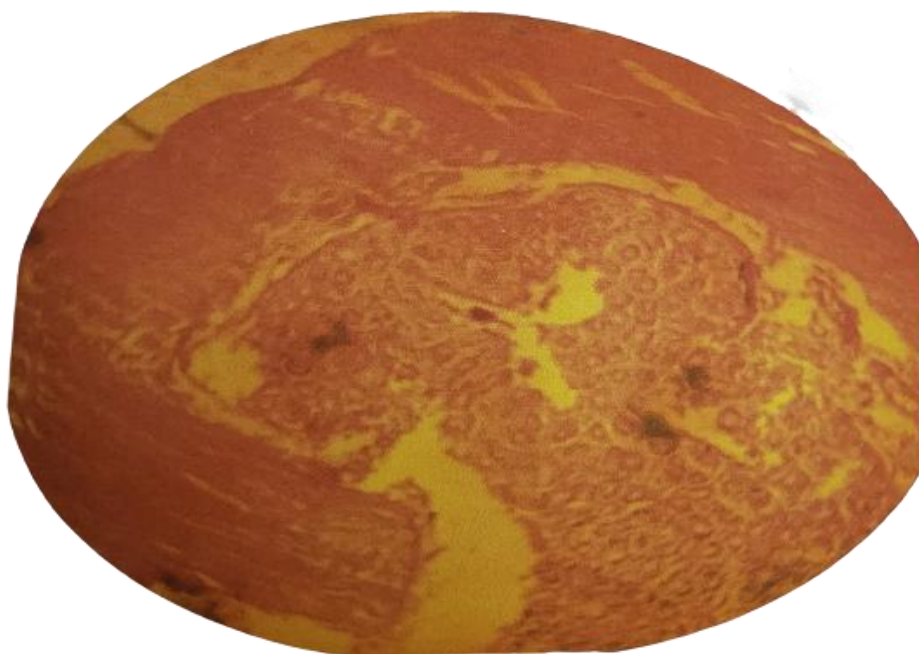


Plate 7: Photomicrograph of Large Intestine treated with 20mg/ml of ethanol extract of *Asclepiassyriaca* (group 4) for 14days showing exfoliation of mucosa (H&E x 10)

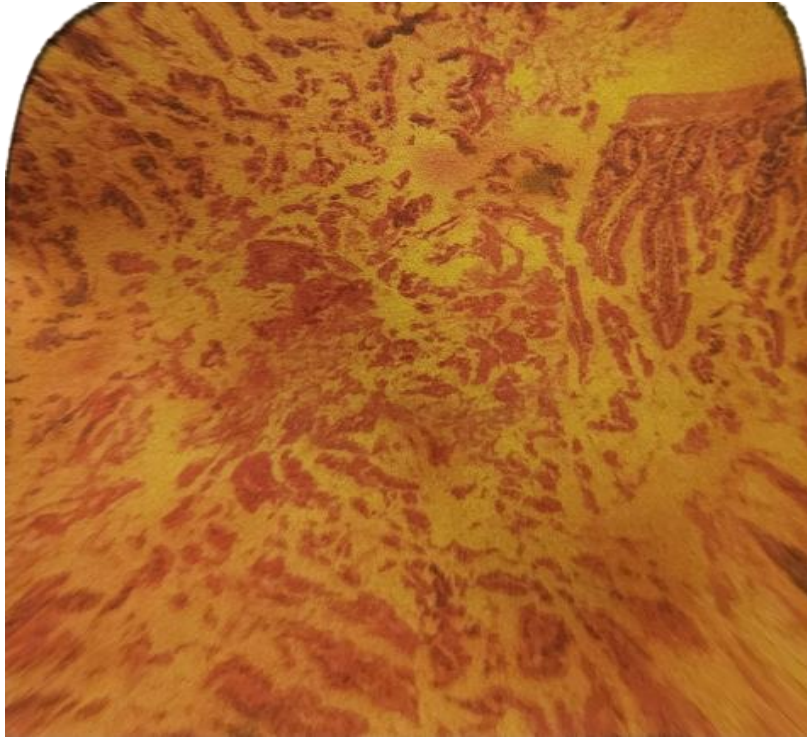


Plate 8: Photomicrograph of Small Intestine treated with 20mg/ml of ethanol extract of *Asclepiassyriaca* (group 4) for 14days showing loss of villi (H&E x 10)

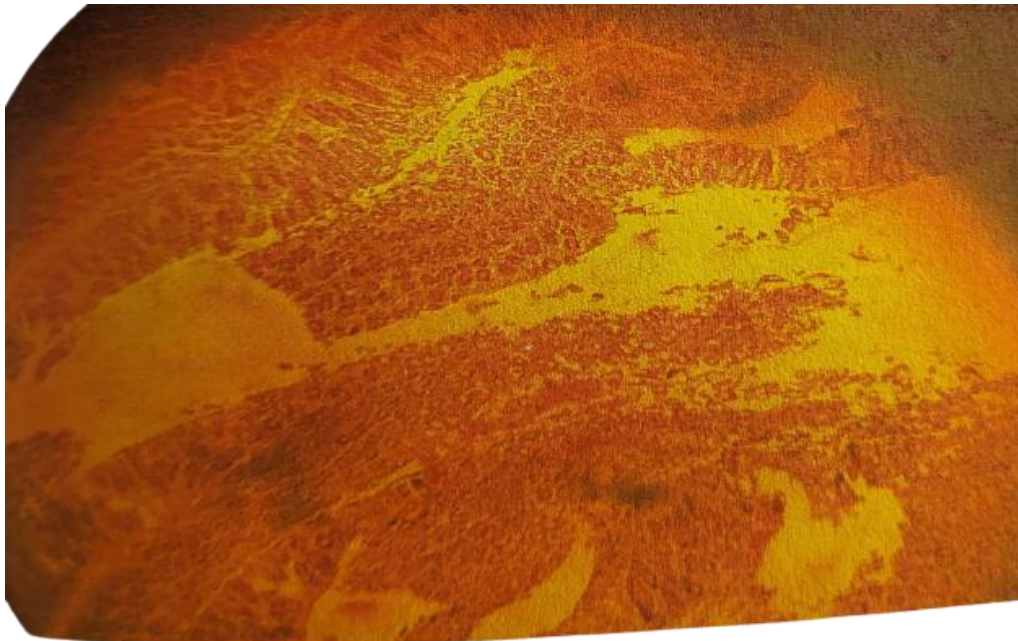


Plate 9: Photomicrograph of Large Intestine treated with 10mg/ml of aqueous extract of *Asclepiassyriaca* (group 5) for 14days showing prominent crypts of mucosa (H&E x 10)

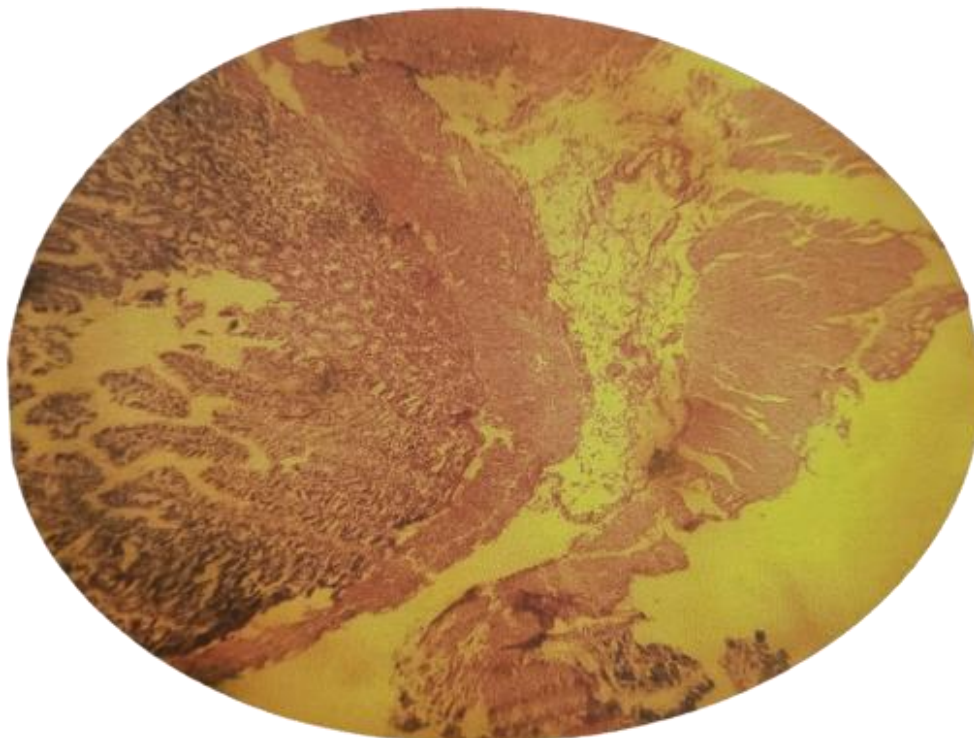


Plate 10: Photomicrograph of Large Intestine treated with 15mg/ml of aqueous extract of *Asclepiassyriaca* (group 6) for 14days showing degeneration of crypts of mucosa (H&E x 10)

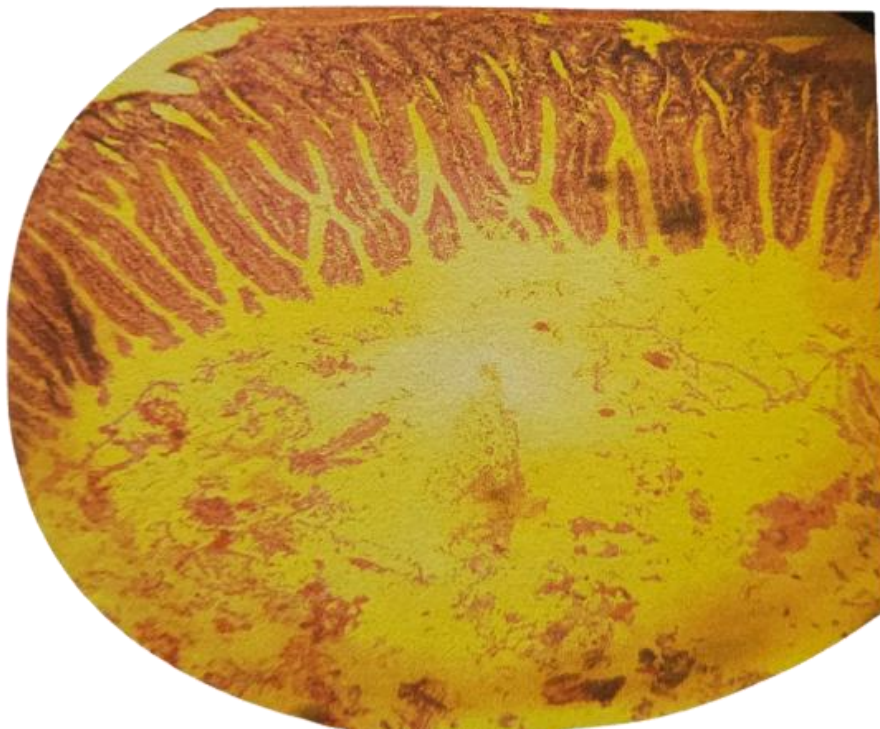


Plate 11: Photomicrograph of Small Intestine treated with 15mg/ml of aqueous extract of *Asclepiassyriaca* (group 6) for 14days showing loss of villi (H&E x 10)




Plate 12: Photomicrograph of Large Intestine treated with 20mg/ml of aqueous extract of *Asclepiassyriaca* (group 7) for 14days showing degeneration of crypts of mucosa (H&E x 10)

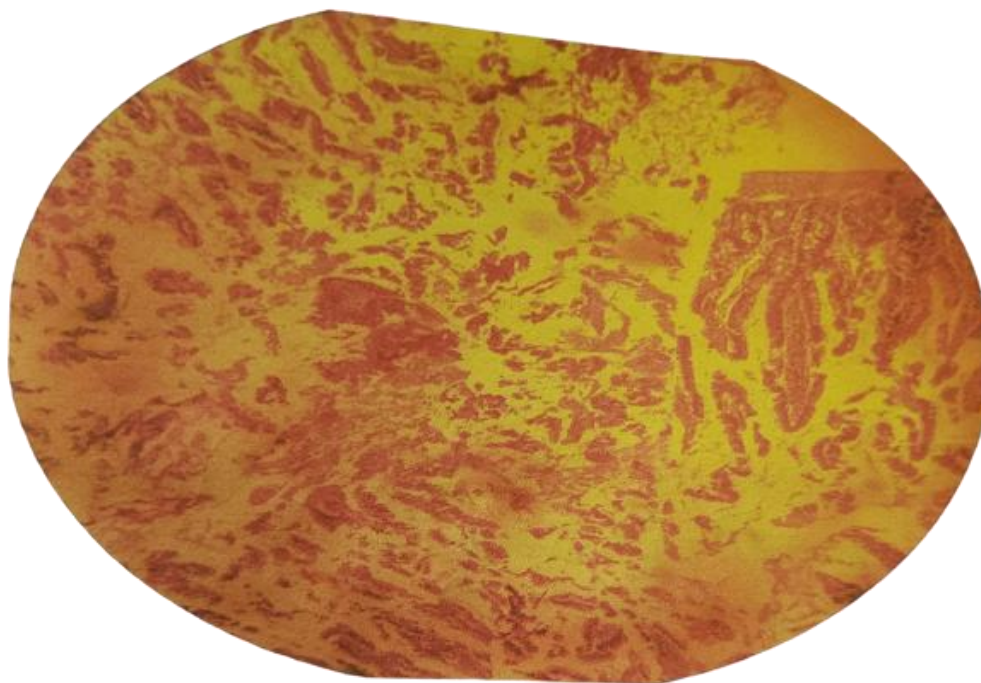


Plate 13: Photomicrograph of Small Intestine treated with 20mg/ml of aqueous extract of *Asclepiassyriaca* (group 7) for 14days showing loss of villi and crypts of Lieberkuhn (H&E x 10)

IV. DISCUSSION:

Herbal medicines are very popular in developing and underdeveloped countries with their indiscriminate use. Therefore, a clear understanding of potential adverse effects of herbs used is necessary for implementing safety measures. There are dearth of literatures in *Asclepiassyriaca*, and little or no systematic safety study had been done so far, hence a study on their toxicity is required. This present study tends to investigate the effects of ethanolic and aqueous extracts of the leaves of common milkweed (*Asclepiassyriaca*) on loperamide induced constipation and its histological effects on parts of the GIT (small and large intestines).

The tables 1 and 2 above reveal a slight weight loss in treated groups however the difference was not statistically significant with $p > 0.05$. The tables 3 and 4 above show that both ethanolic and aqueous extracts of *Asclepiassyriaca* were able to relieve constipation, especially in the second week of administration.

In this study the result showed that group 2 and 5 treated with both 10mg/ml of ethanol and aqueous extracts respectively showed normal histological organization in both small and large intestines with prominent crypts of Lieberkuhn and presence of Villi in small intestine as well as prominent crypts of mucosa in large intestine as shown in group 1 (control). Histological examination of the small and large intestines of both ethanol and aqueous extracts in group 3, 4, 6, and 7 revealed observable histological changes compared to control as shown in plates 5-8 and 10-13. Administration of both ethanol and aqueous extracts of *Asclepiassyriaca* at the doses of 15mg/ml and 20mg/ml indicates the possibility of the exfoliation or degeneration of the crypts of mucosa in the large intestines and loss of villi as well as degeneration of crypts of Lieberkuhn in small intestine.

V. CONCLUSION AND RECOMMENDATION

Our research has demonstrated ethanolic and aqueous extracts of the leaves of *Asclepiassyriaca* can effectively relieve chronic constipation. However, dose-dependent effects occur in the small and large intestines of the GIT of almost every treated group.

We therefore recommend a need to study the biochemical parameters of the leaves of *Asclepiassyriaca* on these organs and other vital organs as well as the lethal dose.

ETHICAL APPROVAL

International standard, rules and guidelines for use of animals for research was adhered to as approved by the committee

AUTHOR'S CONTRIBUTIONS

All the authors involved in this study made significant contributions towards the success of this presentation. Worthy of note, are their contributions during the article's review processes. No conflict of interest is declared.

REFERENCES

- [1]. Adelmanet, C. & Schwartz, B.L. 2011. The Midwestern Native Garden: Native Alternatives to Non-native Flowers and Plants an Illustrated Guide.
- [2]. Annells M, Koch T. Constipation and the preached trio: diet, fluid intake, exercise. *Int J Nurs Stud* 2003; 40: 843-852 [PMID: 14568365 DOI: 10.1016/s0020-7489(03)00075-0]
- [3]. Barbara, Y, James, S.L, Alan, S. and John, W.H (2006). *Wheater's functional histology. A text and colour atlas*, 5th Edition. Churchill Livingstone: Edinburgh
- [4]. Everett, J.H, Lonard, R.L and Little, C.R. 2009. *Weeds in south texas and northern Mexico*. Lubbock: Texas Tech University press. ISBN 0-8089-2317-X
- [5]. Mearin F, Lacy BE, Chang L, et al. Bowel disorders. In: Drossman DA, Chang L, Chey WD, Kellow J, Tack J, Whitehead WE, eds. *ROME IV, Functional Gastrointestinal Disorders-Disorders of gut brain interactions*, 4th edn. Raleigh, NC: The Rome Foundation; 2016:967-1058.
- [6]. Schmidt FM, Santos VL. Prevalence of constipation in the general adult population: an integrative review. *J Wound Ostomy Continence Nurs*. 2014;41:70-76.
- [7]. Surya Prakash, D.V., Sree Satya, N., and Vangalapati, M. (2012). Extraction of Chebulinic Acid from *TerminaliaChebulasp* by Soxlet Extractor- An Experiment and modeling studies. *Asian Journal of Biochemical and Pharmaceutical Research*: 2 (3): 170 -176.
- [8]. Werth BL, Christopher SA. Potential risk factors for constipation in the community. *World J Gastroenterol* 2021; 27(21): 2795-2817 URL: <https://www.wjgnet.com/1007-9327/full/v27/i21/2795.htm> DOI: <https://dx.doi.org/10.3748/wjg.v27.i21.2795>

Preyor E, et. al. "Investigations of the Effects of Ethanolic and Aqueous Extracts of The Leaves of Common Milkweed (*Asclepiassyriaca*) on Loperamide Induced Constipation and Histology of the Large and Small Intestine of the GIT of Wistar Rats." *IOSR Journal of Humanities and Social Science (IOSR-JHSS)*, 28(2), 2023, pp. 28-37.