

## Effect of Insecticide Carbaryl on Histomorphology of Testis and Fertility Index

Manumati Munglang<sup>1</sup> and Mahindra Nagar<sup>2</sup>

<sup>1</sup>Demonstrator, Department Of Anatomy, Assam Medical College and Hospitals, Dibrugarh, Assam, Pin Code-786002, India,

<sup>2</sup>Professor & Head Of Department, Department Of Anatomy, University College Of Medical Sciences And G.T.B Hospital, Delhi-110095, India,

---

**Abstract:** Humans Are Constantly Exposed To Pesticides Knowingly Or Unknowingly Via Sprays, Drinking Water And Food Products. Carbaryl, A Synthetic 1-Naphthyl-N-Methyl Carbamate Insecticide, Commercially Known As Sevin, Has Been One Of The Most Commonly And Extensively Used Insecticide In Commercial Land, Agriculture, Poultry And Livestock Due To Its Broad Spectrum Activity. However, It Is A Matter Of Concern That Many Of The Food Products That Are Available In The Market Have Been Found To Contain Pesticide Residues Which Could Cause Serious Toxic Effects On Humans. One Of Such Possibilities Could Be An Increasing Risk Of Infertility. The Present Work Was Conducted To Study The Histomorphological Changes In The Testis Produced By The Insecticide Carbaryl And Its Effect On Fertility. Inbred Adult Wistar Albino Rats (*Rattus Norvegicus*) Weighing 150-200gm Were Injected With 200mg/Kg Body Weight Of Carbaryl In Corn Oil Intraperitoneally, Five Days A Week For Thirty Days. Controls Were Maintained. The Animals Of Both The Groups Were Sacrificed Within Twenty Four Hours Of The Last Injection By Perfusion. Testis Was Dissected Out, Paraffin Sections (7 $\mu$ ) Were Cut And Stained For Light Microscopy. The Fertility Index Was Calculated According To Johnson, 1970. Data Was Tabulated And Statistically Analyzed. The Seminiferous Tubules Were Seen To Be Hypocellular With Lack Of Organization Of The Epithelial Cells. Most Tubules Showed Sloughing With Degenerating Cellular Debris In The Lumen. There Was Collection Of Inflammatory Fluid In The Interstitial Tissue Which Caused Thinning Of The Connective Tissue Septa And Compression Of The Seminiferous Tubules. The Fertility Index Of The Experimental Group Was 6.89 $\pm$ 2.57 Which Was Found To Be Statistically Significant ( $P < 0.001$ ). The Above Findings Suggests That The Insecticide Carbaryl Caused Inflammatory And Degenerative Changes In The Testis With Decreased Fertility Index Indicating Hypospermatogenesis Which Further Suggests An Infertile Testis Due To Carbaryl Toxicity.

**Key Words:** Carbaryl, Carbamates, Fertility Index, Infertility, Pesticide, Testis

---

### I. Introduction:

Pesticides are one of the most harmful chemical substances which are added to our environment constantly and have posed a great risk factor to human lives. Carbaryl, a synthetic 1-naphthyl-N-methyl carbamate insecticide is one of the most extensively used insecticide in the recent years in commercial agriculture, poultry, pets, livestock, home and garden pest control, due to its broad spectrum activity. Humans are exposed either directly during manufacture, formulation and application or indirectly via the consumption of fruit and food products contaminated with this pesticide causing various toxicities.<sup>[1]</sup> Carbaryl was the most frequently (58.6%) detected N-methyl carbamate in juice samples studied.<sup>[2]</sup> Occupational hazards like an increase in the incidence of sperm shape abnormality and decreased sperm motility have been documented.<sup>[3, 4]</sup> Congenital malformations and teratogenesis in chicken embryos and beagle dogs<sup>[5, 6, 7, 8]</sup> a follicular hypertrophy of the thyroid<sup>[9]</sup> and necrotic changes in testes and ovaries<sup>[10]</sup> have been observed. Inflammatory infiltrations in the heart and the lungs has been reported by Toś-Luty et al,<sup>[11]</sup> while D. Bigot Lassere et al<sup>[12]</sup> observed tumors in the heterozygous P53 knockout mice after oral administration of carbaryl. Sharma<sup>[13]</sup> and Tripathi et al<sup>[14]</sup> reported changes in the liver enzymes suggesting hepatocellular damage.

The aim of the present work was to study the histomorphological changes in the testis produced by the insecticide carbaryl and its effect on fertility.

### II. Materials And Methods:

Inbred adult Wistar albino rats (150-200gm) were taken from the animal house of University College of Medical Sciences after approval from the local animal ethical committee in accordance with "Principles of Laboratory Animal Care". The animals were divided into two groups. Group-I served as the experiment and Group-II as the control. They were group housed with ad libitum access to food and water. The body weights were recorded before the onset of the experiment and prior to their sacrifice. Group-I rats received 200mg/kg body weight of carbaryl in corn oil intraperitoneally, five days a week for thirty days. The control animals received equal quantity of the vehicle by the same route. The animals were sacrificed within twenty four hours of the last injection. The testis were dissected out and processed. Sections (7 $\mu$ ) were cut and stained with

haematoxylin and eosin stain. Histomorphological changes were studied under light microscopy and Fertility index or Mean Score according to Johnson, 1970<sup>[15]</sup> was calculated by the number of tubules recorded at each score, multiplied by the score and the sum of the products divided by the total number of tubules recorded. Data was tabulated and statistically analysed using Unpaired student's t-test (Table 1).

### III. Results:

Microscopic examination of the experimental rat testis showed seminiferous tubules most of which appeared shrunken and disorganized. There was interstitial tissue edema due to which the tubules appeared shrunken and the interstitial connective tissue septa thinned out (Figure 1B). The number of nuclei in the tubules were decreased giving the tubules a hypocellular and an empty look. Most of the germ cells were seen to be detached from the germinal epithelium in the basal portion and were seen to be irregularly arranged (Figure 2). There was sloughing of immature germ cells into the lumen of the seminiferous tubules due to which the lumen appeared to be filled with cellular debris. (Figure 2,3). The sertoli cells were seen to be widely placed (Figure 3,4). A whole range of hypocellularity of the germinal epithelium gave the tubules a "Sertoli cell only" appearance, with rare cluster of germ cells (Figure 3,4). The seminiferous tubules were scored according to Johnson, 1970.<sup>[15]</sup> The Mean Score or Fertility index of the experimental rat testis was found to be  $6.89 \pm 2.57$  and that of the control was  $9.11 \pm 1.607$ . The Fertility index of the experimental rat testis was found to be significantly decreased ( $P < 0.001$ , Table 1).

### IV. Figures And Tables:

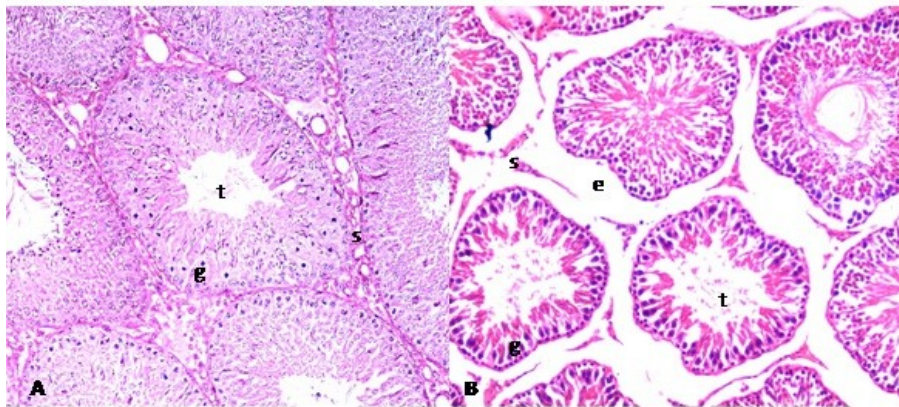


Figure 1. Comparison of the photomicrograph of the transverse section of the control (A) and the experimental (B) rat testis at same magnification: Control(A) shows seminiferous tubules(t) filled with germ cells(g) at various stages of spermatogenesis and the interstitial connective tissue septa showing numerous blood vessels and interstitial cells. While the experimental(B) shows interstitial tissue edema(e) causing thinning of the connective tissue septa(s) and shrinkage of the tubules(t) with a disorganized appearance of the germ cells giving it a hollow and an empty look. (Heamatoxylin and eosin stain 100x).

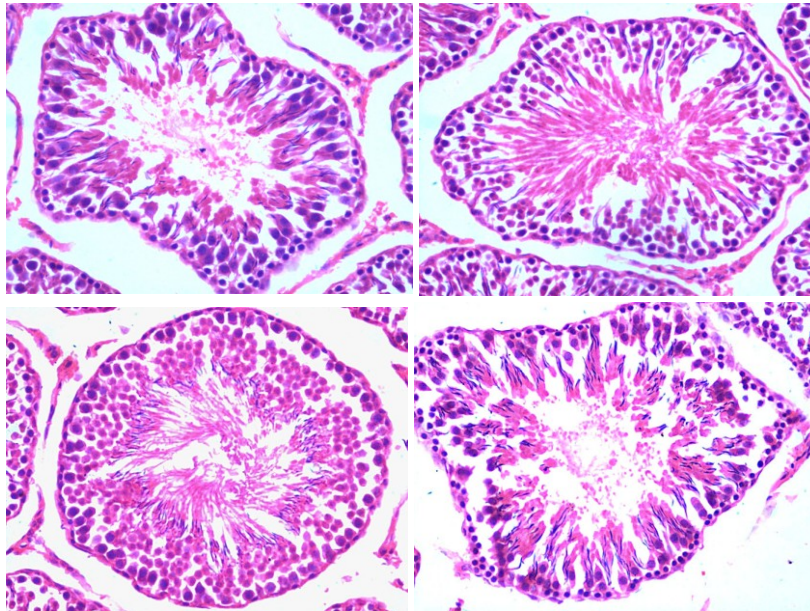


Figure 2: Photomicrograph of transverse section of seminiferous tubules of experimental rat testis showing tubules which appear shrunken due to interstitial tissue oedema with thinned out connective tissue septa. There is also sloughing of the germ cells into tubular lumen due to which the cells appear to be detached from the basal portion and look haphazardly arranged. Heamatoxylin and eosin stain (200X).

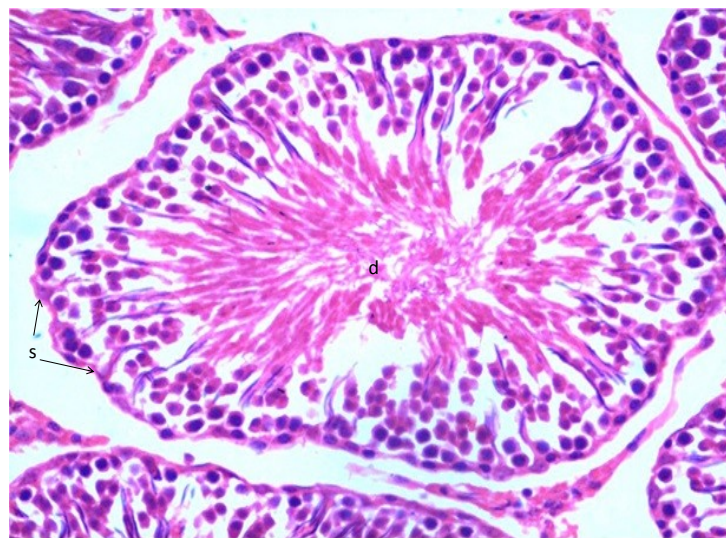


Figure 3. Photomicrograph of the transverse section of the seminiferous tubule of the experimental rat testis which appears to be irregular in shape and shrunken. There is sloughing of the germ cells into the tubular lumen which is seen to be filled with cellular debris(d), while the sertoli cells(s) along the basement membrane appear to be widely placed. The connective tissue septa between the seminiferous tubules appear thinned out due to collection of edematous fluid. Heamatoxylin and eosin stain (200X).



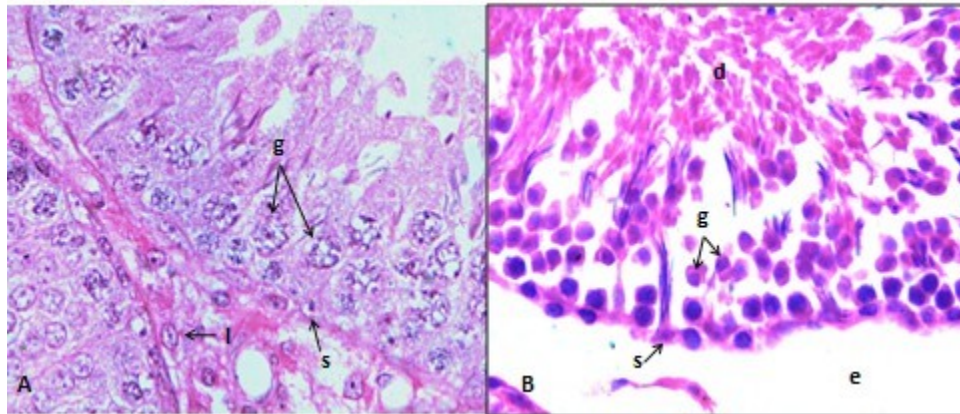


Figure 4. Comparison between photomicrograph of the transverse section of the seminiferous tubules of the experimental (B) rat testis with that of the control group (A). Section (A) shows regularly arranged germ cells (g) and sertoli cells (s) in the control group with an intact connective tissue septa between the tubules; (l-leydig cell). Whereas section (B) shows sloughing of the germ (g) cells into the tubular lumen which is seen to be filled with cellular debris(d) and the sertoli cells(s) along the basement membrane appear to be widely placed. The connective tissue also appear thinned out due to edematous (e) fluid collection. Heamatoxylin and eosin stain (400X).

**Table 1: Comparison of the Fertility Index of the experimental group with that of the control group.**

Seminiferous tubules seen	Score	Control Group		Experimental Group	
		No. of Seminiferous tubules at each score	Total Score	No. of Seminiferous tubules at each score	Total Score
Complete spermatogenesis with many spermatozoa leaving an open lumen .	10	73	730	10	100
Many spermatozoa but germinal epithelium disorganized with marked sloughing and obliteration of lumen.	9	0	0	32	288
Only few spermatozoa but many spermatocytes present .	8	9	72	11	88
No spermatozoa but many spermatids present .	7	8	56	6	42
No spermatozoa but few spermatids seen	6	5	30	10	60
No spermatozoa, no spermatids, but many spermatocytes	5	3	15	11	55
Only few spermatocytes (less than five) with no spermatids	4	2	8	7	28
Spermatogonia, the only germ cell seen	3	0	0	2	6
No germ cell but many sertoli cells present	2	0	0	11	22
No cells seen in tubular cross sections.	1	0	0	0	0
Mean Score			9.11%		6.89%

Normal Mean Score: 8.9

Average Mean Score: 9.3

t = -7.332(Unpaired students t-test)

p<0.001

## V. Conclusions:

In the present study, carbaryl was seen to cause shrinkage of seminiferous tubules along with the widening of interstitial tissue spaces (Figure 1B). This could probably be due the collection of inflammatory fluid in the testis causing interstitial tissue edema, thinning of the connective tissue and compression of the tubules. This are in accordance with the findings of Toś-Luty et al<sup>[11]</sup> who documented widening of interalveolar septa in the lungs and swelling of endothelium of blood vessels on dermal application of carbaryl in rats and those of Smalley et al<sup>[16]</sup> who observed edema of the myelinated tracts in the cerebellum, brainstem and spinal cord . The disorganized appearance of the seminiferous tubules was probably due to the detachment of the immature germ cells from the basal portion of the tubules and their sloughing into the lumen, so that the tubular lumen was seen to be filled with cellular debris (Figure 2). Most of the tubules appeared hypocellular and empty with only few sertoli cells and irregular cluster of germ cells, probably due to the massive sloughing of the cells (Figure 2,3). Similar findings were reported by Shtenberg et al<sup>[17]</sup>, who observed desquamation of the

germinal epithelium and a reduction in the number of germ cells in the testis following chronic administration of carbaryl in rats and suggested that probably the effects could be secondarily to effect on the adenohypophysis. The sertoli cells within the tubules were seen to be widely placed, probably suggesting the loss of the sertoli-sertoli cell tight junctions due to degeneration (Figure 3,4). Degenerative changes were noted in testes and ovaries,<sup>[10]</sup> in stratum spinosum of epidermis and in the purkinje cells of the cerebellum,<sup>[11]</sup> in myocytes,<sup>[16]</sup> and in chick and duck embryos.<sup>[18]</sup> The significant decrease in the fertility index of the experimental rat testis (Table 1) is indicative of a decrease in the spermatogenic activity in the testis, probably due to degeneration and immature sloughing of the germ cells. Similarly, Pant et al<sup>[19]</sup> observed a dose and age-dependent decrease in the sperm motility and sperm count and a significant increase in the abnormal sperms on oral administration of carbaryl in male albino rats, suggesting the adverse effects of carbaryl on spermatogenesis and morphological aberrations. Tripathi et al<sup>[14]</sup> also reported a significant reduction in the reproduction output in snail *Lymnaea* accumulate on sub-lethal exposure to carbaryl.

From the above findings it is being concluded that the insecticide carbaryl caused inflammatory and degenerative changes in the experimental rat testis with significantly decreased fertility index. Since the Mean Score or the Fertility Index, which is taken as a parameter for spermatogenic activity in the testis was found to be statistically significantly decreased, the study is also suggestive of Hypospermatogenesis and an infertile testis due to carbaryl toxicity.

### References:

- [1]. M. Sittig. : Handbook of toxic and Hazardous chemicals and carcinogens. 2nd Ed. Noyes. Publications, Park Ridge, N.J (1985).
- [2]. Rawn DFK, Roscoe V, Krakalvich T, Hanson C. N methyl carbamate concentrations and dietary intake estimates for apple and grape juices available on the retail market in Canada. *Food Additives Contam.* 2004; 21: 555-563.
- [3]. Wyrobeck AJ, Watchmaker G, Gordon L, Wang K, Moore D II, Whorton D. Sperm shape abnormalities in carbaryl-exposed employees. *Environ Health Perspectives* 1981; 40: 255-265.
- [4]. Meeker JD, Ryan L, Barr DB, Herrick RF, Bennett DH, Bravo R, Hauser R. The relationship of urinary metabolites of carbaryl / naphthaline and chlorpyrifos with human semen quality. *Environ Health Perspect*; 112: 1665-1670.
- [5]. Marliac JP, Verrett MJ, Laughlin J Jr, Fitzhugh OG. A comparison of toxicity data obtained for twenty-one pesticides by the chick embryo treated with acute, oral LD-50's in rats. *Toxicol Appl Pharmacol* 1965; 7:490.
- [6]. Ghadiri M, Greenwood DA. Toxicity and biological effects of malathion, phosdrin and sevin in the chick embryo. *Toxicol Appl Pharmacol* 1966; 8: 342.
- [7]. Smalley HE, Curtis JM, Earl FL. Teratogenic action of carbaryl in beagle dogs. *Toxicol and Appl Pharma* 1968; 13: 392-403.
- [8]. Robens JF. Teratologic studies of carbaryl, diazinon, norea, disulfiram and thiram in small laboratory animals. *Toxicol Appl Pharmacol* 1969; 15: 152-163.
- [9]. Stenberg AM. The effect of carbaryl on status of the thyroid gland on status of the thyroid gland of mice receiving artificial or full value diet with different content of iodine. *Gigiena i. Sanitarija* 1970; 8: 119.
- [10]. Stanberg, Otovan. Effect of small doses of carbaryl on the reproductive function of animals in a number of offsprings. *Vaprosi Pitaniija* 1971; 30(1): 41-49.
- [11]. Toš-Luty S, Prezbirowska D, Latuszynska J, Tokarska-Rodak M. Histological and ultrastructural studies of rats. exposed to carbaryl. *Ann Agric Environ Med* 2001; 8: 137-144.
- [12]. Bigot-Lassere D, Chuzel F, Debryue ELM, Bars R, Carmichael NG. Tumorigenic potential of carbaryl in the heterozygous p53 knockout mouse model. *Food Chem Toxicol* 2003; 41: 99-106.
- [13]. Sharma B. Effect of carbaryl on some biochemical constituents of blood and liver of *Clarias batrachus*, a fresh-water teleost. *J Toxicol Sci* 1999; 3: 157-164.
- [14]. Tripathi PK, Singh SK, Yadab RP, Singh D, Singh A. Toxicity of malathion and carbaryl pesticides: effects of some biochemical profiles of the fresh water fish *colisa fasciatis*. *Bill Environ Contam Toxicol* 2004; 72: 592-599.
- [15]. Johnson, S.G. Testicular biopsy score count -- a method for registration of spermatogenesis in human testes. Normal values and results in 335 hypogonadal males. *Hormones* 1:2-25, 1970.
- [16]. Smalley HE, O'Hara PJ, Bridges CH, Radeleff RD. The effects of chronic carbaryl administration on the neuromuscular system of swine. *Toxicol Appl Phramacol* 1969; 15: 152-163.
- [17]. Shtenberg AI, Rybakova MN. Effect of cabaryl on the neuroendocrine system of rats. *Fd Cosmet Toxicol*, 1968, 6: 461-467.
- [18]. Khera KS. Toxic and teratogenic effects of insecticides in duck and chick embryos. *Toxicol Appl Pharmacol* 1966; 8: 345.
- [19]. Pant N, Shankar R, Srivastava SP. Spermatotoxic effects of carbaryl in rats. *Hum Exp Toxicol* 1996; 15: 736-738.