

Apexification of Traumatized Anterior Teeth with Calcium Enriched Mixture (CEM Cement) with one year follow up - A Pilot study

¹Dr. Prasanth Balan, ²Dr. Nileena R kumar ³ Dr. Mridula Parameswaran,
⁴Dr. Ramesh Kumar. M

*1Assistant professor, 2Assistant professor 3Post Graduate Student, 4Professor And Head
1,3,4Department Of Conservative Dentistry & Endodontics , 2.Department of Oral medicine Government
Dental College Medical College
Calicut- 673008*

Abstract: Artificial apical barrier technique for the management of blunder buss canals is being widely used in modern endodontics as compared to the conventional apexification using calcium hydroxide, which inturn is much time consuming. In addition to the current gold standard, MTA, a large number of novel materials are being studied and marketed world wide as pretty promising, effective, and less expensive alternatives for the same. This article describes the successful management of a traumatized and necrotic permanent maxillary central incisor with an open apex using artificial apical barrier technique with a novel endodontic material, Calcium Enriched Mixture (CEM cement) in which remarkable healing of the periapical lesion could be achieved within 6 months.

Key Word: Artificial Apical Barrier, Blunder Buss Canal, Calcium Enriched Mixture, CEM Cement

I. Introduction

Successful management of necrotic teeth with blunder buss canals often poses various difficulties to the endodontist as far as the treatment plan and prognosis is concerned. The management of a nonvital tooth with an open apex consists of the induction of a natural or artificial apical barrier which can act as a stop for the obturating material. Apexification is defined as 'a method to induce a calcified barrier in a root with an open apex or the continued apical development of an incomplete root in teeth with necrotic pulp'(1). Traditionally a thick mix of calcium hydroxide packed against the apical soft tissue with a plugger or thick point is used to initiate hard tissue formation. But there are certain disadvantages associated with this conventional method. The average time taken for apexification to complete using Calcium hydroxide is 6-24 months and this prolonged time period can promote bacterial recontamination(2). Previous studies have described the disadvantages of Calcium hydroxide apexification such as failure to control infection, recurrence of infection and cervical fracture. Thus, although the apexification technique with Calcium hydroxide has enjoyed considerable tooth preserving success, the many disadvantages of this protracted treatment have justified a search for alternatives, such as artificial apical barrier techniques, with their potential for more rapid treatment; and regeneration techniques, with their potential for continued tooth development.

Artificial apical barrier technique consists of a barrier material which is packed into the apical portion of the root canal against which the obturating material can be condensed. Clinicians have tried several materials to form apical barrier in the past. These include, calcium hydroxide powder, calcium hydroxide mixed with different vehicles, collagen, tricalcium phosphate, osteogenic protein, bone growth factor and oxidised cellulose.

Among the various materials used as artificial apical barrier, Mineral Trioxide Aggregate (MTA) is currently considered as one of the most promising material. MTA introduced by the Loma Linda University has several advantages over Calcium hydroxide which includes superior biocompatibility, cementogenic properties, ability to set in the presence of moisture and blood, superior sealing ability, high pH, radiopacity and its ability to aid in the release of bioactive dentin matrix proteins(3).

However previous studies reveal that MTA has some drawbacks as well. It has shown high solubility, demonstrating 24% loss after 78 days of storage in water(4). A significant downside to MTA is the prolonged setting time of approximately 2 hours and 45 minutes as well as the difficult handling characteristics(5,6). MTA is very expensive. One gram of MTA powder costs approximately the same as 24 grams of calcium hydroxide base/catalyst paste, making MTA much less cost effective per use(7). The antimicrobial activity of MTA is questionable (8). The presence of iron in the grey MTA formulation may darken the tooth(9).

Recently, a new endodontic cement named Calcium Enriched Mixture (CEM) has been introduced by the Iranian Center for Endodontic Research Tehran, Iran(2008), which appears to have an appropriate setting time, handling characteristics, chemical properties, colour and sealing ability. Major components of CEM cement powder are 51.75% wt CaO, 9.53% wt SO₃, 8.49% wt P₂O₅, 6.32% wt SiO₂, and minor components are Al₂O₃

> Na₂O > MgO > Cl as essential constituents, which provides a bioactive calcium and phosphate enriched material when mixed with a water base solution. CEM cement has similar pH, increased flow, but decreased setting time (< 1 hour), film thickness, and estimated price than MTA(10). The clinical use of CEM cement is approved by Iranian Ministry Of Health And Medical Education and is used for direct pulp capping, furcation repair, external root resorption repair, root end filling, apexogenesis and apexification.

This article describes the successful management of a symptomatic, traumatized, immature, necrotic permanent maxillary central incisor having a wide open apex using Calcium Enriched Mixture as an artificial apical barrier.

Methodology

A healthy 22 year old male patient was referred to the Department Of Conservative Dentistry & Endodontics, Government Dental College, Calicut on January 2011 with a history of severe pain and swelling in relation to the upper front tooth region for the past 2 weeks, the onset of which was after 1 month of wearing an upper retraction plate. The patient had a history of trauma to the permanent maxillary left central incisor at the age of 8 yrs. Clinical examination revealed Ellis class 4 fracture of upper left permanent central incisor with acute dental alveolar abscess and was tender on palpation. The involved tooth was mildly discoloured and had Grade I mobility. Thermal and electric pulp test results were negative. Cold test with Endofrost Cold Spray (Roeko; Coltene Whaledent, Germany) elicited no response, when compared with the contralateral and adjacent teeth. Radiographic examination revealed immature necrotic permanent upper left central incisor with wide open apex and a moderately large periapical radiolucency. (Figure 1)

After complete explanation of the treatment procedure, risks, and benefits, an informed consent was obtained from the patient. After rubber dam isolation under local anesthesia, emergency access opening was done by using a diamond coated fissure bur and drainage from the canal was facilitated. Copious irrigation of the root canal was done using 5.25% NaOCl and gentle filing done with a No.50 size stainless steel K file (Dentsply, Maillefer). Working length was established. Calcium hydroxide intracanal medicament (RC Cal, Prime Dental) was placed for 2 weeks. The patient was recalled after 2 weeks. There was no postoperative pain or discomfort during the inter appointment period and the involved tooth was asymptomatic. The access cavity was reopened, copious irrigation was done with 0.2 % Chlorhexidine solution, the root canal was dried with sterile paper points. CEM cement powder and liquid (BioniqueDent, Tehran, Iran) was mixed to a thick creamy consistency in 3:1 ratio and was gently condensed to the working length with the aid of a no. 50 size finger plugger (Figure 2). A moist cotton pellet was placed in contact with CEM for 1 hr following which the cotton pellet was removed and the setting of CEM was checked. Backfilling was done at the same appointment using thermoplasticized gutta percha ((E & Q Plus, Meta Bio Med). (Figure 3) Tooth was restored with composite resin. Follow up examinations were carried out at 1 month, 3 months, 6 months and 1 year after apexification.

During follow up periods the involved tooth was asymptomatic with no clinical evidence of periradicular disease including sensitivity to percussion/ palpation, presence of soft tissue swelling/ redness or presence of sinus tract. Post operative radiographs at 6 months and 1 year suggested remarkable healing of the osseous lesion. (Figure 4 and 5)

III. Discussion

Complete destruction of Hertwig's epithelial root sheath results in cessation of normal root development. This does not however mean that there is an end to deposition of hard tissue in the region of the root apex(11). Once the sheath has been destroyed there can be no further differentiation of odontoblasts. However, hard tissue can be formed by cementoblasts that are normally present in the apical region and by fibroblasts of the dental follicle and periodontal ligament that undergo differentiation after the injury to become hard tissue producing cells (12). It has been postulated that the material of choice for apexification should have a cemento conductive potential(13).

As the calcium ions from the calcium hydroxide dressing do not come from the calcium hydroxide but from the bloodstream the mechanism of action of Calcium hydroxide in induction of an apical barrier remains controversial(11). Torneck et al. reported that a bone like material was deposited on the inner walls of the root canal after Calcium hydroxide apexification (14) whereas histological examination reveals that the barrier is porous(15). Previous studies have suggested that the longer the tooth has been necrotic, the less likely that Calcium hydroxide will lead to apical closure.

According to a study done to analyze the physical properties and chemical compositions of Calcium Enriched Mixture (CEM cement) and compare them with Mineral Trioxide Aggregate (MTA), the results concluded that cementogenic activity of MTA is because of its release of an abundance of calcium ions, which interact with phosphate groups in the surrounding tissue fluid to form hydroxyapatite on the surface of white and gray MTA(16). Therefore, the clinical success of MTA can be attributed to its biocompatibility (17).

On the other hand, Electron Probe Micro Analysis (EPMA) revealed endogenous phosphate in CEM.

Therefore, it seems reasonable to suspect that the presence of significant calcium and phosphate ions in CEM is most likely to form the hydroxyapatite compared with white MTA. MTA does not contain endogenous phosphorus as does CEM cement. (17) CEM cement as a root-end filling material, in contrast to MTA, when stored in normal saline forms hydroxyapatite over the material, surrounding dentine and their boundaries, resulting in the creation of a second seal(18).

The high alkalinity of CEM is comparable with white MTA, a favourable property related to its bactericidal properties providing an excellent tight seal, and biocompatibility. This cement has antibacterial effects better than MTA and comparable with calcium hydroxide; it has also low cytotoxic effect on different cell lines similar to MTA(17,19).

During and after mixing with its liquid, hydration reactions take place, producing Calcium hydroxide (CH). This production is mostly because of the reactions involving calcium silicates, calcium phosphate, and calcium oxide in addition to the presence of CH. CH dissociated into calcium and hydroxyl ions, increases the pH and calcium concentration(17).

Studies have revealed that the cementogenic properties of CEM cement is similar to that of MTA when used as a root end filling material. The successful use of CEM as an artificial apical barrier has been reported in a case series in which successful clinical and radiographic outcomes was noted in an average follow up period of 14.5 months. Radiographically complete osseous healing of the lesions was noted in all of the teeth studied(20).

IV. Conclusion

In the light of previous studies that are conducted on Calcium Enriched Mixture cement, the successful treatment outcomes in majority of the cases reported, as well as considering the various advantages of this biomaterial over MTA such as low cost, improved colour, handling and bactericidal effects, Calcium enriched mixture could be used as successful artificial apical barrier for the treatment of teeth with blunderbuss canals. However more clinical studies with longer follow up periods are recommended.

Acknowledgement

My sincere gratitude to Dr. Saeed Asgary and Dr. Ali Nosrat of Iranian Centre For Endodontic Research (ICER) who provided Calcium Enriched Mixture (CEM cement) and for their valuable guidance and support for this study.

References

- [1]. American Association of Endodontists. Glossary of endodontic terms, 7th edn. Chicago: American Association of Endodontists; 2003.
- [2]. Camp. J, Fuks A Pediatric Endodontics: Endodontic Treatment For The Primary And Young Permanent Dentition. In: Cohen S, Hargreaves K, Keiser K editors, Pathways of the Pulp 9th Edition. St Louis Mosby Elsevier; 2006.p 822-82
- [3]. Parirokh M, Torabinejad M., Mineral Trioxide Aggregate: A Comprehensive Literature Review- Part I: Chemical physical and Antibacterial properties, J Endod 2010;36:16-27
- [4]. Fridland M & Rosado R (2003) Mineral Trioxide aggregate (MTA) solubility and porosity with different water-to-powder ratios. Journal of Endodontics 29(12) 814-817.
- [5]. Torabinejad M, Hong C, McDonald F & Pitt Ford T (1995) Physical and chemical properties of a new root-end filling material. Journal of Endodontics 21(7) 349-353.
- [6]. Islam I, Kheng Chng H & Jin Yap A (2006) Comparison of the physical and mechanical properties of MTA and Portland cement. Journal of Endodontics 32(3) 193-197.
- [7]. TJ Hilton, Keys to Clinical Success with Pulp Capping: A Review of the Literature Operative Dentistry, 2009, 34-5, 615-625
- [8]. Asgary S, Kamrani F, Antibacterial Effects Of Five Different Root Canal Sealing Materials. J Oral Sci 2008;50:469-74
- [9]. Aeinehchi M, Eslami B, Ghanbariha M & Saffar A (2002) Mineral Trioxide Aggregate (MTA) And Calcium Hydroxide As Pulp-Capping Agents In Human Teeth: A Preliminary Report. International Endodontics Journal ;36: 225-231.
- [10]. Asgary S, Shahabi S, Jafarzadeh T, Amini S, Kheirieh S(2008) The Properties Of A New Endodontic Material. Journal of Endodontics; 34: 990-3 Rafter M. Apexification: A Review. Dent Traumatol 2005; 21: 1-8.
- [11]. Torneck CD. Effects Of Trauma To The Developing Permanent Dentition. Dent Clin N Am 1982;26:481-504.
- [12]. Shabahang S, Torabinejad M, Boyne P, Abedi H, McMillan P. A Comparative Study Of Root End Induction Using Osteogenic Protein -1, Calcium Hydroxide, And Mineral Trioxide Aggregate In Dogs. J Endod 1999;25:1-5
- [13]. Torneck CD, Smith JS, Grindall P. Biological Effects Of Endodontic Procedures On Developing Incisor Teeth. IV. Effect Of Debridement Procedures And Calcium Hydroxide CPCP Paste In The Treatment Of Experimentally Induced Pulp And Periapical Disease. Oral Surg 1973;35:541-54.
- [14]. Steiner JC, Van Hassel HJ. Experimental Root Apexification In Primates. Oral Surg 1971;31:409-15.
- [15]. Sarkar NK, Caicedo R, Ritwik P, Moiseyeva R, Kawashima I. Physicochemical Basis Of The Biologic Properties Of Mineral Trioxide Aggregate. J Endod 2005;31:97-100.
- [16]. Saeed Asgary, DDS, MS, Sima Shahabi, DDS, PhD The Properties of a New Endodontic Material (J Endod 2008;34:990-993)
- [17]. Asgary S, Eghbal MJ, Parirokh M (2008) Sealing Ability Of A Novel Endodontic Cement As A Root-End Filling Material. Journal of Biomedical Materials Research Part A 87, 706-9.
- [18]. Asgary S, Parirokh M, Eghbal MJ, Ghoddsi J (2006) SEM Evaluation Of Pulp Reaction To Different Pulp Capping Materials In Dog's Teeth. Iranian Endodontic Journal 4, 117-22.
- [19]. Nosrat A, Asgary S, Eghbal M J, Ghoddsi J, Bayat -Movahed S. Calcium Enriched Mixture Cement As Artificial Apical Barrier: A Case Series. J Conserv. Dent 2011;14:427-31

Figure 1
Preoperative view

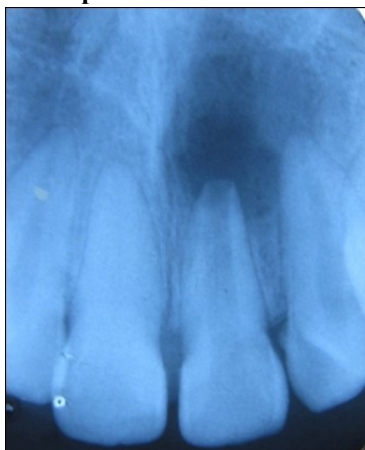

Figure 2
Apexification with CEM

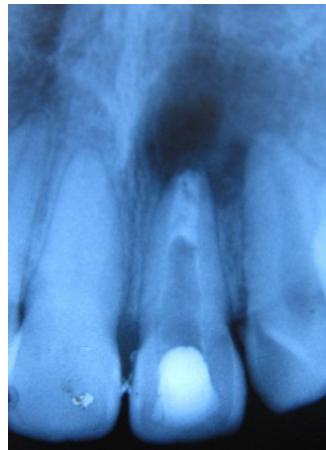


Figure 3
After obturation

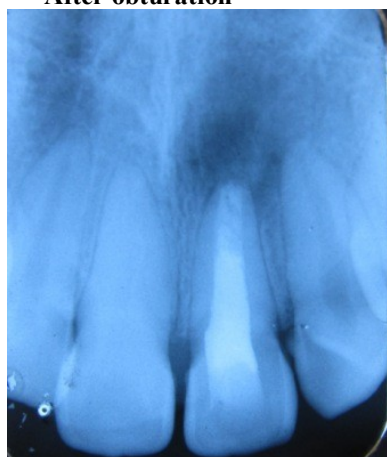


Figure 4
6 months postoperative

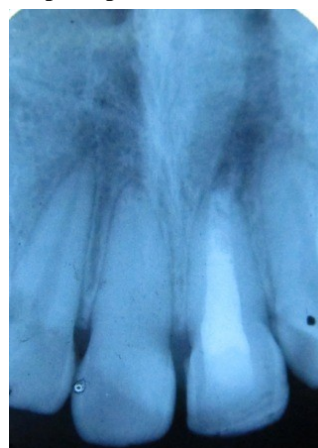

Figure 5
1 year postoperative view

