

## Gingival Enlargement Leading To the Diagnosis Of Acute Lymphoblastic Leukemia In An 8-Year Old Girl: A Case Report

<sup>1</sup>Dr. Neha Vashisht, <sup>2</sup>Dr. A. Ravi Kiran, MDS, <sup>3</sup>Dr. Divy Vashisht, MDS,  
*Oral Medicine and Radiology, Prosthodontics*

---

**Abstract: Background:** oral complications may be leukemia's first presentation. Aim: to present a case of a young girl with gingival enlargement that led to the diagnosis of acute lymphoblastic leukemia is reported. Conclusion: dentists must be able to clearly recognize oral physiological characteristics, and, when identifying changes of normalcy, to fully investigate it requesting additional tests or referring the patient to specialized professionals.

**Keywords:** gingival enlargement, diagnosis, acute lymphoblastic leukemia

---

### I. Introduction

Leukemia is a disease of mesenchymal origin in which there is an abnormal proliferation or an increased lifespan of myeloid or lymphoid cells. <sup>1</sup> Leukemic cell multiplication at the expense of normal hemopoietic cell lines cause marrow failure, depressed blood cell count (cytopenia), and death as a result of infection, bleeding, or both. <sup>1</sup> Causes of leukemia are poorly defined. However, radiation exposure, chromosomal abnormalities, chemical injuries and viral infections have been implicated. <sup>2</sup> According to the clinical behavior, leukemias are classified into acute or chronic forms and characterized as lymphocytic and myelocytic, referring to its histogenetic origin. Acute lymphoid leukaemia (ALL) and acute myeloid leukemia (AML) are further subdivided within the French-American British (FAB) classification according to their degree of differentiation along cell lines and extent of cell maturation. FAB classification of AML includes eight categories, designated M0 to M7, based on morphology and cytochemistry. <sup>1</sup> A decrease in the production of erythrocytes, granulocytes and platelets give rise to the clinical signs of weakness, fatigue, increased susceptibility to infection and hemorrhage. As compared to acute leukemia, oral changes are non specific in patients with chronic leukemia. <sup>3</sup> Gingival enlargement is reported to be the most consistent symptom that directs the patient to seek early dental consultation, leading to a diagnosis of leukemia.

### II. Case Report

An 8-year-old female patient reported to the department of Oral Medicine and Radiology with the chief complaint of asymptomatic swelling of both sides of palate, with rapid development in two weeks time. There wasn't significant medical or family history. Intraoral examination revealed bucco-palatal expansion of posterior palate present bilaterally, more prominent on the right side of palate. (Figure 1, 2) The mucosa overlying was bulbous and on palpation, it was tender and firm in consistency. Grade I mobility of all maxillary teeth was present. Gingival enlargement was seen in right posterior mandibular region also. (Figure 3) Imaging tests did not show any significant changes. (Figure 4, 5)

Hematological investigations were performed. Serum calcium, phosphorus and alkaline phosphatase were under normal limits. Thus, ruling out any bony pathology. Blood report revealed hemoglobin (Hb) values of 10 gm %, red blood cells (RBCs) count of 3.3 million/mm<sup>3</sup>, white blood cells (WBCs) count of 36, 000/mm<sup>3</sup> and platelet count 40,000/mm<sup>3</sup>. These findings suggested of **leucocytosis and thrombocytopenia**.

Blood smear examination was done, which revealed leukocytosis with 705 of the population being blast cells. Individual blast cells were 30-40 microns in diameter, with centrally placed nucleoli. Chromatin was coarsely clumped. The cytoplasm was scanty and agranular. Associated RBCs were normocytic normochromic and platelets were decreased in number. On the basis of these findings, impression of **Acute Lymphoblastic Leukemia with thrombocytopenia** was given.

Bone marrow aspiration was performed, which revealed presence of pre-B cell. Thus final diagnosis of gingival hyperplasia due to **Acute Lymphoblastic Leukemia** was made. Our patient revealed swelling, which was actually extensive gingival hyperplasia. The patient was immediately admitted to the oncology centre and treatment was started with three-drug induction consisting of vincristine, prednisone plus L-asparaginase, intrathecally.

### III. Discussion

Oral lesions may be the presenting feature of acute leukemias and are therefore important diagnostic indicators of the disease. Such lesions may occur due to direct leukemic infiltration of tissues, or be secondary to immunodeficiency, anemia and thrombocytopenia. Typical oral manifestations of acute leukemias include gingival enlargement, local abnormal color or gingival hemorrhage, petechiae, ecchymoses, mucosal ulceration and oral infections.<sup>4</sup>

Gingival overgrowth has several causes, including poor oral hygiene, drugs, systemic illnesses and neoplastic conditions. The presenting characteristics of gingival enlargement vary according to its etiology. The gingiva shows slow growth rate and appear pink with firm consistency with minimal inflammatory component when it is genetically induced. In case of blood dyscrasias, the gingiva appears soft and edematous with tenderness and bleeding tendency.<sup>3</sup> Gingival tissues are considered more susceptible to leukemic cell infiltration because of their microanatomy and expression of endothelial adhesion molecules which enhance infiltration of leukocytes.

In a study by Dreizen et al., 1983, gingival enlargement was observed in acute myelogenous leukemia (AML) with a frequency of 3% to 5% among 1,076 patients receiving anti-leukemia chemotherapy at a referral centre. Gingival hyperplasia is most commonly seen with the AML subtypes acute monocytic leukemia (M5) (66.7%), acute myelomonocytic leukemia (M4) (18.5%), and acute myelocytic leukemia (M1, M2) (3.7%).<sup>5</sup> As reports of gingival enlargement in ALL population are scarcely reported in literature, our case could be considered as a rare one. Gingival enlargement is more common in acute than chronic leukemia, in adults and in people with “aleukemia” or “subleukemic” forms of leukemia.<sup>6</sup> Leukemia cell gingival infiltrate is not observed in edentulous individuals, suggesting that local irritation and trauma associated with the presence of teeth may play a role in the pathogenesis of this abnormality.<sup>5</sup>

Generally, gingival enlargement resolves completely or at least partly with effective leukemia chemotherapy.<sup>6</sup>

### IV. Conclusion

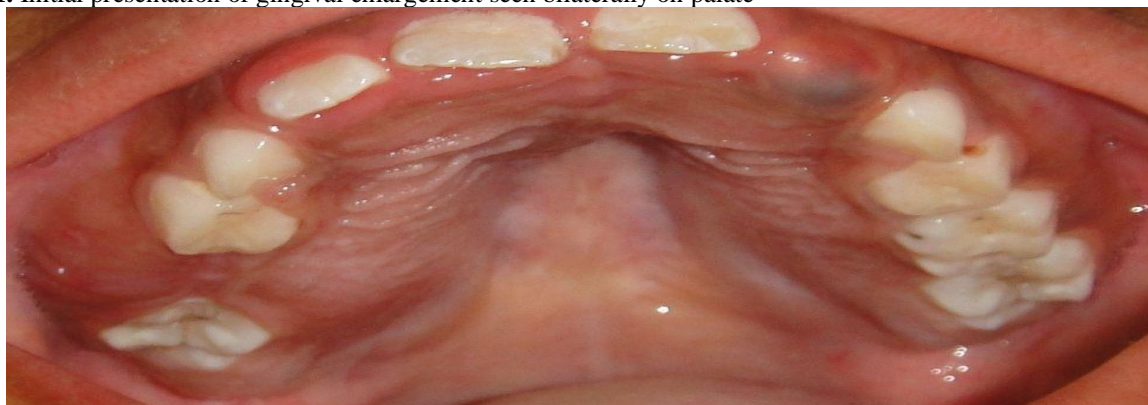In conclusion, the fact that gingival alterations are sometimes the first manifestations of the disease implies that dental professionals must be sufficiently familiarized with the clinical manifestations of systemic diseases to ensure prompt detection and referral. Considering the acuteness of this disease, early diagnosis and referral of leukemic patients should be done for better outcome of this fatal condition.<sup>7</sup>

### References

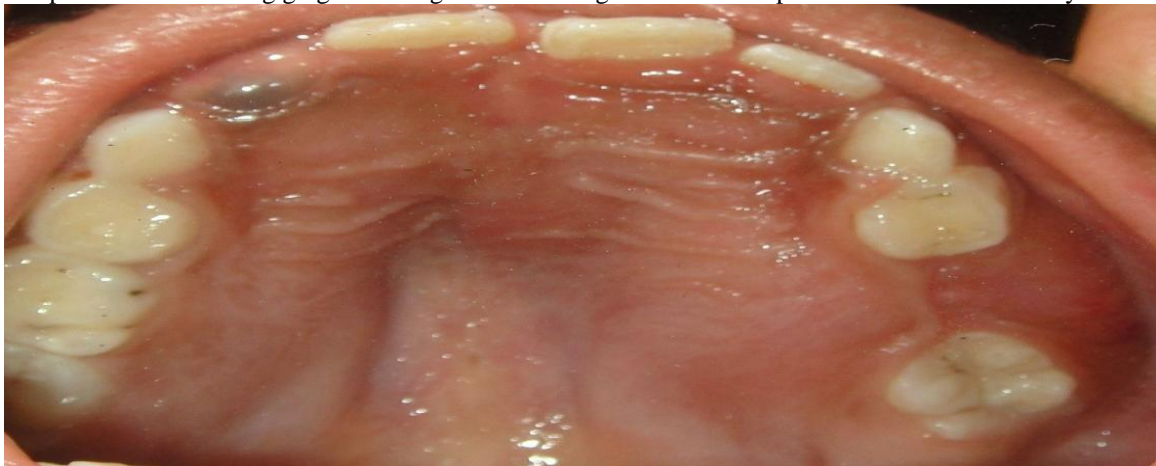
- [1]. Vernon P. Burke, James M. Startzell. The Leukemias. *Oral Maxillofacial Surg Clin N Am* 2008; 20: 597–608
- [2]. Cotran RS, Kumar V, Collins T. *Robbin’s Pathologic Basis of Disease*. 6th edn. Philadelphia: WB Saunders Company 1999: 675- 678.
- [3]. Serhat Demirel, Hakan Özdemir. Gingival Hyperplasia as an Early Diagnostic Oral Manifestation in Acute Monocytic Leukemia: A Case Report. *European Journal of Dentistry* 2007; 1
- [4]. Santosh Patil, Nitin Kalla. Leukemic gingival enlargement: a report of two Cases. *Archives of Orofacial Sciences* 2010; 5: 69-72
- [5]. Dreizen S, McCredie KB, Keating MJ and Luna MA. Malignant gingival and skin “infiltrates” in adult leukemia. *Oral Surg Oral Med Oral Pathol* 1983; 55: 572-579
- [6]. Curtis L. Cooper, Ruth Loewen. Gingival Hyperplasia Complicating Acute Myelomonocytic Leukemia. *J Can Dent Assoc* 2000; 66:78-9
- [7]. Mahesh Chavan, Arun Subramaniam. Acute myeloid leukemia: a case report with palatal and lingual gingival alterations. *Braz J Oral Sci* January/March 2010; 9: 1

### Figures

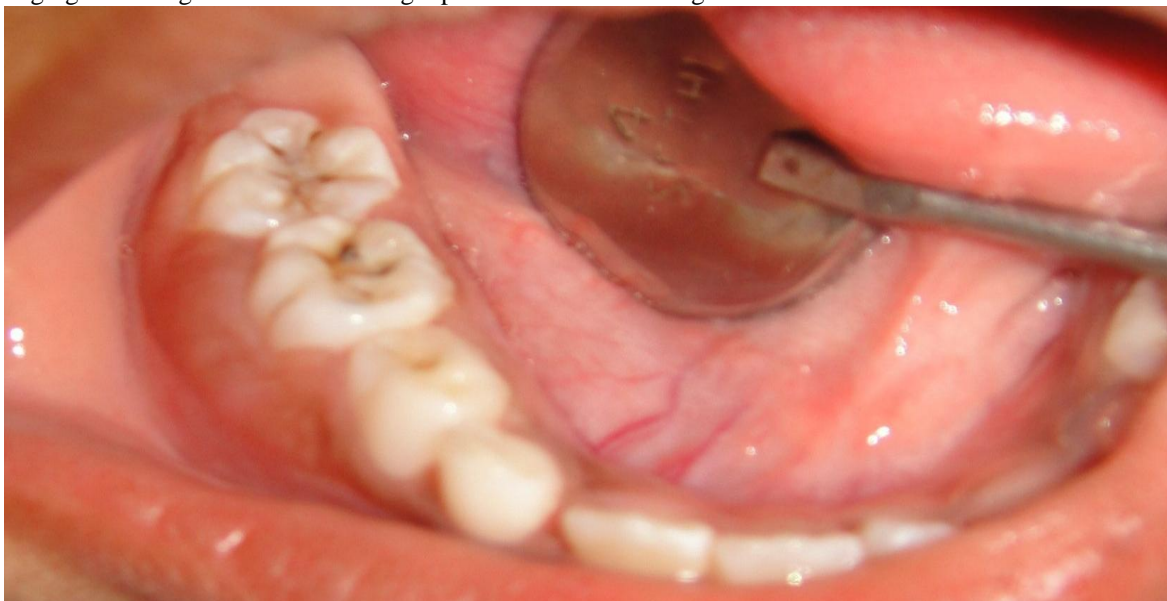
1. Initial presentation of gingival enlargement seen bilaterally on palate



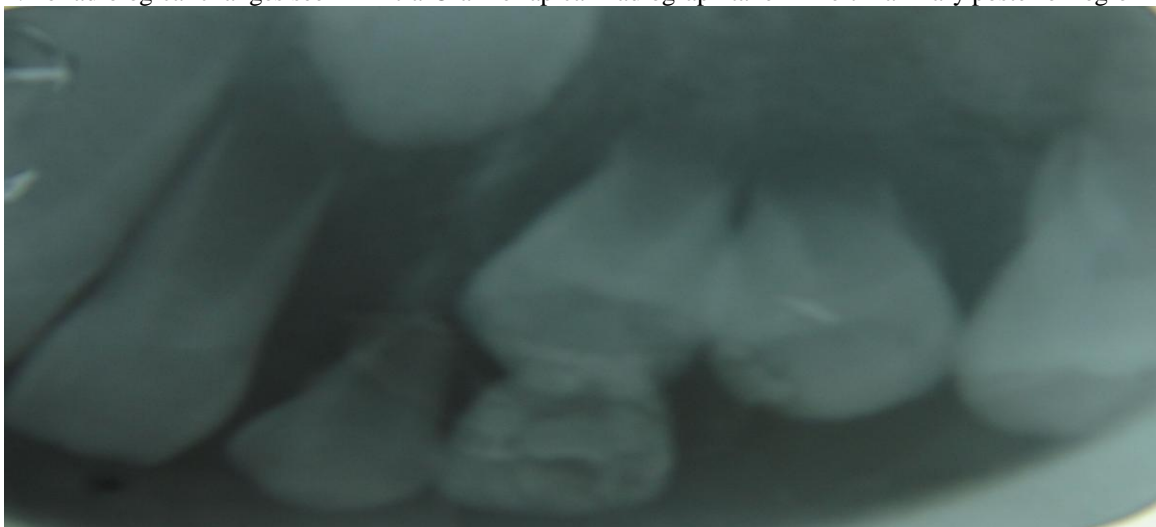
2. a palatal view showing gingival enlargement covering the buccal and palatal surfaces of maxillary teeth



3. gingival enlargement seen in the right posterior mandibular region



4. no radiological changes seen in Intra-Oral Periapical Radiograph taken in left maxillary posterior region



5. no radiological changes seen in maxillary occlusal view

