

Retrobulbar Optic Neuritis Revealing An Optic Nerve Sheath Meningioma: A Case Report

J. Boucht, S. Najim, Z. Ferjouchia, M. Jilla, R. Belfkih

Abstract

Objective: The aim of reporting this case of an atypical presentation of an optic nerve sheath meningioma mimicking optic neuritis is to highlight the importance of differential diagnosis and early imaging in order to avoid delays in management.

Methods: A descriptive study of a case of optic nerve sheath meningioma revealed by optic neuritis. Data were collected retrospectively from the clinical records and MRI findings, along with a review of the literature.

Results: The patient presented with decreased visual acuity initially suggestive of optic neuritis. The atypical clinical course and MRI findings led to the diagnosis of optic nerve sheath meningioma, resulting in a revision of the diagnosis and appropriate management.

Discussion: Optic nerve sheath meningioma is a rare cause of compressive optic neuropathy that can mimic optic neuritis. The distinction relies on clinical features (progressive course, limited recovery) and especially orbital MRI, which typically shows characteristic perineural enhancement. This case highlights the importance of considering a tumoral etiology in atypical presentations to avoid diagnostic delay and to guide appropriate management.

Conclusion: Optic nerve sheath meningioma can mimic optic neuritis. Any atypical presentation should prompt the search for a compressive cause, particularly using MRI, in order to avoid diagnostic delay and optimize patient management.

Date of Submission: 23-04-2026

Date of Acceptance: 03-05-2026

I. Introduction

Optic nerve sheath meningiomas (ONSMs) are rare tumors arising from the arachnoid cap cells surrounding the optic nerve. They account for approximately 1–2% of all intracranial meningiomas and 2–3.5% of orbital tumors. After gliomas, they represent the second most common primary tumor of the optic nerve.

Although typically benign and slow-growing, their progressive expansion leads to compression of the optic nerve, resulting in visual impairment that is often irreversible in the absence of appropriate management. Therefore, visual prognosis is closely related to the timeliness of diagnosis and the therapeutic strategy implemented.

The present case illustrates an atypical and initially misleading clinical presentation of ONSM, highlighting the diagnostic challenges and the importance of considering a tumoral etiology in any unusual optic neuropathy.

The aim of this report is to describe an atypical clinical presentation of ONSM revealed by features suggestive of retrobulbar optic neuritis, and to analyze the clinical and radiological findings that led to the correct diagnosis. This work also seeks to emphasize the challenges of the differential diagnosis between inflammatory and compressive optic nerve disorders, and to underline the importance of early orbital imaging with appropriate sequences in atypical presentations, in order to avoid diagnostic delay and optimize therapeutic management and visual outcomes.

II. Methods

This is a retrospective descriptive study reporting a case of optic nerve sheath meningioma (ONSM) initially presenting with features suggestive of optic neuritis. Data were collected from the patient's medical records, including medical history, clinical presentation, ophthalmologic examination, response to initial treatment, and imaging findings.

Radiological assessment was primarily based on contrast-enhanced brain and orbital magnetic resonance imaging (MRI), allowing detailed evaluation of the lesion's characteristics, location, extent, and its relationship to the optic nerve. Clinical and radiological findings were then compared with data from the literature in order to discuss the diagnostic and therapeutic particularities of this case.

III. Results

A 45-year-old woman with no significant past medical history was admitted for decreased visual acuity in the left eye, associated with pain on ocular movement. Symptoms had been evolving for one month with a relapsing–remitting pattern, initially suggestive of inflammatory retrobulbar optic neuritis.

Ophthalmologic examination was unremarkable. Brain and orbital magnetic resonance imaging (MRI) focused on the optic nerves demonstrated a hyperintense signal on T2-weighted and fat-suppressed sequences, with enhancement after gadolinium administration. The lesion was located along the sheath of the left optic nerve, sparing the nerve itself and without associated parenchymal involvement, consistent with an optic nerve sheath meningioma (Figure 1).

Cerebrospinal fluid analysis, including the assessment of oligoclonal bands, was negative.

Given the posterior location of the lesion, making surgical intervention difficult, a conservative approach with regular clinical and radiological follow-up was adopted, with consideration of radiotherapy in case of disease progression.

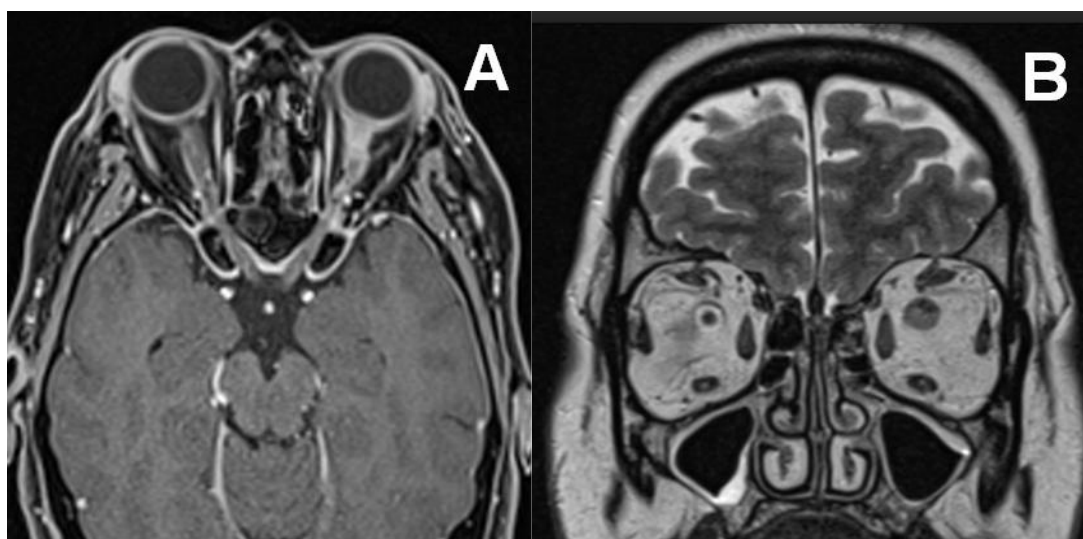


Figure 1:

- A. Contrast-enhanced axial brain MRI showing a left optic nerve sheath meningioma.
- B. Coronal T2-weighted brain MRI showing a left optic nerve sheath meningioma

IV. Discussion

Optic nerve sheath meningiomas (ONSMs) show a marked female predominance, with approximately 80% of reported cases occurring in women, suggesting a potential hormonal influence in their pathophysiology.

Clinically, progressive visual acuity decline is the most common presenting symptom. This course is typically slow, insidious, and non-reversible, in contrast to the relapsing–remitting pattern observed in our patient, which initially led to an erroneous diagnosis of inflammatory optic neuritis. This atypical presentation highlights the difficulty in distinguishing between compressive and inflammatory optic neuropathies.

Other clinical features may include proptosis, oculomotor disturbances due to tumor extension, visual field defects, and optic disc edema on fundoscopic examination. Bilateral involvement may also occur, particularly in more extensive forms.

Magnetic resonance imaging (MRI) plays a central role in the diagnosis. It allows visualization of the lesion arising from the optic nerve sheath while demonstrating the optic nerve within the mass, a characteristic appearance sometimes described as the “tram-track” sign. Lesions may appear in tubular, fusiform, or exophytic forms, with homogeneous and well-defined enhancement after gadolinium administration. The typically isointense signal on T1-weighted images and mildly hyperintense signal on T2-weighted images may contribute to diagnostic and therapeutic delay, as reported in the literature, particularly if imaging is not performed or interpreted by an experienced specialist. The use of gadolinium enhancement, fat-suppressed sequences, and dedicated imaging of the anterior visual pathways is essential for accurate diagnosis.

Management of ONSMs remains controversial and depends on several factors, including lesion location, clinical course, and visual impairment. Surgery may be considered in selected accessible cases but is often limited by the risk of visual deterioration. Radiotherapy, particularly conformal or stereotactic techniques, represents an effective alternative, often allowing stabilization of visual function. In certain situations, especially in slowly progressive lesions or those in surgically inaccessible locations, a conservative approach with close clinical and radiological monitoring may be adopted, as in our patient, with delayed treatment indicated in case of progression.

This case underscores the importance of thorough clinical and radiological assessment to avoid misdiagnosis and to optimize therapeutic decision-making.

V. Conclusion

Optic nerve sheath meningiomas (ONSMs) are histologically benign tumors but may lead to significant visual impairment. Their diagnosis should be considered in any case of decreased visual acuity, particularly when the presentation is atypical. It relies primarily on imaging with dedicated sequences. Therapeutic management remains challenging; however, fractionated radiotherapy appears to provide disease stabilization in cases localized to the orbit.

References

- [1]. M. Bouyon Et Al , Méningiome Et Neuropathie Optique : Un Piège Diagnostique, Journal Français D'ophtalmologie, Vol 36 - N° 3, P. 221-229 - Mars 2013, Doi : 10.1016/J.Jfo.2012.07.001
- [2]. Z. Hammoumi Et Al, Les Tumeurs Du Nerf Optique: A Propos De 18 Cas, Société Française D'Ophtalmologie, 2021
- [3]. T. Ben Salem Et Al, Profil Clinique Et Etiologique Des Neuropathies Optiques Rétrobulbaires Dans Un Service De Médecine Interne, La Revue De Médecine Interne, Vol 38 - N° S1 P. A191-A192 - Juin 2017. Doi :10.1016/J.Revmed.2017.03.278
- [4]. Mouton S Et Al, Optic Nerve Sheath Meningioma. Experience In Lyon With Twenty Patients. Rev Neurol (Paris). 2007 May;163(5):549-59. Doi: 10.1016/S0035-3787(07)90461-0.Pmid: 17571023
- [5]. M. Bouyon Et Al, Méningiome Et Neuropathie Optique : Un Piège Diagnostique optic Neuropathy And Meningioma : A Diagnostic Trap, Journal Français D'ophtalmologie Volume 36, Issue 3, March 2013, Pages 221-229, Doi.Org/10.1016/J.Jfo.2012.07.001
- [6]. D. Grivet Et Al, Atypical Clinical Presentation Of An Optic Nerve Sheath Meningioma, Journal Français D'ophtalmologie Volume 30, Supplement 2, April 2007, Page 2s317, Htpps://Doi.Org/10.1016/S0181-5512(07)80398-6
- [7]. A. Alphandari Et D. Milea, Is It Optic Neuritis? Differential Diagnosis, Revue Neurologique Volume 166, Issue 12, December 2010, Pages 970-977, Htpps://Doi.Org/10.1016/J.Neurol.2010.09.002