

Custom-Made Polymethyl Methacrylate (PMMA) Cranioplasty Using a Conventional Prosthodontic Technique: A Clinical Case Report

Dr. Mitumani Biashya¹, Dr. Jitendra Khetan², Dr. Shiv Kumar³, Dr. Sk Afreen⁴
Post Graduate Student¹, Head of the Department², Post Graduate Student³, Post Graduate Student⁴
Department Of Prosthodontics, Nims Dental College and Hospital, Jaipur

Abstract

Cranioplasty is a reconstructive procedure performed to restore cranial defects caused by trauma, tumor resection, or decompressive surgery. This case report presents the rehabilitation of a cranial defect in a 32-year-old male patient using a custom-fabricated polymethyl methacrylate (PMMA) implant developed through conventional prosthodontic techniques. A precise impression was made, followed by wax pattern fabrication, flasking, and heat-cure PMMA processing. The implant was surgically placed with satisfactory esthetic and functional outcomes. This method provides a cost-effective alternative to digital workflows, particularly in resource-limited settings.

Keywords: Cranioplasty, PMMA, Cranial defect, Maxillofacial prosthesis, Conventional technique

Date of Submission: 18-04-2026

Date of Acceptance: 28-04-2026

I. Introduction

Cranioplasty is performed to repair cranial defects and restore both functional and esthetic integrity of the skull. These defects may arise due to trauma, tumor resection, or decompressive craniectomy. Reconstruction not only protects intracranial structures but also contributes to improved neurological function and psychological well-being of the patient^{1,2}.

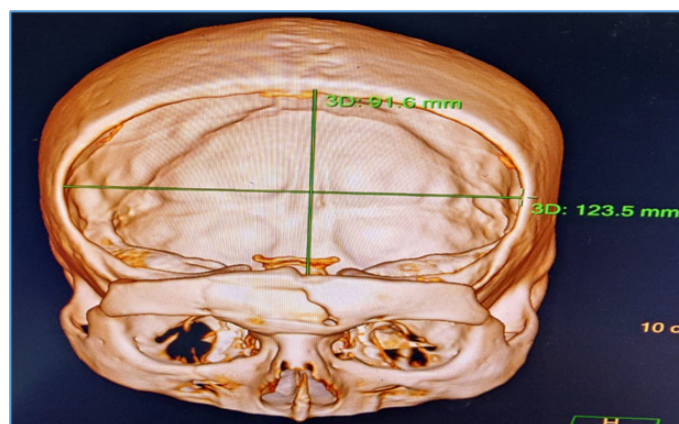
Various materials such as titanium, hydroxyapatite, and CAD/CAM fabricated patient-specific implants have been used for cranioplasty. However, polymethyl methacrylate (PMMA) remains widely used due to its affordability, ease of manipulation, and acceptable biocompatibility.^{3,4}

In recent years, CAD/CAM-based techniques have gained popularity due to their precision and customization. However, their high cost and limited accessibility restrict their widespread use in developing countries.^{7,12}

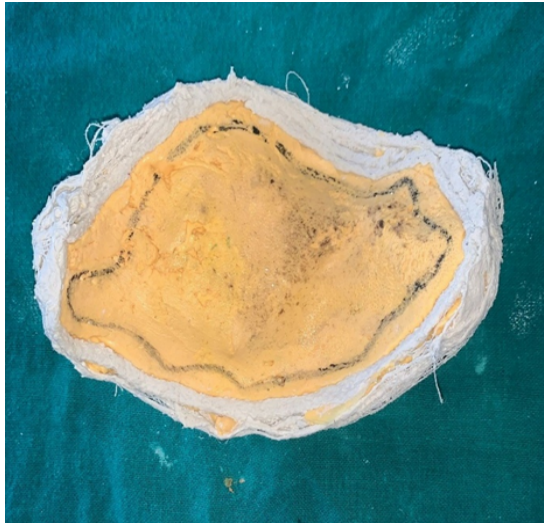
Therefore, conventional prosthodontic techniques continue to play a significant role in the fabrication of cranial prostheses.

II. Case Report


A 32-year-old male patient, reported with a cranial defect following trauma. The patient's chief complaint was esthetic deformity and lack of protection over the affected region. Radiographic evaluation using CBCT confirmed a well-defined cranial defect.



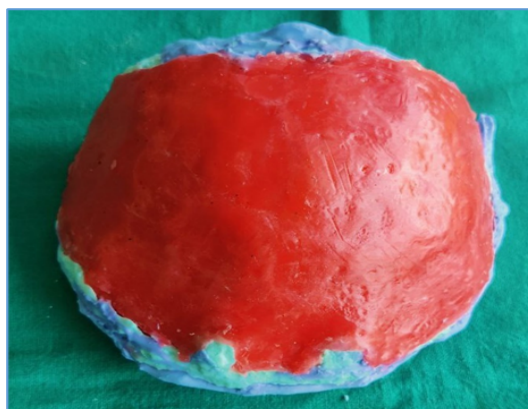
Procedure



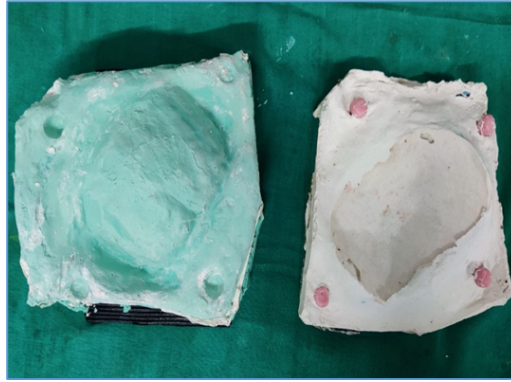
Impression Making: Accurate impression of the cranial defect was obtained.



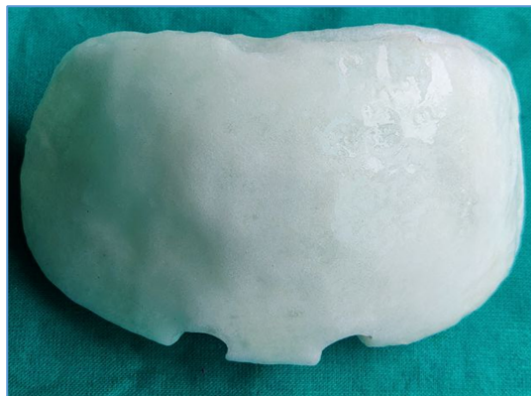Cast Preparation: A working cast was fabricated.



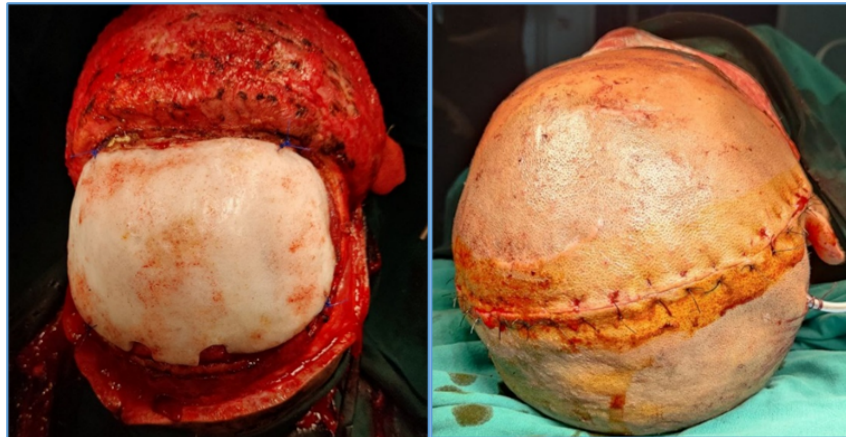
Wax Pattern: Anatomical contour restored using wax pattern.



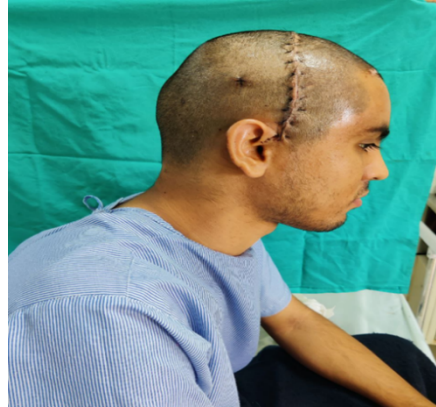Flasking & Processing: Heat-cure PMMA used to fabricate implant.



Finishing & Polishing: Smooth surface achieved to prevent irritation.



Surgical Placement: Implant placed and secured.



Follow-Up: Good healing observed at 5-day review.

III. Results

The fabricated PMMA implant demonstrated excellent adaptation and restoration of cranial contour. No post-operative complications such as infection, inflammation, or implant rejection were observed. The patient reported high satisfaction in terms of both esthetics and function.

IV. Discussion

Cranioplasty is a critical procedure aimed at restoring cranial integrity, improving neurological function, and enhancing esthetic outcomes. It also plays a significant role in protecting intracranial structures and improving cerebrospinal fluid dynamics. Various materials have been used for cranial reconstruction, including autogenous bone grafts, titanium meshes, hydroxyapatite, and alloplastic materials such as polymethyl methacrylate (PMMA).^{1,9}

PMMA remains one of the most widely used materials for cranioplasty due to its favorable properties, including ease of manipulation, cost-effectiveness, adequate strength, and acceptable biocompatibility.^{3,4} Studies have demonstrated that PMMA provides satisfactory long-term outcomes with minimal complications when proper aseptic techniques are followed.^{5,8}

Although CAD/CAM-based patient-specific implants offer superior precision and reduced operative time, their high cost and requirement of advanced infrastructure limit their use in developing regions.^{7,12} In contrast, conventional prosthodontic techniques, as used in the present case, provide a viable alternative with acceptable accuracy and clinical outcomes.

Biomechanical studies have shown that PMMA exhibits sufficient rigidity and resistance to deformation, making it suitable for cranial defect reconstruction.⁴ However, careful handling is required to avoid complications such as thermal injury during polymerization and infection.¹⁴

CBCT imaging played a crucial role in this case by enabling accurate assessment of defect size and morphology, thereby facilitating precise prosthesis fabrication and surgical planning. Similar findings have been reported in previous studies emphasizing the importance of advanced imaging in cranioplasty procedures.^{2,13}

The present case demonstrates that conventional PMMA cranioplasty can achieve satisfactory esthetic and functional results when meticulous clinical and laboratory procedures are followed. This approach is particularly beneficial in resource-limited settings where access to digital technologies is restricted.

V. Conclusion

Conventional PMMA cranioplasty is a reliable, economical, and effective method for cranial defect rehabilitation. It remains a valuable treatment option where advanced digital facilities are not available.

VI. References

1. Zanotti B, Zingaretti N, Verlicchi A, Robiony M, Alfieri A, Parodi PC. Cranioplasty: Review of materials. *J Craniofac Surg*. 2016;27(8):2061–2072.
2. Kumar AR, Bradley JP, Harshbarger R. Advances in cranioplasty: A review. *Neurosurg Focus*. 2004;16(3):E10.
3. Chiarini L, Figurelli S, Pollastri G, Torcia E, Ferrari F, Albanese M. Cranioplasty using acrylic material: A new technical procedure. *J Craniomaxillofac Surg*. 2004;32(1):5–9.
4. Gosain AK, Song L, Corrao MA, Pintar FA. Biomechanical evaluation of various cranioplasty materials. *Plast Reconstr Surg*. 2004;114(2):439–446.
5. Marchac D, Greensmith A. Long-term experience with methyl methacrylate cranioplasty in craniofacial surgery. *J Plast Reconstr Aesthet Surg*. 2008;61(7):744–752.
6. Moreira-Gonzalez A, Jackson IT, Miyawaki T, Barakat K, DiNick V. Clinical outcome in cranioplasty: Critical review in long-term follow-up. *J Craniofac Surg*. 2003;14(2):144–153.
7. Staffa G, Nataloni A, Compagnone C, Servadei F. Custom made cranioplasty prostheses in porous hydroxyapatite using 3D design techniques. *Surg Neurol*. 2007;68(5):441–446.
8. Rosenthal G, Ng I, Moscovici S, Lee KK, Lay T, Martin C, et al. Poly(methyl methacrylate) cranioplasty: Clinical experience and outcomes. *Acta Neurochir (Wien)*. 2014;156(4):693–702.
9. Aydin S, Kucukyuruk B, Abuzayed B, Aydin S, Sanus GZ. Cranioplasty: Review of materials and techniques. *J Neurosci Rural Pract*. 2011;2(2):162–167.
10. Thien A, King NKK, Ang BT, Wang E, Ng I. Comparison of polyetheretherketone and titanium cranioplasty after decompressive craniectomy. *World Neurosurg*. 2015;83(2):176–180.
11. Cabraja M, Klein M, Lehmann TN. Long-term results following titanium cranioplasty of large skull defects. *Neurosurg Focus*. 2009;26(6):E10.
12. Punchak M, Chung LK, Lagman C, Bui TT, Lazareff JA, Rezzadeh KS, et al. Outcomes following polyetheretherketone (PEEK) cranioplasty: Systematic review. *J Clin Neurosci*. 2017;41:30–35.
13. Grant GA, Jolley M, Ellenbogen RG, Roberts TS, Gruss JR, Loeser JD. New materials and techniques in cranioplasty. *Neurosurg Focus*. 2000;9(6):1–5.
14. Matsuno A, Tanaka H, Iwamuro H, Takanashi S, Miyawaki S, Nakashima M, et al. Analyses of the factors influencing bone graft infection after delayed cranioplasty. *Acta Neurochir*. 2006;148(5):535–540.