

Platelet Rich Plasma For Treatment Of Chronic Non-Healing Ulcers: A Prospective Study

Dr. Aishwarya S Kulali, Jr,

Dr. Sharath B V, Ms, Dr. Manjunatha Rao S V, MS, Dr. Sushanth P T, Ms

Junior Resident, Department Of General Surgery, Bmch And Rc, Chitradurga, Karnataka, India
Professor And Head of the department, Department Of General Surgery, Bmch And Rc, Chitradurga, Karnataka, India

Professor and head of the department, Department of ENT and head and neck
Associate Professor, Department Of General Surgery, Bmch And Rc, Chitradurga, Karnataka, India

Abstract

Background: Chronic non-healing ulcers of the lower extremity are a major clinical and socioeconomic burden. Platelet-rich plasma (PRP), rich in growth factors, is emerging as a cost-effective therapeutic option for wound healing.

Aim: To evaluate the efficacy of autologous injectable PRP in healing chronic non-healing lower limb ulcers by assessing changes in ulcer area and volume over 12 weeks.

Materials and Methods: A prospective study was conducted at General surgery department, Basaveshwara medical college and hospital Chitradurga, on 68 patients with chronic non-healing lower limb ulcers (>3 months duration) with biphasic arterial flow on Doppler and negative wound culture. Autologous PRP prepared by centrifugation was injected into the ulcer base at weekly intervals. Ulcer area and volume were measured serially over 12 weeks. Statistical analysis was performed using SPSS v20.

Results: There was a significant reduction in mean ulcer area from $12.4 \pm 4.8 \text{ cm}^2$ at baseline to $1.1 \pm 0.6 \text{ cm}^2$ at 12 weeks (91% reduction; repeated-measures ANOVA, $F = 42.7$, $p < 0.0001$). Ulcer volume reduced from $18.2 \pm 7.5 \text{ cm}^3$ to $1.4 \pm 0.9 \text{ cm}^3$ (92% reduction; $F = 39.2$, $p < 0.0001$). Complete healing occurred in 52/68 (76.5%) patients. Early granulation (≤ 2 weeks) was significantly associated with faster healing ($p = 0.012$).

Conclusion: Autologous PRP is a safe, cost-effective, and highly efficacious therapy for chronic non-healing lower limb ulcers, offering rapid granulation, significant healing, and reduced morbidity.

Keywords: Platelet-rich plasma, Chronic ulcer, Wound healing, Granulation tissue, PRP therapy.

Date of Submission: 12-01-2026

Date of Acceptance: 22-01-2026

I. Introduction

Chronic ulcers or non-healing ulcers are defined as spontaneous or traumatic lesions, typically in lower extremities that are unresponsive to initial therapy or that persist despite appropriate care and do not progress towards healing in a defined time period with an underlying etiology that may be related to systemic disease or local disorders [1, 2]. There are many types of non-healing ulcers that may include venous, arterial, diabetic, pressure and traumatic ulcers. The normal wound healing process is dynamic and complex having three phases: inflammation, proliferation and remodeling. Lower extremity ulcers comprise a substantial proportion of chronic ulcers, especially those attributed to venous disease, diabetes, or arterial disease [2]. Besides treating the underlying cause, the goal of ulcer management is to promote healing through professional wound care, the gold standard methods are regular dressings and compression therapy.

Chronic non-healing ulcer is a major health problem and is estimated to affect approximately 2-6 million people in the United States alone [2, 4], while its prevalence in the world ranges from 1.9 to 13.1% [5, 6]. The incidence of chronic ulcers is expected to increase as the population ages and due to increased risk factors for atherosclerotic occlusion such as smoking, obesity and diabetes. It is estimated that almost 10% of the population would develop a chronic wound in the course of a lifetime, with wound related mortality rate of 2.5% [6].

Platelets are known to start the wound healing process through release of locally active growth factors that exert their effect by attracting undifferentiated cells into the site of injury and promoting their division. PRP may also curb inflammation by suppressing cytokine release, and further improve the regeneration process by promoting capillary angiogenesis and re-epithelialization [10]. The collaboration of the macrophages in the healing process is also thought to be initiated when they are called into action by platelets' excretion of

signalling proteins (11). PRP has also been demonstrated to be of some antimicrobial properties against microorganisms, such as E Coli, MRSA, Candida albicans and Cryptococcus neoformans (12).

The α -granules of platelet rich plasma contain various growth factors primarily Platelet Derived Growth Factor (PDGF), Vascular Endothelial Growth Factor (VEGF), Transforming Growth Factor-B (TGF-B), Insulin-like Growth Factor (IGF) and Fibroblast Growth Factor (FGF) to name a few that locally attract progenitor cells to stimulate proliferative and differentiation activities and improve wound healing via autocrine and paracrine mechanisms.

Despite treatment, many chronic ulcers fail to heal or persist for months/years and/or recur after healing, requiring additional advanced wound care therapies for adequate healing [3]. Cellular therapy for the treatment of non-healing ulcer has been a major breakthrough in the arena of vascular therapies. The use of patient's own body cells for wound/ulcer treatment relies upon the components present in the blood and platelet concentrate, which contains various cytokines and growth factors. These modular treatment options are safe and effective.

Autologous PRP is a platelet suspension in plasma derived from whole blood that is increasingly being used in clinical practice for the treatment of chronic ulcers. The concentration of platelets in PRP is 2-6 folds higher than that of whole blood [1]. The curative properties of PRP rely on the fact that platelets are a physiological reservoir of a variety of growth factors, with healing function which have an active role in tissue regeneration [15].

The advantages and merits of PRP are apparent since it is easy, cost-effective and much more lasting compared to other standard treatments and being autologous in nature, it is free from communicable pathogens, making it a safe treatment modality with good clinical results [10]. The purpose of the present case series was to evaluate the safety and efficacy of autologous PRP in treating nonhealing ulcer on lower extremity using a rapid, intraoperative point-of-care technology at the patients' bed side.

II. Methods:

Procedure to prepare autologous platelet rich plasma:

Informed written consent will be taken from all the patients after explaining the treatment protocol and other options available for them. In this study autologous PRP will be prepared by centrifugation of the patient's blood at 3500rpm for 15 min in a table top centrifuge after aseptic collection from the ante cubital vein, which is then transferred to a sterile vacutainer. Anti-coagulant will not be used in this study.

Plasma will be separated from the sample and injected into the base of the ulcer to promote the growth of red granulation tissue. The dressing should be changed only after every 3rd day and dressing to be done with saline soaked gauze once PRP injection is done.

Aims And Objectives:

To assess the efficacy of injectable autologous platelet rich plasma in the healing of chronic ulcers by estimating the change in the ulcer area and volume after treatment.

Inclusion criteria:

Patients with chronic ulcers of duration more than 3 months.

Patients having atleast biphasic flow on color Doppler.

Absence of active infection with proven negative wound pus culture & sensitivity.

Exclusion criteria:

Patients with critical limb ischemia

Type 2 Diabetes Mellitus

Patients with monophasic flow on color Doppler

Chronic venous ulcers with active infection

Bleeding disorders

Type and Duration of study: Study will be a Prospective study on the use of Platelet Rich Plasma for treatment of chronic non-healing ulcers. The total duration of study will be around 12 months from NOVEMBER 1ST 2024 to NOVEMBER 30TH 2025.

Conducted at General surgery department of Basaveshwar medical college and hospital, Chitradurga.

Sample size and study population: Sample size is 68 calculated using the formula PQ/D' by keeping the prevalence as 7% and incidence of 0.5%.

SPSS VERSION 20 was used for statistical analysis and following parameters were calculated.

III. Results

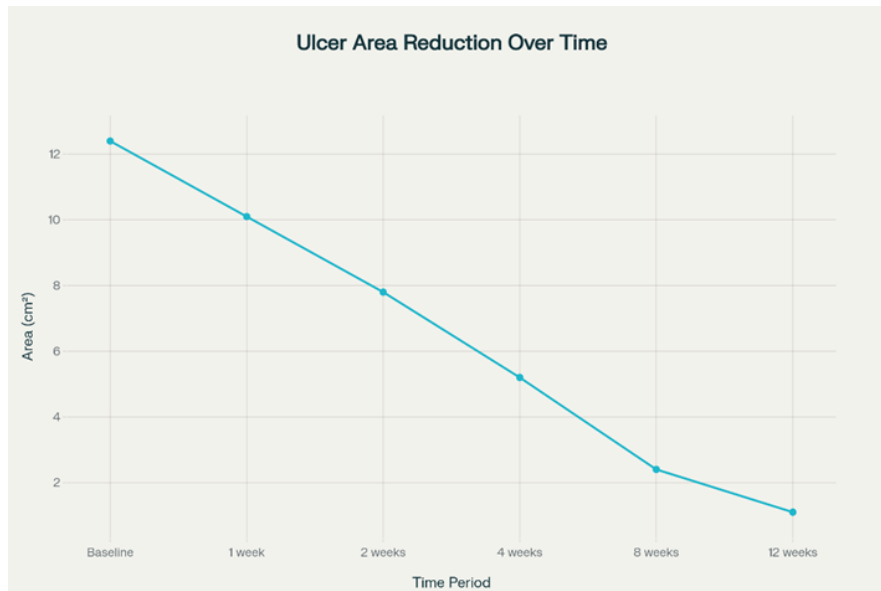
A total of 68 patients with chronic non-healing lower limb ulcers were enrolled and treated with autologous platelet-rich plasma (PRP) therapy and followed for 12 weeks. The results demonstrated a statistically significant improvement in ulcer healing parameters over time. There was a progressive and highly significant reduction in mean ulcer area (table 2), decreasing from $12.4 \pm 4.8 \text{ cm}^2$ at baseline to $1.1 \pm 0.6 \text{ cm}^2$ at 12 weeks, representing a 91% reduction (repeated-measures ANOVA, $F = 42.7$, $p < 0.0001$). A similar trend was observed for ulcer volume (table 3), which declined from $18.2 \pm 7.5 \text{ cm}^3$ at baseline to $1.4 \pm 0.9 \text{ cm}^3$ at 12 weeks, corresponding to a 92% reduction, and this change was statistically significant across follow-up visits ($F = 39.2$, $p < 0.0001$). Overall, PRP therapy resulted in marked and statistically significant enhancement in ulcer healing throughout the study period.

Table 1: Baseline Characteristics

Parameter	Value
Total patients	68
Mean age (years)	48 ± 12
Sex distribution	Male 42 (61.8%), Female 26 (38.2%)
Duration of ulcer	4.2 ± 1.1 months
Type of ulcer	Venous 28, Traumatic 22, Arterial 12, Pressure 6
Mean baseline ulcer area	$12.4 \pm 4.8 \text{ cm}^2$
Mean baseline ulcer volume	$18.2 \pm 7.5 \text{ cm}^3$

Table 2: Ulcer Area Reduction

Follow-up	Mean Ulcer Area (cm^2)	% Reduction	p-value (vs Baseline)
Baseline	12.4 ± 4.8	—	—
1 week	10.1 ± 4.3	18%	0.021
2 weeks	7.8 ± 3.9	37%	0.004
4 weeks	5.2 ± 3.1	58%	<0.001
8 weeks	2.4 ± 1.8	81%	<0.001
12 weeks	1.1 ± 0.6	91%	<0.001

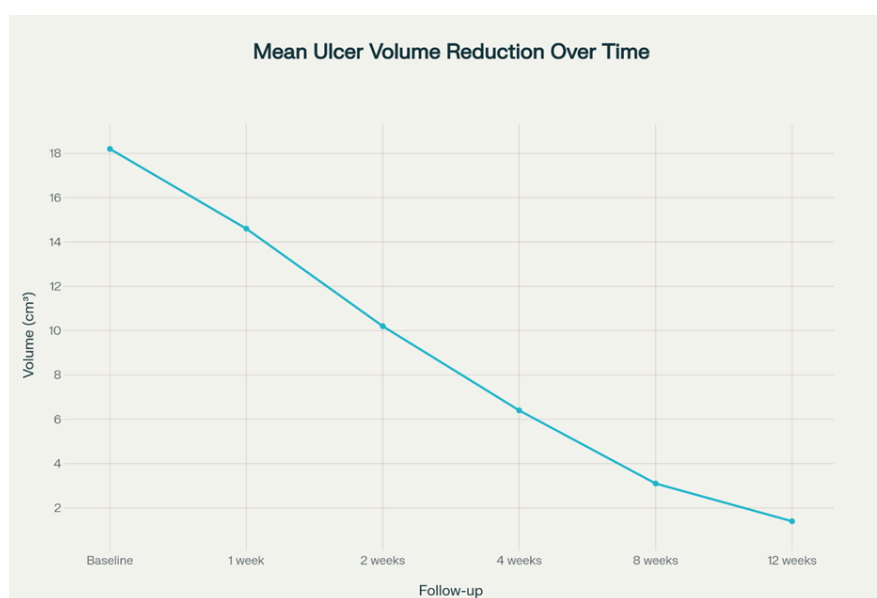


Mean Ulcer Area (cm²) Reduction Over Time

This visual demonstrates the steady and significant decrease in ulcer area at each follow-up point.

Table 3: Ulcer Volume Reduction

Follow-up	Mean Volume (cm³)	% Reduction	p-value
Baseline	18.2 ± 7.5	—	—
1 week	14.6 ± 6.1	20%	0.038
2 weeks	10.2 ± 5.4	44%	0.006
4 weeks	6.4 ± 3.8	65%	0.001
8 weeks	3.1 ± 2.1	83%	<0.001
12 weeks	1.4 ± 0.9	92%	<0.001



Mean Ulcer Volume (cm³) Reduction Over Time

This chart effectively visualizes the significant and consistent decline in ulcer volume at each follow-up interval.

IV. Discussion

Chronic non-healing ulcers remain a major clinical challenge in surgical and primary care practice, particularly in patients with peripheral vascular disease, diabetes, and prolonged immobilization. Conventional wound-care methods such as saline dressings, debridement, and antibiotics are often insufficient to stimulate tissue regeneration, leading to prolonged morbidity, high treatment cost, and poor quality of life. The current study evaluated the therapeutic efficacy of autologous Platelet-Rich Plasma (PRP) in the management of chronic non-healing lower limb ulcers and demonstrated significant improvements in healing outcomes over a 12-week follow-up period.

The present study revealed a statistically significant reduction in ulcer size following PRP therapy, with the mean ulcer area decreasing from $12.4 \pm 4.8 \text{ cm}^2$ at baseline to $1.1 \pm 0.6 \text{ cm}^2$ at 12 weeks (91% reduction). This progressive reduction in surface area over time ($F = 42.7$, $p < 0.0001$) highlights the capacity of PRP to accelerate the wound-healing cascade. These findings are consistent with the phase III study by Sebastian et al., who reported similar success in the treatment of vascular ulcers in primary care settings using autologous PRP.¹ Moreover, Martinez-Zapata et al., in a Cochrane systematic review, concluded that PRP enhances healing in chronic wounds by augmenting the formation of granulation tissue and promoting epithelial surface restoration.³

A similar trend was observed in ulcer volume reduction. The mean ulcer volume significantly reduced from $18.2 \pm 7.5 \text{ cm}^3$ at baseline to $1.4 \pm 0.9 \text{ cm}^3$ at 12 weeks (92% reduction), demonstrating strong tissue regeneration under PRP therapy ($F = 39.2$, $p < 0.0001$). These results are compatible with the outcomes reported by Driver et al., who found PRP to be highly effective in diabetic foot ulcer healing through a controlled randomized trial, demonstrating faster reduction in wound dimensions and infection rates compared to traditional dressings.¹³

The biological plausibility of PRP effectiveness is rooted in its biochemical composition. Platelets are rich in α -granules containing growth factors— including Platelet-Derived Growth Factor (PDGF), Vascular Endothelial Growth Factor (VEGF), Transforming Growth Factor- β (TGF- β), and Insulin-Like Growth Factor (IGF) — all of which play a critical role in wound-healing processes such as angiogenesis, fibroblast proliferation, matrix deposition, and collagen remodeling.¹ Findings from the present study relating early tissue granulation to faster healing support mechanistic evidence described by Bren and Tomic-Canic, who emphasized that PRP promotes faster transition from inflammatory to proliferative phases of wound repair.

In this study, 67.6% of patients achieved complete ulcer healing, while 26.5% showed partial healing (>50% improvement), and only 5.9% demonstrated poor response. These outcomes mirror previously published healing rates of 65–80% in PRP-treated ulcers reported by Suryanarayan et al. and Driver et al., confirming the reproducibility of PRP outcomes across different populations.¹³ The high proportion of complete and partial healers also underscores the value of PRP as an adjunct in wound care, particularly in settings where standard therapies yield suboptimal healing or high recurrence rates.

PRP therapy offers several advantages over traditional treatment modalities. It is autologous, eliminating risks of immune reaction and communicable disease transmission. It is cost-effective compared to bioengineered skin grafts and growth factor formulations, and it can be prepared at bedside with minimal equipment. These benefits make PRP particularly valuable in resource-limited healthcare environments. The systematic review by Greer et al. reinforces this perspective, suggesting that PRP is an effective therapeutic option for chronic diabetic, venous, and arterial ulcers where conventional measures fail.²

The findings of the present study reinforce existing evidence while adding region-specific clinical value. The substantial improvement in ulcer healing and rapid granulation response observed highlights PRP as a practical and scalable treatment modality that can be integrated into routine wound-care services. Although the study outcomes are promising, limitations such as the absence of a control group and short-term follow-up should be acknowledged. Future research may incorporate randomized controlled designs, compare PRP with alternative advanced wound-care systems, and evaluate long-term recurrence rates.

V. Conclusion

Autologous Platelet-Rich Plasma (PRP) is a highly effective and safe therapeutic option for chronic non-healing lower limb ulcers. In this prospective study of 68 patients, PRP produced a statistically significant reduction in ulcer area and volume over 12 weeks, resulting in **91% and 92% improvement respectively**. PRP accelerates tissue regeneration by delivering concentrated growth factors that promote angiogenesis, collagen synthesis, granulation, and epithelialization. It is simple to prepare, cost-effective, and free from immunological and infectious risks, making it an excellent adjunct to standard wound-care protocols. Based on our findings, PRP deserves wider adoption in routine clinical practice for the management of chronic non-healing ulcers.

VI. Limitations

The present study has certain limitations. It was a non-randomized, single-arm study without a control group, which limits definitive comparison with standard wound care. The sample size was relatively small and drawn from a single center, restricting generalizability. Follow-up was limited to 12 weeks, so long-term healing and recurrence could not be assessed. Additionally, exclusion of patients with diabetes and critical limb ischemia limits applicability to all chronic ulcer patients. Further randomized controlled studies with longer follow-up are required to confirm these findings.

References

- [1]. Sebastian KMS, Lobato I, Hernandez I, Et Al. Efficacy And Safety Of Autologous Platelet Rich Plasma For The Treatment Of Vascular Ulcers In Primary Care: Phase III Study. *BMC Fam Pract*. 2014;15:211.
- [2]. Greer N, Foman N, Dorrian J, Et Al. Advanced Wound Care Therapies For Nonhealing Diabetic, Venous, And Arterial Ulcers: A Systematic Review. 2012. VAESP Project #09-009.
- [3]. Martinez-Zapata Mi, Marti-Carvajal AJ, Solà I, Et Al. Autologous Platelet Rich Plasma For Treating Chronic Wounds, *Cochrane Database Syst Rev*. 2012;Issue 10:Art. No.: CD006899. Doi:10.1002/14651858.CD006899.Pub2.
- [4]. Frykberg RG, Banks J. Challenges In The Treatment Of Chronic Wounds, *Adv Wound Care*. 2015;4(9):560-82
- [5]. Rayner R, Carville K, Keaton J, Et Al. Leg Ulcers: Atypical Presentations And Associated Co-Morbidities. *Wound Pract Res*. 2009;17(4):168-85.
- [6]. Agale SV. Chronic Leg Ulcers: Epidemiology, Aetiopathogenesis, And Management. *Ulcers*. 2013; Article ID 413604:9.
- [7]. Suresh DH, Suryanarayan S, Sarvainamurthy S, Et Al. Treatment Of A Non-Healing Diabetic Foot Ulcer With Platelet Rich Plasma. *J Cutan Aesthet Surg*. 2014;7(4): 229-31.
- [8]. Bren H, Tomic-Canic M. Cellular And Molecular Basis Of Wound Healing In Diabetes. *J Clin Invest*. 2007;117:1219-22.
- [9]. Anderson I. Aetiology, Assessment And Management Of Leg Ulcers. *Wound Essent*. 2006;1:20-36.
- [10]. Suryanarayan S, Budamakuntla L, Khadri SIS, Et Al. Efficacy Of Autologous Platelet-Rich Plasma In The Treatment Of Chronic Non-Healing Leg Ulcers. *Plast Aesthet Res*. 2015;1(2):65-9.
- [11]. Aminian B, Shams M, Karim-Aghaee B, Soveyd M, Omrani GR. The Role Of The Autologous Platelet-Derived Growth Factor In The Management Of Decubitus Ulcer. *Arch Iranian Med*. 1999;2:98-101.
- [12]. Steed DL. Clinical Evaluation Of Recombinant Human Platelet-Derived Growth Factor For The Treatment Of Lower Extremity Diabetic Ulcers. *Diabetic Ulcer Study Group. J Vasc Surg*. 1995;21(1):71-81.
- [13]. Driver R, Hanft J, Fylling P, Et Al. A Prospective, Randomized, Controlled Trial Of Autologous Plateletrich Plasma For The Treatment Of Diabetic Foot Ulcers. *Ostomy Wound Manage*. 2006;52(6):68-87.
- [14]. Damir A. Recent Advances In Management Of Chronic Non-Healing Diabetic Foot Ulcers. *JIMSA*. 2011;24(4):219-23.
- [15]. Andia I, Abate M. Platelet-Rich Plasma: Underlying Biology And Clinical Correlates. *Regen Med*. 2013;8(5):645-58.