

## A Comprehensive review of Occlusion in Fixed Partial Denture

Balamanikandan S<sup>1</sup>, Onesiphour S<sup>2</sup>, Dr. Ahnaf Abdulla P<sup>3</sup>, Dr. Abhinav Mohan<sup>4</sup>,  
Dr. Dipin PP<sup>5</sup>, Dr. Cimmy Augustine<sup>6</sup>

<sup>(1,2)</sup>Final year BDS, Mahe Institute of Dental sciences & Hospital.

<sup>(3,5,6)</sup>Senior lecturer, Dept. of Prosthodontics and Crown & Bridge, Mahe Institute of Dental Sciences & Hospital.

<sup>(4)</sup>Reader, Dept. of Prosthodontics and Crown & Bridge, Mahe Institute of Dental Sciences & Hospital.

---

### Abstract:

*The long-term success of a fixed partial denture depends on its occlusion. Dental occlusion is the culmination of several components, which include the teeth, the periodontium, the tongue and the supporting oral tissues. The main question that arises is whether the patient's oral condition or state is good enough to receive a fixed partial denture. In this article, we are going to discuss occlusion in fixed partial dentures, their evolution, concepts, occlusal interferences and treatment.*

**Key Words:** Occlusion, FPD, Determinants, Concepts, Interferences, Implant supported prosthesis.

---

Date of Submission: 28-06-2025

Date of Acceptance: 06-07-2025

---

### I. INTRODUCTION:

Occlusion is defined as the act or process of closure or of being closed or shut off, or the static relationship between the incising or masticating surfaces of the maxillary or mandibular teeth or tooth analogues(1). The ideal condylar position, or centric relation, is an anteriorly, superiorly braced position along the articular eminence of the glenoid fossa, with the articular disc positioned between the condyle and eminence. During restorative treatment, the occlusion should be in harmony with this position. This is the most musculoskeletally stable position and the most orthopedically stable position due to the activation of the elevator muscles(2).

### TERMINOLOGIES:

**Centric relation:** It is a maxillomandibular relationship, independent of tooth contact, in which the condyles articulate in the anterior-superior position against the posterior slopes of the articular eminences; in this position, the mandible is restricted to a purely rotary movement; from this unstrained, physiologic, maxillomandibular relationship, the patient can make vertical, lateral or protrusive movements; it is a clinically useful, repeatable reference position(1).

**Centric occlusion:** It is the occlusion of opposing teeth when the mandible is in centric relation; this may or may not coincide with the maximal intercuspal position(1).

### IDEAL OCCLUSION:

It is defined as an occlusion which is compatible with stomatognathic system providing efficient mastication and good esthetics, without creating physiological abnormalities.

## **EVOLUTION OF OCCLUSION:**

In dentistry, occlusion has always been a mysterious subject that leaves most of us baffled when faced with a complex case, particularly when full mouth rehabilitation involves vertical dimension loss. Let's take a quick look at the evolution of occlusion and the various contributions made by distinguished researchers. It all began in the 1950s with the idea of balanced occlusion and then gradually evolved to the current mutually protected occlusion(4).

- In 1890, von Spee wrote about the cuspids' "overbite," or vertical overlap.
- Gysi explained the canine-protected occlusion plan and the teeth's masticatory activities in 1915.
- McCollum established a Gnathologic society in 1926. In 1955, McCollum and Stuart presented the Gnathological Concept in their seminal Research Report. This idea shows how the maxillomandibular relationships, transverse hinge axis, mandibular movements, and an Arcon fully adjustable articulator develop. Because of this, natural dentition was also using balanced occlusion(4).
- However, the percentage of clinical failures eventually led Stuart to observe that patients were biting their tongues and cheeks due to deflective occlusal contacts caused by unequal wear of the buccal and lingual cusps, which resulted in a loss of centric-related closure(4).
- Similar to D'Amico's observation, Stuart and Stallard later noted that canines excluded all other teeth in laterotrusive (working) excursion. This observation gave rise to the idea of mutually protected occlusion(4).
- In 1958, D'Amico conducted research on the importance of cuspid teeth and introduced the concept of canine guidance, also known as canine disclusion, which states that the maxillary canine teeth guide the mandible during eccentric movements and determine both lateral and protrusive movements of the mandible when in functional contact with the lower canines and first premolars. The balanced occlusion is therefore only appropriate for fully edentulous arches and is not only inappropriate but detrimental when used on natural dentition and fixed prosthodontic rehabilitation procedures(4).
- The Point Centric concept was proposed, according to which the condyles should be positioned in the mandibular fossae at the exact moment when the teeth's maximal intercuspation takes place in the retruded contact position(4).

## **CHARACTERISTICS OF IDEAL OCCLUSION:**

Beyron has described a few key aspects of occlusion as follows:

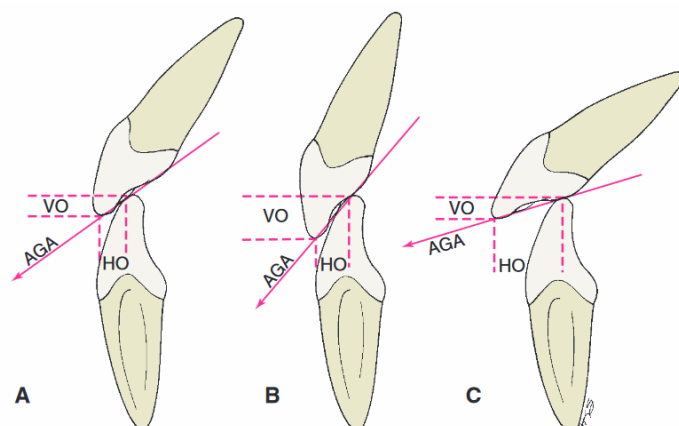
- Regardless of any particular relationship, the maximum number of bilateral centric stops during closing in maximum intercuspation.
- For the best force distribution within the alveolus, posterior teeth should be axially loaded as much as feasible.
- The ability to move freely within the retrusive range of occlusal contact guarantees that the mandible won't be forced into a border position when the teeth meet in centric occlusion.
- The ability to move the occlusal contact in multiple dimensions, with group function during anterior tooth protrusion and laterotrusion, offers the best force distribution for any kind of functional activity.
- Sufficient vertical occlusal dimension(3).

Dawson (1974) also proposed his methods for determining ideal occlusion:

- When the condyles are in their most superior posterior position, all teeth have stable stops.
- An anterior guidance that blends with the boundary movements of the function envelop.
- All posterior teeth are dislocated in protrusive motions.
- Every posterior tooth on the balanced side is dislocated.
- All posterior teeth on the working side do not obstruct the lateral anterior guidance or the condylar border movements(3).

## **DETERMINANTS OF OCCLUSION:**

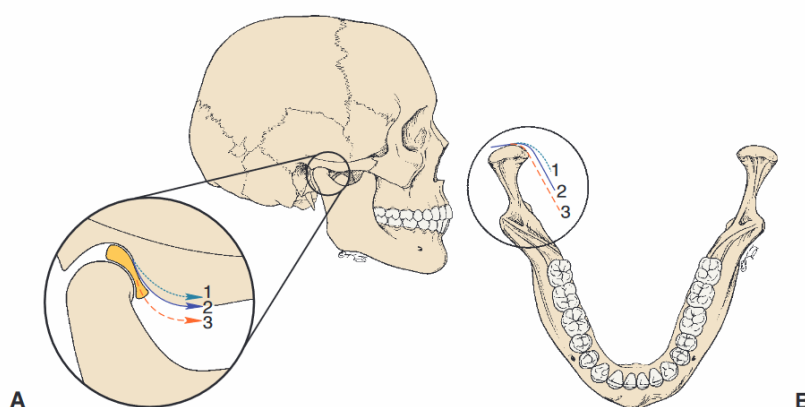
**Anterior determinants:** The mandible is guided by the anterior teeth in several ways. During protrusive and lateral excursions, the mandible is guided by the anterior teeth. Since canines have the strongest and longest roots, they are particularly well-suited for this. Canines being located away from the fulcrum coupled with proprioceptive thresholds and accompanying responses lessen the load acting on them(5).



The anterior guidance between the maxillary and mandibular anterior teeth has a direct influence on the direction of mandibular movement.

**FIGURE 4-15** ■ Anterior determinants of occlusion. Different incisor relationships with differing horizontal overlap (HO) and vertical overlap (VO) produce different anterior guidance angles (AGA). **A**, Angle class I. **B**, Angle class II, division 2 (increased VO; steep AGA). **C**, Angle class II, division 1 (increased HO; flat AGA).

**Posterior determinants:** The two TMJs are posterior determinants, and the dentist has no control over them. They affect how the mandible moves, which in turn affects how the teeth move. The foundation for the use of articulators is the recording and replication of these movements. Vertical stoppers for mandibular closure are provided by posterior teeth, which direct the mandible into the most intercuspal position possible(5).



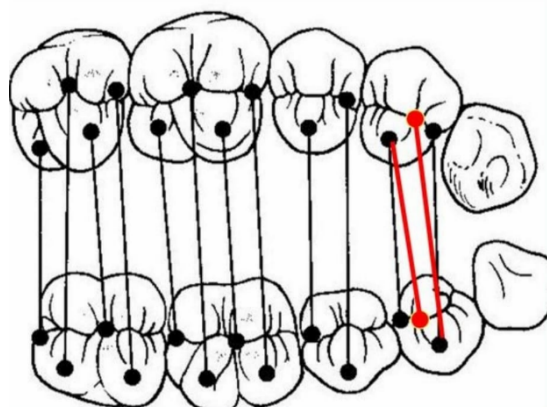
**FIGURE 4-14** ■ Posterior determinants of occlusion. **A**, Angle of the articular eminence (condylar guidance angle). 1, Flat; 2, average; 3, steep. **B**, Anatomy of the medial walls of the mandibular fossae. 1, Greater than average; 2, average; 3, minimal side shift.

## STATIC OCCLUSION:

Types of Occlusion Relationship:

### 1.Cusp-Ridge Pattern of Occlusion:

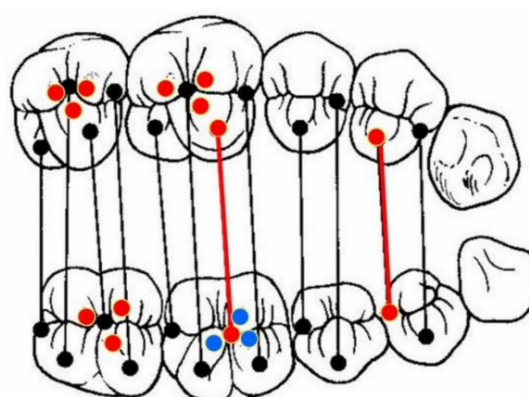
- One stamp cusp fits into a fossa, while another stamp cusp of the same tooth fits into the embrasure area of two opposing teeth because of the relationship between the upper and lower teeth.
- This cusp-ridge configuration is referred to as a "cusp embrasure" occlusal pattern or a "tooth-to-two teeth" occlusion.



*Cusp tips to marginal ridges and Cusp tips to fossa*

## **2.Cusp-Fossa Pattern of Occlusion:**

The majority of the stamp cusps in this pattern fit into fossae. An interdigitative link between the cusps and fossae of one tooth and the cusps and fossae of only one opposing tooth is typically produced via the "cusp-fossa" relationship. Another name for this pattern is "tooth-to-one-tooth" occlusion.



*Cusp-fossa*

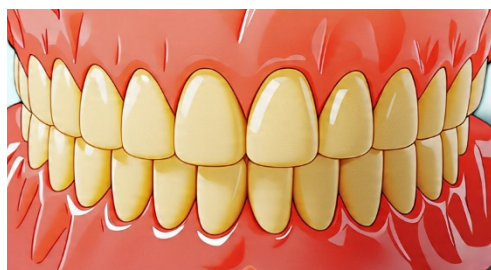## **Advantages of Cusp-Fossa over Cusp-Marginal Ridge Pattern of Occlusion:**

- The upper and lower teeth interlock due to a cusp-fossa relationship, providing the most support possible in centric occlusion.
- A more effective chewing mechanism results from the forces being closer to each tooth's long axis.
- There is less tipping because the occlusal stresses travel along the teeth's long axes. Food impaction between marginal ridges has been eliminated. The occlusion and the teeth are more stable. There is less wear on the cusp tips because the cusps make contact with their ridges rather than their points.

## **DYNAMIC OCCLUSION:**

### **1.BILATERALLY BALANCED OCCLUSION:**

By Monson and von Spee. It requires that a maximal number of teeth make contact in all of the mandible's excursive positions. In complete denture fabrication, when contact on the nonworking side is crucial to preventing denture tipping, this is very helpful. It is not recommended to use this in natural dentition because it results in several facets being worn out from extreme friction(4).



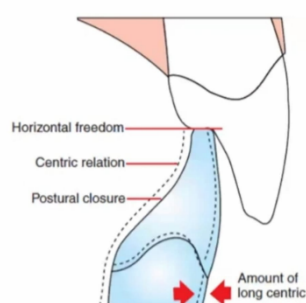
***Bilaterally balanced occlusion***

## **2.UNILATERALLY BALANCED OCCLUSION/GROUP FUNCTION:**

By Schuyler. In this case, a lateral excursion should bring all of the functioning side teeth into contact. Conversely, the nonworking side's teeth are shaped to avoid contact altogether. The occlusal load is distributed via the working side teeth's group function. The absence of contact on the nonworking side prevents those teeth from being subjected to the damaging, obliquely directed forces inherent in nonworking interferences. Additionally, it prevents excessive wear on the centric holding cusps, which include the maxillary palatal cusps and the mandibular facial cusps(4).

## **3.LONG CENTRIC:**

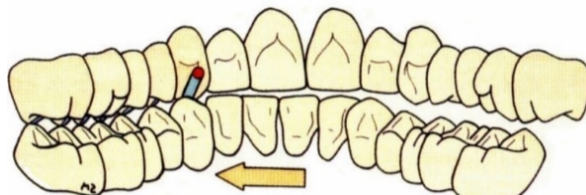
As the idea of unilateral balance developed, it was proposed that it is beneficial to allow some degree of anteroposterior mobility. This concept is referred to as long centric(4).



***Long centric***

## **4.MUTUALLY PROTECTED OCCLUSION :**

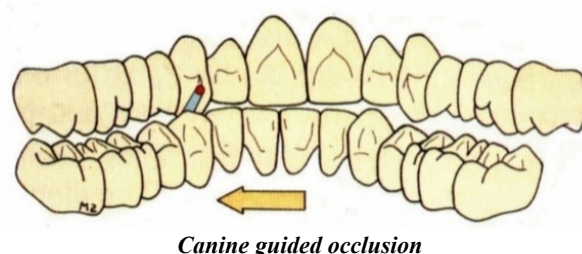
The idea was derived from the work of D'Amico, Stuart, Stallard, and Lucia as well as the members of the Gnathological Society, which McCollum founded in the middle of the 1920s. Mutually protected occlusion was renamed ORGANIC OCCLUSION by Stallard and Stuart (1961), in which MIP and a centric relation coexisted. Only opposing canines should make contact during lateral excursions, and only the anterior teeth should make contact during protrusion. In a centric occlusion, the cusps of the posterior teeth should make contact. A cusp-to-fossa relationship exists between the posterior teeth. The anterior teeth disocclude by 25 microns(7)



***Mutually protected occlusion***

### 5. CANINE GUIDED OCCLUSION:

Gysi introduced the canine protected occlusion scheme in 1915. In 1958, D'Amico conducted research on the importance of cuspid teeth and proposed the concept of canine guidance, also known as canine disclusion, which states that the mandible is guided during eccentric movements by the maxillary canine teeth. When in functional contact with the lower teeth, they guide both lateral and protrusive movements of the mandible. Thus preventing any force other than axial loading(7).



#### **Why canine is a preferred tooth:**

- Anatomically: long roots or sufficient root length
- A good crown-to-root ratio that can withstand high pressures
- Distance from TMJ: reduces the likelihood of TMJ dysfunction by providing better leverage to counterbalance loads.
- The palatal surface is sufficiently concave to facilitate lateral movement.

It possesses numerous receptors in the PDL, which allow it to regulate lateral pressure by guiding vertical masticatory movements. It is surrounded by dense, compact bone, which can withstand stress better.

#### **Similarities and differences between group function and canine-protected occlusion:**

McAdam summarized some similarities and differences between canine-protected occlusion and group function. Similarities:

Both must have several posterior contacts with intercusp location (centric occlusion) that are either within 1 mm of protrusion in a straight sagittal direction or coincident with the centric relation. During mediotrusion, posterior contacts must be absent. Whenever possible, anatomical arrangements should prevent posterior contact during anterior incision. When the anatomical arrangement allows, there should be posterior disclusion during the protrusive movement together with anterior group functional guidance. When the anatomical arrangement allows, there should be posterior disclusion during the protrusive movement together with anterior group functional guidance(8).

Differences:

In canine guidance, the horizontal forces are minimized by limiting the supporting cusps contact to their opposing fossae at or near their intercusp position; steeper canine inclines prevent all other lateral contacts, making the chewing stroke more sagittal in frontal view. In group function, the first contact occurs at a lateral location rather than between the supporting cusp and opposing fossa, followed by a slide to centric occlusion. This will result in some horizontal forces, but these can be reduced by:

- Striking as many working contacts as possible at the same time;
- Reducing the angle of incline;
- Reducing the friction by removing irregularities and roughness;
- Slightly rounding off the facio-occlusal line angle(8).

#### **Developing an acceptable lateral and protrusive guidance:**

Establishing a healthy and useful complement of tooth contacts that will help the mandible navigate the different eccentric movements is the aim of this selective grinding step. The forces of eccentric mandibular movement are typically not well accepted by posterior teeth. Under ideal circumstances, the canines should make contact during laterotrusive motions and disocclude all of the posterior teeth (bilaterally) because the anterior teeth, and particularly the canines, are far superior(10).

This objective is accomplished when the canines are properly aligned. However, during a laterotrusive movement, they are frequently not in the right position to make contact right away. This loss of contact cannot be fixed since selective grinding just removes tooth structure. When it happens, the mandible should be guided and contacted by the teeth that can withstand the lateral stresses the best until the canines can make contact and help with the movement(10).

Laterotrusive contacts are most readily accepted by a few posterior teeth that are closest to the anterior part of the mouth, such as the premolars. To put it another way, group function guidance is established when the canines are not positioned to quickly give laterotrusive instruction. In this case, the mandible is guided laterally by the premolars and even the mesiobuccal cusps of the first molars. The canines are employed to aid in the movement as soon as sufficient movement brings them into contact(10).

It is crucial to keep in mind that this laterotrusive movement is dynamic rather than static. Throughout the entire movement, tooth contacts must be carefully managed until the canines cross over one another and the anterior incisors make contact (referred to as the crossover position). All of the teeth guiding the group function should make smooth, even contact throughout this dynamic movement. The first premolar may undergo traumatic stresses, which typically lead to mobility, if it is observed that it is in charge of all guidance during a specific segment of the movement. Through selective grinding, this tooth is adjusted such that, during the laterotrusive movement, it makes equal contact with the other teeth(10).

## **OCCLUSAL SCHEMES:**

### ➤ **Basic principles:**

Regardless of the type or the number of restorations, the occlusal scheme to be adopted must be decided before restoration. The following are the shared goals of the various schemes:

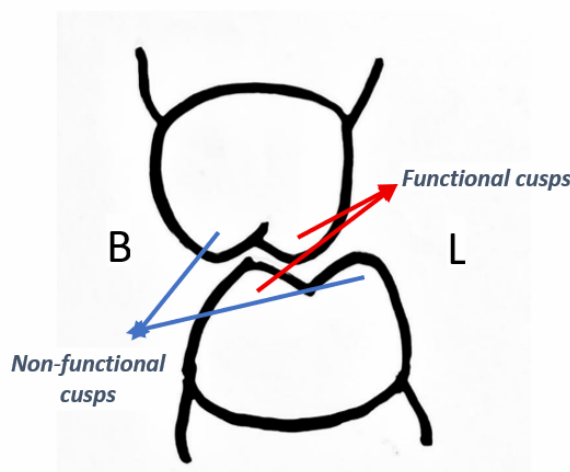
- After restoration, the position of the teeth should remain stable. New deflective contacts cannot be added by the restoration.
- It should be highlighted that minor high spots may go unnoticed by the physician because the tooth is intruded after initial contact. The restoration and other teeth in the IP should make synchronous contact without high spots or absence of occlusion.
- The restoration should not have any non-functioning side contacts since these create rotational forces on the tooth and restoration, and eliminating them requires working side contacts to "pick up" the guidance.
- Working side interference, which frequently appears on lingual cusps and is challenging to identify, shouldn't be present on the restoration.
- The anterior guidance shouldn't cause occlusal hindrance and should work in harmony with the temporomandibular joints and muscles.
- The strongest regions of the tooth and restorative material should receive the majority of occlusal forces.
- The long axis of teeth should be the direction of occlusal forces(10).

## **FUNCTIONAL CUSP:**

- Cusps that form a centric occlusion with the opposing teeth. The buccal cusps of the lower posterior teeth and the lingual cusps of the upper posterior teeth are in a normal occlusion.

## **NON-FUNCTIONAL CUSP:**

- Cusps in a centric occlusion that do not occlude with the opposing teeth. The lingual cusps of the lower posterior teeth and the buccal cusps of the upper posterior teeth are in a normal occlusion.



## **Cusp angle**



Cusp angle is the inclination of the cusp slope from the cusp tip to the marginal ridge. It is defined as "the angle made by the average slope of a cusp with the cusp plane measured mesiodistally or buccolingually" (GPT-6 1994). The cusp plane means the plane determined by the two buccal cusp tips and the highest lingual cusp of a molar" (GPT-6 1994), anatomically means a plane comprised of three cusp tips. The effective cusp angle is the angle created by the horizontal reference plane and the average cusp slope. The sagittal protrusive effective cusp angle is the effective cusp angle during protrusive movement. The term "frontal lateral effective cusp angle on the working and nonworking side" refers to the effective cusp angle during lateral movement on both sides(10).

#### **Deviation of the cusp angle:**

Conversely, the condylar and incisal route inclination variances were 43% and 32% of the mean, respectively. Compared to the condylar and incisal paths, the cuspal morphology data was, on average, four times more trustworthy. Consequently, the cusp angle should be equally reliable since it is a feature of cuspal morphology(10).

The aforementioned information made it clear that the cusp angle does not depict individual differences in the incisal or condylar paths.

#### **Standard Value of the Cusp Angle:**

The most trustworthy occlusion reference is thought to be the cusp angle. However, it is well known that caries, abrasions, and restorative procedures cause occlusal morphology to change from its original form in maturity. Specifically, there are no cusps to use as a reference when teeth are lost. Therefore, the cuspal morphology of a typical dental office patient is unreliable and cannot be utilized as an occlusion reference. If the value of the cusp angle at the time of eruption is used as a reference for occlusion, then creating a restoration according to this method should be excellent for the patient because there aren't many changes in the cusp morphology of permanent teeth just after eruption(10).

#### **PATIENT ADAPTABILITY:**

Individual patients respond differently to occlusal anomalies in terms of adaptation. While some people can endure noticeable malocclusions without exhibiting overt symptoms, others cannot handle relatively insignificant occlusal abnormalities. Without displaying immediate symptoms, the majority of individuals appear to be able to adjust to minor occlusal defects(9).

**Lowered Threshold:** It is usually easy to diagnose patients with low pain thresholds. Every suffering is easily recognized by them. However, a lower threshold is only a sign of inadequate adaptation to occlusal differences and should not be confused with hypochondria. A patient's tolerance or adaptability will vary; it will be lower during periods of emotional stress and general malaise, and clinical symptoms such excruciating headaches, muscle spasms, and pain may manifest during these periods(9).

**Raised Threshold:** Even though there are several indications of ongoing pathologic processes, people who have adjusted to their current malocclusions may say they are quite at ease with their teeth. Occlusal therapy, however, may be recommended even in the absence of discomfort or patient complaints in order to avoid or reduce further tooth wear and subsequent injury to the TMJs or musculature(9).

#### **OBJECTIVES OF SELECTING CORRECT OCCLUSAL SCHEME AND MORPHOLOGY:**


- To minimize lateral forces during mandibular excursive movements in order to appropriately direct the occlusal forces.
- To stabilize the occlusion.
- To improve the efficiency of mastication.
- To lessen wear caused by friction(6).

#### **OCCLUSAL INTERFERENCES:**

Unwanted occlusal interactions known as interferences can cause mandibular deviation during closure to maximal intercuspation or impede easy transitions to and from the intercuspal position. Occlusal interferences come in four different varieties:(2)

- i. Centric
- ii. Working
- iii. Non-working
- iv. Protrusive





- i. Centric interference is an early contact that occurs when the mandible closes with the condyles in the glenoid fossae at their ideal position. The mandible will deflect as a result, either laterally, anteriorly, or posteriorly(2).
- ii. When the maxillary and mandibular posterior teeth come into contact on the same side of the arches as the direction in which the mandible has migrated, a working interference could happen. It is an interference if the touch is sufficiently heavy to disocclude anterior teeth(2).
- iii. A nonworking interference is an occlusal contact between maxillary and mandibular teeth on the side of the arches opposite the direction in which the mandible has migrated during a lateral excursion. The interference that does not function is especially harmful. Changes in mandibular leverage, forces acting outside the teeth's long axes, and disturbance of normal muscle activity have all been linked to the potential of harming the masticatory apparatus(2).
- iv. A protrusive interference is a premature contact occurring between the mesial aspects of mandibular posterior teeth and the distal aspects of maxillary posterior teeth. Because of the proximity of the teeth to the muscles and the oblique vector of the forces, contacts between opposing posterior teeth during protrusion are potentially destructive and interfere with the patient's ability to incise properly(2).

#### **CONSEQUENCES OF POOR OCCLUSION:**

- Excessive tooth mobility
- Irreversible pulpal damage
- Neuromuscular discomfort
- Bruxism
- Soft tissue trauma

#### **Causes and treatment:**

- Impaired centric or eccentric connections result in irreversible pulpal injury and tooth mobility.
- If the issue is identified early and fixed, tooth mobility can be restored; however, if it is not, prostheses may fail because of perforation and esthetic loss.
- Endodontic therapy should be used to address pulpal damage after occlusal correction.
- To treat mobility caused by traumatic occlusion on teeth compromised by periodontal disease and long-term occlusal interferences on healthy teeth, FPD is removed and teeth are splinted with a detachable prosthesis.
- Extraction is required if movement is significant.
- Occlusal issues are also caused by a changed vertical dimension.
- This must be recognized and corrected since it is the consequence of inadequate treatment planning.
- Additionally, it could result in temporomandibular problems.

#### **OCCLUSION IN IMPLANT SUPPORTED FIXED DENTAL PROSTHESIS:**

The restoration on an implant differs greatly from the one supported by teeth. The practitioner cannot fully justify or rationalize applying the same concept of occlusion as that of the natural dentition because implant-supported/retained dentures lack the cushioning effect of periodontal ligaments, making it impossible to compare how stress acts on these restorations and how these restorations respond to these stresses with that of the natural dentition. Therefore, when it comes to implant-based rehabilitation, the idea of Implant Protected Occlusion is being used. For an implant-supported prosthesis, a mutually protected occlusion with anterior guiding and equally distributed contacts with wide freedom in centric relation is recommended.(4)

#### **IMPLANT PROTECTIVE OCCLUSION:**

- No premature occlusal contacts or interference;
- Mutually protected articulation;
- Implant body angle to occlusal load;

- Cusp angle of crowns (cuspal inclination);
- Cantilever or offset loads;
- Crown height (vertical offset);
- Implant crown contour;
- Occlusal contact positions;
- Timing of occlusal contacts;
- Protect the weakest component.(6)

#### **OCCUSION ON IMPLANT SUPPORTED FPD:**

- i. Direct forces along the implant body's long axis.
- ii. Reduce the implant's lateral forces.
- iii. When required, apply lateral stresses as far anteriorly in the arch as you can.
- iv. Distribute lateral stresses over as many teeth and implants as possible if anterior movement or minimization is not feasible(9).

## **II. CONCLUSION:**

Since each instance is different, restoring occlusion in patients with badly damaged dentition can be difficult. Due to significantly differing opinions on the selection of an acceptable occlusal plan, restoring a weakened dentition is fraught with anxiety. All attempts should be made to create an occlusal interface so that the periodontium of teeth, masticatory muscles, and TMJs work in harmony with one another. The treatment concepts are universal, and all functional aspects are interrelated. During rehabilitation operations, the patient's needs should be taken into consideration to achieve the best possible occlusion. No one rule can be applied to every patient since chewing efficiency can vary throughout a broad spectrum of occlusal shapes and types of occlusal schemes(6).

## **REFERENCES:**

- [1]. The Glossary of Prosthodontic Terms 2023. The Journal of Prosthetic Dentistry. 2023 Oct;130(4):e1–3.
- [2]. Shillingburg HT, Sather DA, editors. Fundamentals of fixed prosthodontics. Fourth edition. Chicago Berlin Tokyo: Quintessence Publishing Co, Inc; 2012. 1 p. (STAT!Ref electronic medical library).
- [3]. Rangarajan V, Gajapathi B, Yogesh PB, Ibrahim MM, Kumar RG, Karthik P. Concepts of occlusion in prosthodontics: A literature review, part I. The Journal of Indian Prosthodontic Society. 2015;15(3).
- [4]. Occlusion in Fixed Partial Denture Understanding the Key before Designing the Lock.pdf.
- [5]. Zarina, Rita & Jaini, JL & Raj, Rajan. (2017). A Systematic Approach for Rehabilitation of Occlusion in Fixed Partial Denture. International Journal of Preventive and Clinical Dental Research. 4. 136-141. 10.5005/jp-journals-10052-0097.
- [6]. Gupta R, Sharma S, Vashisht D, Vignesh A, Kumari M. Occlusion in Fixed partial dentures -A review. Journal of Advanced Medical and Dental Sciences Research. 2022;10(12).
- [7]. Hazra R, Kumar D, Srivastava A, Khattak A, Kalia D. Occlusal forms and philosophies in full mouth rehabilitation: A literature review. APRD. 2021 Jun 28;7(2):79–83.
- [8]. Pasricha N, Sidana V, Bhasin S, Makkar M. Canine protected occlusion. Indian J Oral Sci. 2012;3(1):13.
- [9]. Rosenstiel SF. Contemporary Fixed Prosthodontics.
- [10]. Apurva Deshmukh - Occlusion in Fixed partial dentures (Library Dissertation)