

White Sponge Nevus In A Middle Aged Patient: A Rare Case Report

Rashmi Yadav¹, Guruprasad R², Neeta Sharma³, Shruti Pathania⁴, Deeksha Sharma⁵,
Probin Kumar Vishwas⁶

¹PG Student, HP Government Dental College, Shimla

²Professor and HOD, HP Government dental College, Shimla

³Professor, HP Government dental College, Shimla

⁴Assistant Professor, HP Government dental College, Shimla

⁵PG Student, HP Government Dental College, Shimla

Abstract

White sponge nevus (WSN) is a rare hereditary dyskeratotic hyperplasia of mucous membranes. It is an autosomal dominant disorder with variable penetrance. We report a case of WSN in a healthy 41-year-old male with no history of familial involvement. A white smooth plaque with no erythema or other structural abnormalities was observed, which confirmed the diagnosis of WSN histopathologically. Patient was given 0.2% chlorhexidine for 2 weeks which resolved the lesion completely.

Keywords: Cannon's disease, Genodermatosis Exfoliative leukoedema, White sponge nevus.

Date of Submission: 12-02-2025

Date of Acceptance: 22-02-2025

Introduction

White sponge nevus (WSN), also known as Cannon's disease, is a rare autosomal-dominant disorder mainly affecting the oral mucosa characterised by soft, white, corrugated plaques, usually appear at birth or in early childhood, but sometimes the condition develops during adolescence[1]. Other names of this disorder are Familial white folded mucosal dysplasia, Hereditary mucosal leukokeratosis, Nevus of Cannon, White folded gingivostomatitis, Exfoliative leukoedema[2]. It results from mutations in keratin genes, specifically K4 and K13, leading to abnormal epithelial maturation and hyperkeratosis without systemic involvement.[3]Prevalence rate is below 1 in 2,00,000[4]. It exhibits no race or gender predilection. The diagnosis is generally reached by combining its histopathologic features, clinical appearance, and the patient's family history[5]While generally asymptomatic and requiring no treatment, various therapies including topical agents and surgical interventions have been attempted with mixed success, often resulting in recurrence[6].

Case Report

A 41-year-old male came to the Department of Oral Medicine with the complaint of whitish growth on the both side inner cheek region since 1 year. He also complained of occasionally traumatising the affected area while chewing and mild burning sensation. The patient's general health was reportedly good. The patient denied presence of a similar condition in immediate family members or any similar lesions elsewhere on his body. On extra oral examination there was no gross asymmetry and no regional lymphadenopathy. On intra oral examination, there were similar bilateral white plaques on the buccal mucosa, extending from angle of mouth to pterygomandibular region anteroposteriorly and superoinferiorly from coronal region of maxillary teeth to the coronal region of mandibular teeth approximately 5*2cm. lesion was non scrapable. The plaques were smooth with velvety texture and irregular, well-defined borders. There was no erythema(FIG.1). The margins were distinct and there was no dental attrition and. Oral hygiene was good and other oral structures were normal in appearance. Provisional diagnosis of White Sponge Nevus was made and differential diagnosis were Leukoedema, Leukoplakia, Frictional keratosis, Hereditary benign intraepithelial dyskeratosis, Pachyonychia congenita, lichen planus. An incisional biopsy was performed. In histopathologic examination, oral mucosa covered by stratified squamous epithelium revealed prominent hyperparakeratosis, marked acanthosis and clearing of the cytoplasm of cells in the spinous layer with perinuclear eosinophilic condensation of epithelial cells. Underlying connective tissue was normal in appearance with rare chronic inflammatory cell infiltration

(FIG.2). Based on clinical data and histopathologic findings, the lesion was consistent with white sponge nevus. Patient was given 0.2% chlorhexidine mouthwash once daily at night time for 15 days.when the patient reported after 15 days the lesion was completely healed(FIG.3). A 3-month follow-up was recommended.

Discussion

WSN is a rare hereditary disease that is transmitted as an autosomal dominant disorder. In the present case, the patient had no familial history of the disease. The lesions of WSN usually appear at birth or in early childhood; sometimes, the condition develops during adolescence; However, it detected in 40 years of age in this case[3]. In most instances, the lesions are seen bilaterally as symmetrical, thickened, white, corrugated or velvety, diffuse plaques that affect the buccal mucosa as observed in the present case. Extraoral mucosal sites, such as the nasal, esophageal, laryngeal and anogenital mucosa, also may be affected in some cases though less common. The plaques in our patient were confined to the oral mucosa and were not found to occur elsewhere. A few people may feel a roughness, a burning pain, or a loss of taste, In this case patient gave history of mild burning sensation[7]. WSN can have superimposed candida infection, which may cause it to be symptomatic at times[6] WSN may superficially appear clinically similar to several other oral white lesions that have varied clinical behaviours and treatment protocols. It is important that the condition is distinguished from the other entities to avoid unnecessary treatment. The diagnosis of WSN is usually based on its distinctive clinical appearance and history. However, exfoliative cytologic preparations or biopsy can aid in the diagnosis and may be performed to rule out other lesions. Various treatments were tested to reduce the clinical presentation of the white sponge nevus. These include beta-carotene, chlorhexidine, antibiotics (penicillin, azithromycin, etc.), antihistamines, local applications of retinoic acid, tetracycline mouth rinses, surgical resection, and laser ablation[6]. In the present case the patient was given 0.2% chlorhexidine mouthwash[8].

Treatment	Age	Sex	Family history	Response	Recurrence/Maintenance therapy	Author s
Tetracycline rinses (0.25%,5ml for 1 min) 2 times per day for 12 weeks	23	F	Yes	Partial	No	Otobe et al.
Tetracycline rinses (0.25%,5ml for 1 min) 2 times per day for 12 weeks	27	F	Yes	Partial	No	
Tetracycline rinses (0.25%,5ml for 1 min) 2 times per day for 12 weeks	46	F	No	Complete	No	
Tetracycline rinses (0.25%,5ml for 1 min) 2 times per day for 12 weeks	24	M	No	Complete	5 months	
Tetracycline 250 mg once per day for 4 weeks	1.5	M	Yes	No	-	Lamey et al.
Penicillin 250 mg once per day for 2 weeks				No		
Tetracycline 250 mg once per day for 4 weeks	24	M	Yes	Partial	8 weeks/tetracycline 250mg per week	
Tetracycline 250 mg once per day for 30 weeks				Partial		
Amoxicillin 250 mg 3 times per day for 4 weeks	52	M		Partial	8 weeks/tetracycline 250mg per week	
Minocycline 50 mg 2 times per day for 6 weeks				No		
Penicillin 250 mg 4 times per day for 4 weeks	11	F	No	Partial	Yes/Penicillin 250mg per week	
Penicillin 250 mg once per day for 20 weeks				Partial		
Tetracycline 250 mg 4 times per day for 4 weeks	32	M	Yes	Partial	10 weeks	

Amoxicillin 250 mg 3 times per day for 4 weeks				Partial		
Amoxicillin 125 mg 3 times per day for 4 weeks	6	F	Yes	No	-	
Penicillin G procaine 1.2 MU im once per day for 3 days	36	F	No	No	4 months	Lim et al.
Tetracycline rinse 0.25% single dose				Partial		
Doxycycline 200 mg once per day and tetracycline rinse 0.25% 2 times per day for 12 weeks	26	M	Yes	Complete	-	Contre ras-steyls et al.
Chlorhexidine rinse (0.12%,5ml for 45 seconds) 2 times per day for 8 days	15	M	Yes	Partial	Chlorhexidine rinse 1 week per month	satriano et al.
Chlorhexidine rinse (0.12%,5ml for 45 seconds) 2 times per day for 8 days	50	F	Yes	Partial	Chlorhexidine rinse 1 week per month	
Amoxicillin 500 mg 3 times per day for 10 days	46	M	No	No	-	Pique et al.
Retinoic acid (0.01% aqueous solution) for 4 weeks				Complete	intermittent regime of topical retinoids	
Oral adhesive excipient containing 0.1% triamcinolone acetonide and 0.1% retinoic acid once per day for 8 weeks Doxycycline 100mg once per day for 6 weeks	46	M	No	No Partial	No	Amores-martin et al.

Table 1: published cases of white sponge nevus: therapeutic guidelines, clinical response and recurrences (9)

Abbreviations: F, female; M, male; MU, million units; IM, intra muscular.

In conclusion, this case report is presented for its rarity and also for the striking resemblance of the lesions to other lesions that present themselves more commonly in the oral cavity.

References

- [1] Nikhil Shyam, Bernard A. Cohen, In Pediatric Dermatology (Fifth Edition), 2022
- [2] Sanjeeta N, Nandini DB, Premrata T, Banerjee S. White Sponge Nevus: Report Of Three Cases In A Single Family. J Oral Maxillofac Pathol. 2016 May-Aug;20(2):300-3. Doi: 10.4103/0973-029X.185915. PMID: 27601826; PMCID: PMC4989564.
- [3] Qiao Y, Liu B, Bai R, Cai J, Peng Q. White Sponge Nevus Caused By Keratin 4 Gene Mutation: A Case Report. Genes (Basel). 2022 Nov 22;13(12):2184. Doi: 10.3390/Genes13122184. PMID: 36553451; PMCID: PMC9777919.
- [4] Michael Glick, DMD, FDS Rcsd Martin S. Greenberg, Burket's Oral Medicine Thirteenth Edition.
- [5] PHILIP SAPP DDS, MS, ... GEORGE P. WYSOCKI DDS, PHD, In Contemporary Oral And Maxillofacial Pathology (Second Edition), 2004
- [6] Elfatoiki FZ, Capatas S, Skali HD, Hali F, Attar H, Chiheb S. Oral White Sponge Nevus: An Exceptional Differential Diagnosis In Childhood. Case Rep Dermatol Med. 2020 Aug 26;2020:9296768. Doi: 10.1155/2020/9296768. PMID: 32908720; PMCID: PMC7471808.
- [7] Aghbali A, Pouralibaba F, Eslami H, Pakdel F, Jamali Z. White Sponge Nevus: A Case Report. J Dent Res Dent Clin Dent Prospects. 2009 Spring;3(2):70-2. Doi: 10.5681/Joddd.2009.017. Epub 2009 Jun 5. PMID: 23230487; PMCID: PMC3517290.
- [8] R.A. Satriano, E. Errichetti, A. Baroni. White Sponge Nevus Treated With Chlorhexidine. J Dermatol, 39 (2012), Pp. 742-743 Http://Dx.Doi.Org/10.1111/J.1346-8138.2012.01508.X
- [9] Amores-Martín E, Melé-Ninot G, Del Alcázar Viladomiu E, Fernández-Figueras MT. Tratamiento Del Nevus Blanco Esponjoso. Aportación De Un Caso Con Respuesta A Doxiciclina Oral Y Revisión De La Literatura. Actas Dermosifiliogr. 2021;112:463---466.

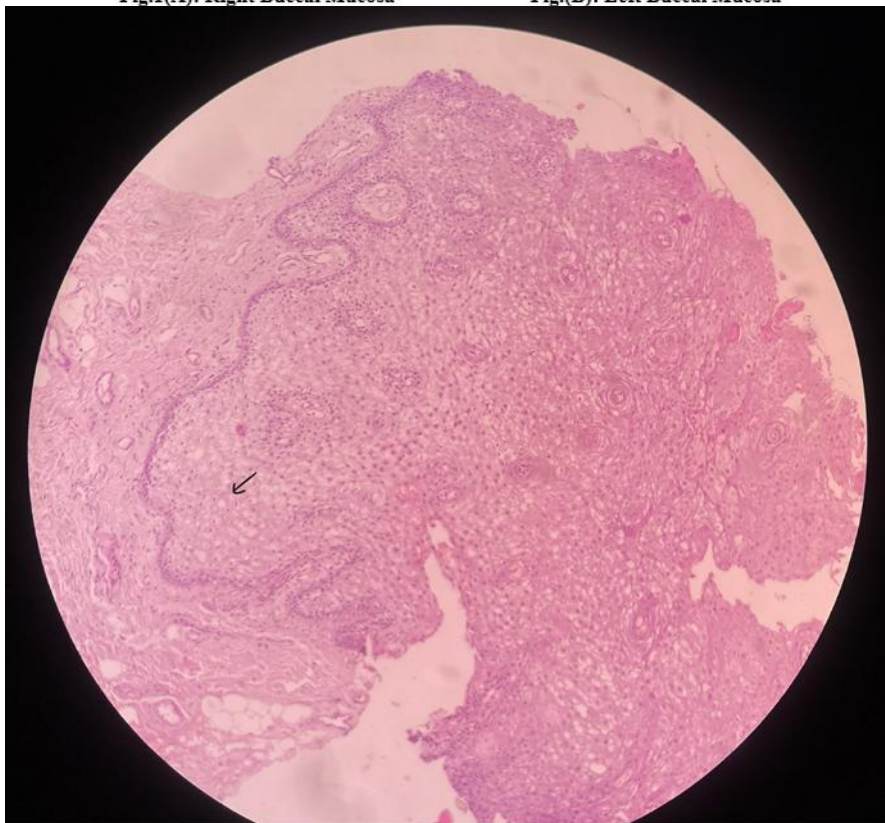
Figures:

Fig.1(A)&(B) Showing Symmetrical Irregular, Well-Defined Borders.White Plaques And Patches On The Buccal Mucosa.

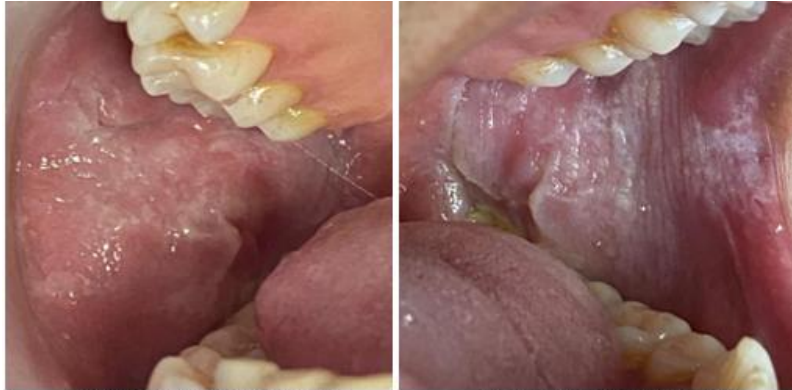

Fig.1(A): Right Buccal Mucosa

Fig.(B): Left Buccal Mucosa



**Fig.2: Slide Was Observed Under 10x Magnification, Stratified Squamous Epithelium Revealed Prominent Hyperparakeratosis And Marked Acanthosis With Clearing Of The Cytoplasm Of Cells In The Spinous Layer.
Arrow Showing Acanthosis Of Spinous Layer.**

Fig.3 (A) & (B) Post Treatment

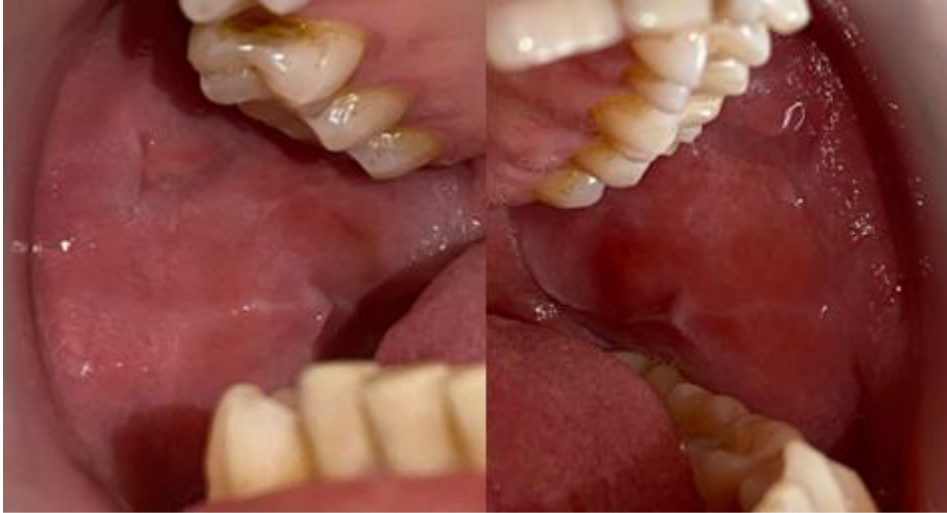

Fig.3(A): Rt. Buccal Mucosa

Fig.3(B) Lt. Buccal Mucosa