

# Radix Entomolaris Is A Challenge To Endodontic Treatment A Brief Review And A Case Report

Dr. Binayak Saha

Dr. Mousumi Biswas

Assistant Professor, Dr. R. Ahmed Dental College & Hospital, Kolkata.

Associate Professor, Dr. R. Ahmed Dental College & Hospital, Kolkata.

---

## Abstract:

**Background:** Mandibular first molars often presented with extra root either on disto-lingual or mesiobuccal aspect. Radix Entomolaris is present distolingually and its presence not only complicate the root canal system but if undetected leads to treatment failure. Cleaning and shaping of root canals during endodontic treatment is not possible until illustrative knowledge regarding such complexities is acquired by a clinician. Inadequate proficiency regarding such aberrations of root canals may cause missed or undetected canals leading to treatment failure.

**Key Words:** RE (Radix Entomolaris), CBCT, Micro-CT, IOPA Xray, MB (mesiobuccal), ML (mesiolingual), DB (distobuccal), DL (distolingual)

---

Date of Submission: 29-01-2025

Date of Acceptance: 09-02-2025

---

## I. Introduction

Root canal system of a tooth is often very complex. It is not only present as a single canal running uniformly from orifice of canal to its apex but it may split or unite during its course at different levels and at different planes increasing complexity. The success of endodontic treatment not solely depends on proper biomechanical preparation, irrigation or obturation in three dimensions but also on the proper diagnosis and detailed knowledge about roots and root canal system of treating tooth. Tooth roots show lots of variation in respect to size, shape and number and its canal morphology.

Mandibular molar teeth often exhibit an extra root on its either buccal or lingual aspect. Radix Entomolaris was named by Carrabelli<sup>1,2</sup> in 1844, for the extra roots present on distolingual aspect of mandibular first molar teeth whereas extra root on mesiobuccal aspect of mandibular molar teeth is named as Radix Paramolaris. Mandibular first molars have two roots in 94.6% whereas extra-roots on distolingual aspect is 5.3%<sup>3</sup>

Accessory roots can be formed as result of either splitting of or by infoldings of Hertwig's Root Sheath during formative stage. The theories that postulate the occurrence of RE is the influence of external factors during odontogenesis or an atavistic gene. Though aetiology was not specific some ethnic & genetic factors, localised trauma or external pressure may have some influence on such development.

Radix Entomolaris in mandibular first molar teeth exhibit certain ethnic predominance. Studies in the literature showed that the people exhibiting Mongoloid characteristics, the Chinese and the Eskimos exhibit a higher rate of prevalence of Radix Entomolaris i.e. 5–30% whereas Africans, Eurasians, white Caucasians and Indians populations exhibit less than 5%.<sup>4-10</sup> RE can be observed less frequently on 2<sup>nd</sup> mandibular molar teeth whereas bilateral occurrence has a frequency of 50–67%.<sup>11</sup>

**According to the cervical portion of RE Carlsen & Alexandersen in 1990 classified RE as :**<sup>12</sup>

- 1) Type A & Type B: Distally located cervical part of RE with two normal and one normal distal root components respectively.
- 2) Type C: Mesially located cervical part
- 3) Type AC: Central location, cervical part is in between the distal and mesial root components.

**Moor et al. in 2004 classified RE on the basis of curvature:**<sup>13</sup>

- 1) Type I : Straight root / straight canal
- 2) Type II: initially curved at entrance which continues as a straight root/root canal.
- 3) Type III: initial Curve in the coronal third of the root canal and second curve at middle third continuing to the apical third.

**Song et al. in 2010 suggested two more variants of RE:**<sup>14</sup>

- 1) Small type: length shorter than half of length of distobuccal root.
- 2) Conical type: smaller than small type with no root canal within it.

According to Zhang et al.<sup>15</sup> classification on the basis of number of roots and number of canals in mandibular molars, RE come under variant 5 & variant 6. Both the variants show three separate roots with either three canals(MB,DB,DL) or four canals( ML,MB,DB,DL) respectively.

Aberrant root morphology along with variant root canal system always provides an extra challenge to the clinicians during endodontic treatment. So without knowledge of such aberrations and variations in the root canal system success of treatment remains questioned.

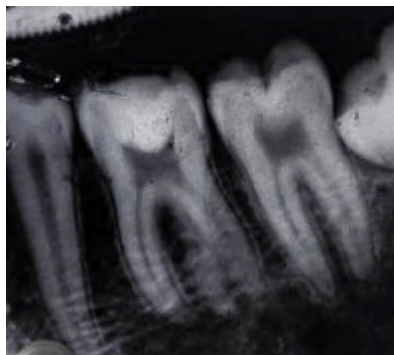## II. Case Report:

A male patient aged about 37 years came to the outpatient department of Dr R. Ahmed Dental College & Hospital, Kolkata with acute pain in lower jaw.

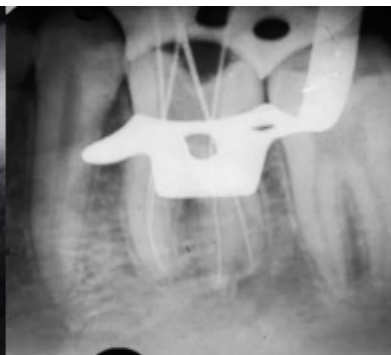On clinical examination it was seen that the buccal cusp of mandibular right first molar ( 46 no.) tooth was fractured and was tender on percussion. Pulp vitality test of the tooth gives delayed response. Radiological examination revealed thickening of PDL space. After diagnosed as the tooth was affected by irreversible pulpitis, endodontic treatment of affected tooth was considered as treatment option.

After isolation with rubber dam an access cavity was prepared on the affected tooth under local anaesthesia using TC round bur in air turbine handpiece with air and water spray. After getting access into the pulp chamber roof of pulp chamber was removed and provide an divergence on walls of access cavity using Endo -Z bur.

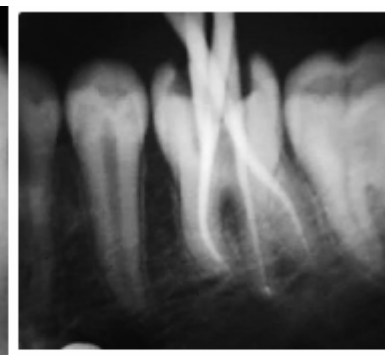
After irrigation of pulp chamber orifices of the root canals were located using DG 16, Maillefer. During exploration an orifice distolingual to distal canal was observed and after taking radiograph the presence of RE was confirmed. Working length of all the canals were confirmed by apex locator, Root Zx, and also by IOPA X-rays. Biomechanical preparation was then done using Hyflex CM files with adequate irrigation with 5.25% NaOCl. Irrigation was done with Endoactivator and obturation was done by corresponding Gutta Percha cones using resin sealer, AH Plus.



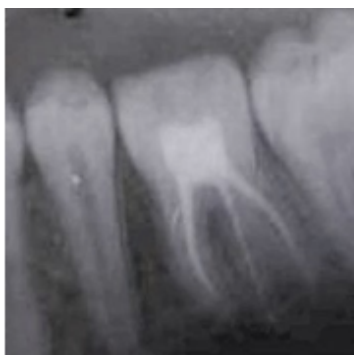Pre-operative X-Ray



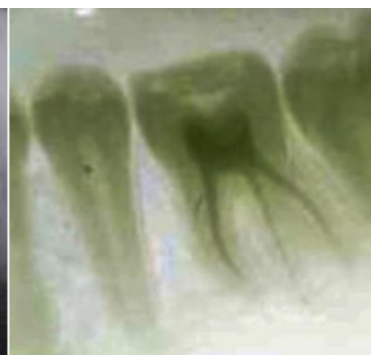WL X-Ray



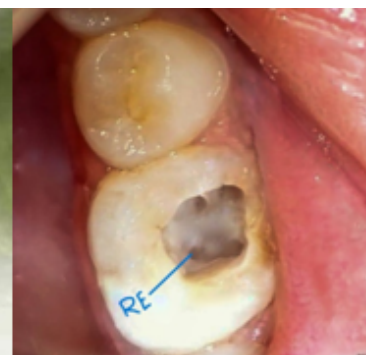Master GP X-



Post-operative X-



Post-operative X-



Occlusal X-Ray

### III. Discussion

Though aetiology of development of radix entomolaris is not clear, its presence has significant clinical implication during performing endodontic treatment. Complex root canal morphology usually hinders cleaning and shaping of root canal system and often may lead to missed & undiagnosed canal causing incomplete biomechanical preparation and treatment failure. Without Proper knowledge, accurate diagnosis and interpretations of radiographs successful endodontic treatment can never be achieved.

Primary importance should be given on identifying the root canal anatomy. Sometimes clinical inspection & analysis of cervical root morphology with periodontal probe can help to detect the presence of extra root<sup>16</sup>. Clinically the presence of bulbous crown, extra cusp, prominent distolingual lobe, cervical convexity and complex external contour of furcal region can give a clue for the presence of RE.<sup>17</sup>

Radiographs, CBCT or Micro CT. are the useful aid to detect RE. Obscure image of distal root or root canal or presence of double PDL space on radiograph hints for the presence of RE. Images of distal roots are usually overlapped on straight radiograph if both are lies on same distolingual plane. To overcome such difficulties X-rays at different angulations often enables visualization of both the roots. Clerk's rule or SLOB rule i.e. 20° mesial/distal angulated X-ray can provide distinct image of RE. CBCT or Micro CT provides images at different horizontal cross sections and three-dimensional reconstruction of images of the tooth that enables identification, location, curvature & angulation of the RE.

The orifice of RE is often located distolingual to the main canal of distal root. So, the shape of access cavity may be required to be altered from triangular to rectangular to expose the hidden extra canal and for its proper endodontic treatment.<sup>18</sup> Localization of root canals can be done using anatomical dark line & bleeding points on the pulpal floor, bubbling test with NaOCl or with aid of dye staining. Adjunctive tools like dental Loupes, Dental Microscope can be helpful in detecting such orifices.<sup>19</sup>

RE roots is characterised by curvatures of various degrees that should be manipulated carefully to maintain its curvature and to avoid procedural errors. A severe root inclination or canal curvature as in type III RE can cause shaping aberrations like straightening of the canal, ledge formation and loss of working length or canal transportation. The use of flexible nickel-titanium rotary files allows a more centered preparation with restricted enlargement of the coronal canal third or orifice relocation After negotiation of the canal upto its working length instrumentation with flexible NITI file system with frequent irrigation and recapitulation can provide effective biomechanical preparation before obturation and brings about satisfactory results.

### IV. Conclusion:

Complexed root canal morphology provides an extra challenge to treat endodontically. Hence adequate knowledge about variant root canal anatomy, advanced diagnostic tools and the skill of operation can be dealt with such morphological alterations.

### References:

- [1] Al Nazhan S. Incidence Of Fourth Canal In Root Canal Treated Mandibular First Molars In A Saudi Arabian Sub-Population. *Int Endod J* 1999; 32:49-52.
- [2] Calberson FL, De Moor RJ, Deroose CA. The Radix Entomolaris And Paramolaris: Clinical Approach In Endodontics. *J Endod* 2007;33(1):58-63.
- [3] CH Jonker "Root And Canal Morphology Of The Maxillary First Molar: A Micro-Computed Tomography-Focused Observation Of Literature With Illustrative Cases. Part 2: Internal Root Morphology" *SADJ* March 2024, Vol. 79 No.2 P75-85
- [4] Turner CG. Three-Rooted Mandibular First Permanent Molars 16. And The Question Of American Indian Origins. *Am J Phys Anthropol.* 1971;34(2):229-41.
- [5] Curzon M, Curzon J. Three-Rooted Mandibular Molars In The 17. Keewatin Eskimo. *J Can Dent Assoc.* 1971;37(2):71.
- [6] Yew S-C, Chan K. A Retrospective Study Of Endodontically 18. Treated Mandibular First Molars In A Chinese Population. *J Endod.* 1993;19(9):471-3.
- [7] Reichart P, Metah D. Three-Rooted Permanent Mandibular 19. First Molars In The Thai. *Community Dent Oral Epidemiol.* 1981;9(4):191-2.
- [8] Walker R, Quackenbush L. Three-Rooted Lower First Permanent 20. Molars In Hong Kong Chinese. *Br Dent J.* 1985;159(9):298-9.
- [9] Curzon M. Three-Rooted Mandibular Permanent Molars In 21. English Caucasians. *J Dent Research.* 1973;52(1):181-.
- [10] Ferraz J, Pécora JD. Three-Rooted Mandibular Molars In 22. Patients Of Mongolian, Caucasian, And Negro Origin. *Braz Dent J.* 1993;3(2):113-7.
- [11] Steelman R. Incidence Of An Accessory Distal Root On 24. Mandibular First Permanent Molars In Hispanic Children. *ASDC J Dent Child.* 1985;53(2):122-3.
- [12] A Shenoy & Kundabala Mala *Endodontics Principles & Practice Book*, Elsevier.
- [13] De Moor RJ, Deroose CA, Calberson FL. The Radix Entomolaris In Mandibular First Molars: An Endodontic Challenge. *Int Endod J* 2004; 37:789-99.
- [14] Song JS, Choi HJ, Jung IY, Jung HS, Kim SO. The Prevalence And Morphologic Classification Of Distolingual Roots In The Mandibular Molars In A Korean Population. *J Endod* 2010;36: 653-7.
- [15] Zhang R, Wang H, Tian YY, Yu X, Hu T, Dummer PM. Use Of Cone-Beam [16] Computed Tomography To Evaluate Root And Canal Morphology Of Mandibular Molars In Chinese Individuals. *Int Endod J.* 2011; 44:990-99.
- [16] Nishant Gandhi Et Al. Radix Enteromolaris *Journal Of Contemporary Dentistry* Jan-Apr 2012 Vol 2 Issue 1.

- [17] R Rajasekhar Et Al. Endodontic Management Of Radix Entomolaris: A Report Of Two Cases Journal Of Scientific Dentistry Vol-11 Issue- 2, 2021.
- [18] Swapna Munaga Et Al. The Radix Entomolaris And Paramolaris: A Review And Case Reports With Clinical Implications International Journal Of Scientific Study July 2020 Vol-8 Issue 4.
- [19] Pai AV, Jain R, Colaco AS. Detection And Endodontic Management Of Radix Entomolaris: Report Of Case Series. Saudi Endod J 2014;4(2):77. DOI: 10.4103/1658-5984.132723.