

## Use Of Endolaser For Female Intimate Harmonization. Reduction Of Localized Fat In The Pubic Symphysis

Moleiro, D<sup>1</sup>; Leite, MPF<sup>2</sup>; Ruiz-Silva, KR<sup>3</sup>; Ruiz-Silva, C<sup>4</sup>; Neto, JP<sup>5</sup>;

Montagner-Moura, JE<sup>6</sup>; Sobral, J<sup>7</sup>

(Department, College/ Faculdade CTA, Msc, PT, Biomedicine Brasil).

(Clínica Leite & Ruiz – PT, Biomedicine, Brasil)

Department, College/ Faculdade CTA, Pharmaceutical, Brasil).

(Department, College/ Faculdade CTA, Phd, Msc, PT, Brasil).

(Department, College/ Faculdade CTA, Dentistry Surgery, Brasil).

(Department, College/ Faculdade CTA, Biomedicine, Dentistry Student, Brasil).

(Department, College/ Faculdade CTA, Biomedicine Brasil).

---

### Abstract:

In recent years, intimate harmonization has emerged as a prominent area within the aesthetic modality, reflecting a significant evolution in the understanding and appreciation of the integral well-being of men and women. Previously restricted to more conventional aesthetic procedures, the demand for treatments that aim to rejuvenate and harmonize the intimate region has increased exponentially, driven by a combination of sociocultural factors, technological advances, longevity and a greater awareness of intimate health related to the individual's self-esteem.

Obesity and massive weight loss cause bulging and ptosis of the mons pubis. The pubic area can cause embarrassment to patients. In some cases, the deformity can even be seen under clothing.

The search for new technologies that enable safe and efficient results and that are minimally invasive has led to many studies on endolaser as a safe option with little or no downtime in the individual's routine, with minimal complications during handling.

Lasers with wavelengths of 1470nm and 980nm have different mechanisms of action in the tissue, which are used for various applications, including in aesthetic procedures, with a lipolytic effect on the subcutaneous tissue and 'tightening', improving the appearance of sagging and retraction.

**Objective:** The current study aims to evaluate the effects of the endolaser technique on dermal sagging and the accumulation of localized fat in the female pubic symphysis (mons veneris) in female intimate regions that cause unsightly damage, discomfort when wearing tighter clothing or even when practicing physical activity.

**Materials and Methods:** Study developed through a literature review in the databases: Google Scholar, PubMed and SciELO, where scientific articles were selected from the period 2007 to 2024. Clinical cases were also analyzed with monitoring of pre and post-treatment with endolaser, marking technique, anesthetic volume and usability protocol.

**Conclusion:** Through the review of articles and diverse clinical cases and their instances analyzed within this work, the technology proved to be effective in all patient profiles, both for localized fat and sagging in women who presented aesthetic complaints.

**Keywords:** adipose tissue, Endolaser, localized fat, intimate harmonization, 980 nm, 1470nm, gynecology

---

Date of Submission: 27-01-2025

Date of Acceptance: 07-02-2025

---

### I. Introduction

The Intimate aesthetics goes beyond simple aesthetic correction, representing a crucial intersection between health, self-esteem and quality of life. Women of different ages and stages of life, from birth, adolescence, maturity and especially those facing the changes arising from menopause, have found in these treatments a way to regain confidence in their own bodies, rediscover their sensuality and, above all, promote physical and emotional well-being.

Non-invasive and minimally invasive treatments have gained popularity as alternatives to surgical interventions. Laser lipolysis, such as Endolaser, has emerged as a promising approach for reducing localized fat with satisfactory response and minimal patient absence.

The World Health Organization (WHO) defines sexual health as a state of physical, emotional, mental and social well-being related to sexuality. It is not just about the absence of diseases, dysfunctions or illnesses,

but about a positive and respectful approach to sexuality and sexual relationships, as well as the possibility of having safe and enjoyable sexual experiences, free from coercion, discrimination and violence.

According to the WHO, healthy aspects of sexuality include:

1. **Autonomy and Body Awareness:** Having the right to make informed decisions about one's own body and sexuality, which includes free and informed consent to any sexual activity.
2. **Respect and Safety:** Sexual relationships should be free from coercion, discrimination and violence. Healthy sexuality is based on relationships of mutual respect, where partners respect each other's desires, boundaries and well-being.
3. **Reproductive Health and Access to Care:** This includes access to accurate information and services related to sexual and reproductive health, such as contraception, prevention of sexually transmitted infections (STIs) and antenatal and postnatal care.
4. **Sexual Pleasure and Satisfaction:** Sexual health also involves the ability to have satisfying and safe sexual experiences. Sexual pleasure is recognized as an important part of health and well-being.
5. **Sexual Education:** Promoting sexual health involves comprehensive sexual education, which should be evidence-based, age-appropriate, culturally sensitive and inclusive.
6. **Diversity and Inclusion:** Respecting and accepting the diversity of sexual expressions and orientations, recognizing the rights of all people to sexual health, regardless of their sexual orientation or gender identity.

## II. Anatomy

When meeting this demand, aesthetic professionals must not only be technically qualified to perform a variety of procedures, but, above all, must have a sharp clinical eye to correctly evaluate each case. This detailed assessment is essential to understand the individual needs of each patient, considering both the physical and emotional aspects that motivate the search for these treatments. When we approach the topic of intimate aesthetics, a generalization of terms is observed, as well as a lack of professional understanding, and therefore knowledge of female genital anatomy is important, followed by definitions of the unsightly and presentation of the treatment technique.

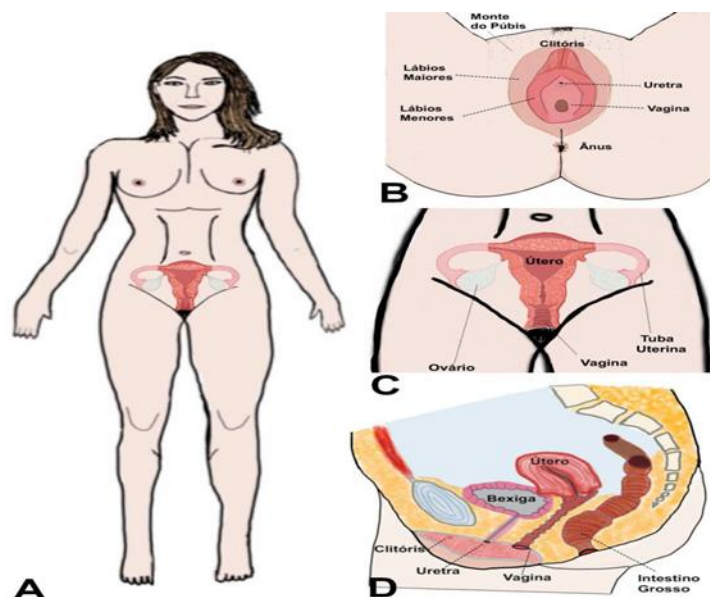


Figure 1 – Location of the Female Reproductive System (A), external genitalia (Vulva) (B), internal organs (C) and internal organs - side view (D).

### Pubic Symphysis

**Location:** The pubic symphysis is a joint in the anterior and central part of the pelvis, where the two pubic bones meet and connect.

**Structure:** It is composed of a fibrous cartilage called the interpubic disc, which connects the two ends of the pubic bones. This disc has elastic characteristics and acts as a shock absorber, providing stability and flexibility. Particularly in women, the pelvic cavity is mobile and its structures are fixed by ligaments and muscles, which facilitates the gestational function of accommodating the newborn, which as it develops acquires size and weight, fitting into the structure until its birth through the vaginal canal.

**Function:** The main function of the pubic symphysis is to provide structural support, allowing a limited degree of movement between the pubic bones. This joint is particularly important for activities such as walking, running and, in the case of women, to accommodate the changes during pregnancy and childbirth.

**Ligaments:** The joint is reinforced by ligaments, such as the superior and inferior pubic ligaments, which maintain stability and limit excessive movement between the pubic bones.

#### Suprapubic Region (Mons pubis)

**Location:** The suprapubic region, known as the Mons pubis, is located just above the pubic symphysis, covering it.

**Structure:** This area is composed of subcutaneous adipose tissue, which accumulates over the pubic bones. The amount of fat in this region can vary from person to person, depending on factors such as genetics, age, obesity, structural musculoskeletal dysfunctions and hormonal levels.

**Function:** Suprapubic fat serves as a protective layer, cushioning impacts and reducing pressure on the bones of the pelvis and internal genital organs. In addition, it has an aesthetic function and serves as an energy reserve, like adipose tissue in other areas of the body.

It is therefore determined that complaints related to the external region of the female genitalia are called vulva and procedures may be performed for aesthetic purposes and complaints related to the internal region are functional procedures and at this point will be directed to a rehabilitation or regeneration professional specializing in the area of women's health.

#### SUPRAPUBIC FAT

Suprapubic fat (mons veneris) has several functions, one of which is to protect and cushion the genitals and bony structures of the pelvis. It also acts as an energy store, as does fat in other parts of the body. However, excessive accumulation of fat in this region can be seen as an aesthetic nuisance by some people, leading to the search for treatments to reduce localized fat.

In evolutionary terms, this fat can also play a role in protection during physical activities, reducing the impact on the pelvic bones and genitals. Its form of deposition is also observed as a fundamental structure of comfort during female sexual intercourse, protecting against the rhythmic impact. However, its aesthetic impact, especially in women seeking a more defined body contour, reducing the protrusion of volume in this region when wearing tighter clothing or bathing suits, is a factor that generates interest in treatments targeted at this area.

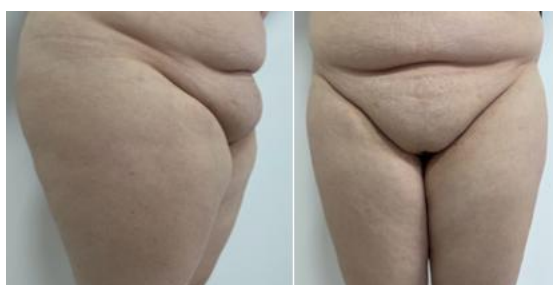

Figure 02: 36-year-old woman, two pregnancies, complains of localized fat volume, combined with sagging, sought treatment to improve her self-esteem and comfort when wearing tighter clothes. (author's correction)

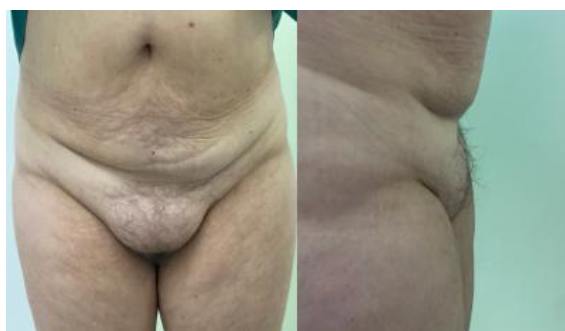

Figure 03: 54-year-old woman complains of localized fat volume in the pubic symphysis region, with discomfort when wearing a bikini or tight pants. (author's collection)

We must also consider pubic dermal laxity after major weight loss. Ptosis of the mons pubis is a common body deformity after gastroplasty and weight loss. Few articles have specifically addressed this topic with reference to the mons pubis (Kaluf, 2008; Alter, 2009; Nobrega, 2009).

In plastic surgery, excess adipose tissue in the mons pubis sometimes requires further refinement, such as additional liposuction and/or resection of excess skin at the lateral ends of the pubis toward the inguinal fold. A second surgical procedure may be necessary to resect the remaining excess tissue. However, it is inconvenient to perform vertical resections of skin and adipose tissue in the central portion of the mons pubis (Andre, 2023).

## ENDOLASER

The treatment of localized fat in the female pubic region using endolaser is a technique that uses laser energy transmitted through an optical fiber directly to the subcutaneous adipose tissue, with the aim of reducing fat, improving sagging skin and providing self-esteem.

The treatment of the female pubic region using endolaser technology has demonstrated clinical efficacy in the field of intimate harmonization. The technique is based on the application of laser energy transmitted through an optical fiber directly to the subcutaneous adipose tissue. This method promotes selective lipolysis of fat cells, with additional benefits in the firmness and quality of the skin, in addition to a positive impact on female self-esteem.

The endolaser works by emitting laser energy that is absorbed by the adipose tissue, generating controlled heat that leads to the destruction of fat cells (adipocytes) through a process called selective photothermolysis. This mechanism has been widely explored by authors such as Goldman et al. (2017), who describe the effectiveness of laser in minimally invasive treatments for body remodeling and skin sagging.

The mechanism of action of the subcutaneous laser is: photostimulatory, and photothermal, generating photothermolysis of the target tissue (Nilforoushzadeh; 2021; 2023).

In addition, studies such as that of Trelles et al. (2019) highlight the safety of the endolaser in sensitive areas due to its precision and thermal control, reducing the risk of damage to adjacent tissues. This is especially relevant when considering the pubic symphysis region, which has delicate anatomical structures that must be preserved.

## Indications and Benefits of Endolaser Treatment

1. Reduction of localized fat: Especially in areas resistant to other therapeutic approaches, such as the pubic symphysis.
2. Improvement of skin sagging: Ideal for treating mild to moderate sagging in the treated area.
3. Complementary to aesthetic procedures: Such as liposuction, to refine the results.

## Benefits:

1. High precision: Direct application to the target tissue allows for personalized and effective results.
2. Fast recovery: As it is minimally invasive, the procedure has a short downtime, facilitating the return to daily activities.
3. Dual effect: Combination of localized fat reduction and stimulation of collagen regeneration, resulting in improved skin texture and firmness.
4. Proven safety: Studies such as that of Ruiz-Esparza (2014) demonstrate a low rate of complications in appropriately selected patients.

## Endolaser Treatment Actions in the Pubic Region

### 1. Laser-Assisted Lipolysis:

The 1470nm diode laser applied during the endolaser procedure acts by promoting the emulsification of adipose cells. The laser energy heats the subcutaneous tissue, a layer of tissue with a concentration of adipocytes, to around 45-55 degrees, facilitating their functional alteration due to local thermal stress and resulting metabolism through macrophages that will generate a process of fragmentation and natural elimination by the body.

The thermal energy causes dysfunction of the adipocyte cell membrane, allowing the release of lipid content, which is then metabolized by the inflammatory process.

Some authors demonstrate that there is no thermal difference between 980 nm and 1470 nm in a comparative study. Mordon, 2008; uses 980 nm and reports what matters and thermal energy, we know that lipids are sensitive to thermal stimulus (Scrimall; 2015) and are thermally destroyed (adipocytolysis) lysis of the cell membrane and lipid peroxidation (Scrimall, 2013; Sigova, 2023; Roberto, 2020); we must remember that innervation has a myelin sheath, be careful with injury. We demonstrated through application and after dissection of a cadaver that there is no injury to innervation and does not affect glands

Diode laser devices (980 nm) appeared as smaller devices, with cheaper maintenance (Dornellas, 2013)

At 980 nm we have a different behavior of adipose tissue in relation to the action and absorption band, which provides lipolysis without the need for high energies (Badin, 2005);

Efficacy of 924 nm and 975 nm, lipolysis and dermal sagging (Wolfenson, 2011, 216; 2021; 2023)

Low energy with 980 nm increases the size of adipocytes and enters apoptosis (Mordan, 2008; Dornellas, 2013)

## 2. Skin Tightening and Sagging:

The heat generated by the laser also stimulates the production of collagen and elastin, promoting skin retraction. This effect is especially important for the pubic region, where the skin can be looser due to aging, weight changes through pregnancy or localized fat accumulation.

The subcutaneous laser technique has a thermolysis effect on the dermal tissue, generating fibroplasty, and indirect (photomodulation) and direct (photothermal effect) dermal toning. Biometric results demonstrate that the endolaser can increase the thickness, density and elasticity of the skin; (Nilforoushzadeh, 2022) with Patient satisfaction (90%) (Nilforoushzadeh, 2022; 2023)

Cutometer results indicate a significant increase in skin elasticity (Nilforoushzadeh, 2022) and skin ultrasound results indicated a significant increase in the density and thickness of the dermis and epidermis after treatment after 6 months (Nilforoushzadeh, 2022; 2023)

The thermal factor is the main cause of the dermal retraction and tightening effect (Marysabel, 2023); therefore we recommend associated use when there is dermal sagging.

Research has evaluated the effectiveness of photothermal therapy in the treatment of sagging skin and concluded that the procedure was safe and effective, producing clinical improvement (WOLFENSON, 2012; 2019; Dornelles, 2013; Wolfenson, 2015, 2024).

Collagen remodeling helps improve skin quality, reducing wrinkles and sagging in the treated area.

## 3. Coagulation Effect and Reduction of Bruising:

The laser promotes the coagulation of smaller blood vessels, which results in less bleeding and bruising during the procedure. This action reduces the risk of complications and accelerates postoperative recovery.

## 4. Reduction of Adipose Tissue Thickness:

The endolaser can be applied to different layers of fat to reduce the thickness of adipose tissue in the pubic region, providing a more sculpted and less voluminous appearance.

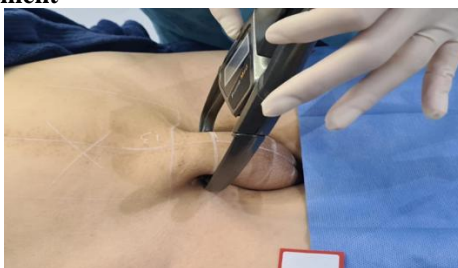## 5. Minimally Invasive Procedure:

Because it is minimally invasive, endolaser reduces recovery time compared to traditional fat removal methods, such as conventional liposuction.

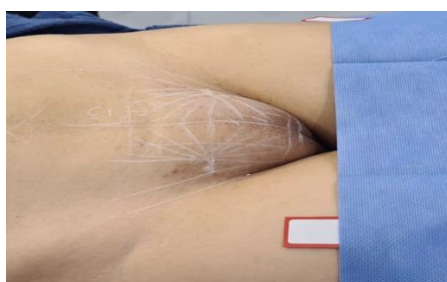### III. Material And Methods

#### Endolaser Protocol For Suprapubic Fat - Lipofemme

#### Endolaser Lipo Femme Appointment



**Figure 04: Marking and Documentation with adipometry collection**



**Figure 05: Planning for endolaser pubic symphysis**

PREGA DE ADIPOMETRIA	ABAIXO DE 3CM	ACIMA DE 3CM
FIBRA ÓPTICA	400ui	600ui
ENERGIA 980nm	4-6j	5-7j
ENERGIA 1470nm	3-5j	6-8j
QTD. DE ENERGIA 10X10cm	500j	750j

**Table Described By The Authors Through Their Clinical Practices**

#### Procedure Description

1. Assessment and Planning (perform trichotomy if necessary)
2. Photodocumentation at 90/45/Frontal angles
3. Perform adipometry fold at 3 points
4. Careful antiseptis of the region should be performed with a chlorhexidine degerming solution, aqueous or alcoholic, and dried with disposable paper.
5. Marking with a white dermographic pencil at 1 cm from the groin fold areas, marking 2 or 3 vector entries in 5 cm fans and 1 cm distance at the distal end of the vectors.
6. Perform anesthetic button with 2% lidocaine
7. Entry of the port and sliding into the subcutaneous tissue to deliver Klein's Solution with approximately 0.3 to 0.5 ml per vector and wait 10 min for anesthesia.
8. Introduce the 600iu fiber and apply the endolaser energy from the distal tip to the tip close to the orifice.
9. Repeat the process until the planned amount of energy delivery is reached, taking into account the protocol per adipometer fold volume.
10. Finish by cleaning the region and proceed with the dressing, which should be removed within 24 hours.

#### Post-Procedure Care

Patients should receive guidance on the care that should be taken in order to avoid contamination or adverse effects in the application region.

Avoid trauma in the region for at least 7 days, such as waxing procedures, swimming pools, saunas and sun exposure will be suspended for up to 30 days.

The use of more comfortable clothing, physical activities and avoiding sexual intercourse should continue for 7 days and lymphatic drainage should be started 72 hours after the procedure.

You can use taping on the area to avoid edema and discomfort or shapewear shorts with moderate compression, which will also make it easier.

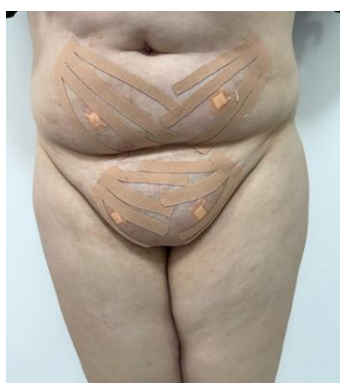

Figure 06: Post-procedure patient with immediate tapping application after the procedure and instructed to maintain it for 72 hours

#### Contraindication

1. History of allergy to laser or thermal action above 42 degrees Celsius
2. Women who are pregnant or breastfeeding
3. Skin infection in the area to be treated
4. Patients using anticoagulants or with coagulation disorders
5. Immunocompromised states
6. Diabetes
7. Areas of skin with vitiligo and psoriasis (Koebner phenomenon)

#### **IV. Result And Considerations On The Procedure**

The use of endolaser for localized fat in the pubic region is indicated for patients with fat that is resistant to diet and exercise. It is important to note that this procedure must be performed by qualified professionals and in a suitable clinical environment to avoid complications such as burns or fibrosis.

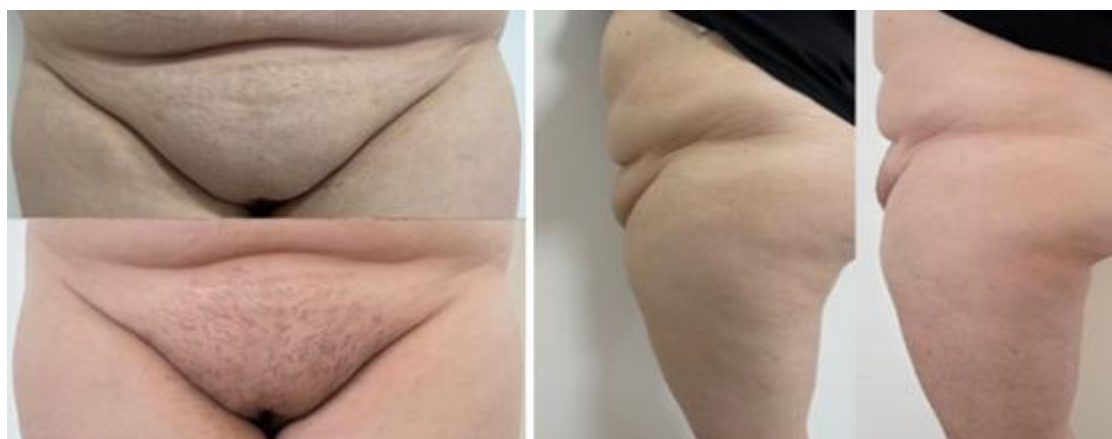

Figure 07: Before and After Photo Documentation

Subcutaneous laser is an interstitial connective remodeling technique based on 1470nm, 980 nm laser, aims to biostimulate and tone the tissues of the deeper layers through a thin optical fiber inserted under the skin in the superficial-medial hypodermis (Dell, Avanzato, 2022; Longo, 2022; Nilforoushzadeh, 2021; 2022; Kalliterna, 2023); Sadoughifar, 2023). The treatment is performed with a solid-state semiconductor laser AlGaAs using a disposable bare optical microfiber, capable of rejuvenating the skin and remodeling connective tissue, stimulating the production of new collagen and promoting skin tone (Dell, Avanzato, 2022; Longo, 2022; Nilforoushzadeh, 2021; 2022; Kaliterna, 2023).

The 660 nm guide itself increases ATP synthesis, angiogenesis, activation of growth factors and activation of HSP (Marysabel, 2023)

The flat bare fibers have a high power density concentrated at the tip and are mainly used for vaporization in Adipocytolysis 1470nm. (Dell, Avanzato, 2022; Longo, 2022; Nilforoushzadeh, 2021; 2022; Kalliterna, 2023)

The 980 nm and 660 nm diode laser can be used to photostimulate and even apply heat to the reticular dermis without the risk of burning or piercing with bare fibers.

Obesity and massive weight loss cause bulging and ptosis of the mons pubis. The pubic area can cause embarrassment to patients. In some cases, the deformity can be seen even under clothing, generating physical and especially psychological discomfort.

Intimate harmonization has emerged as a prominent area within the aesthetic modality, the demand for treatments that aim at rejuvenation and harmonization of the intimate region has increased exponentially, driven by a combination of sociocultural factors, technological advances, longevity and greater awareness about intimate health related to the individual's self-esteem.

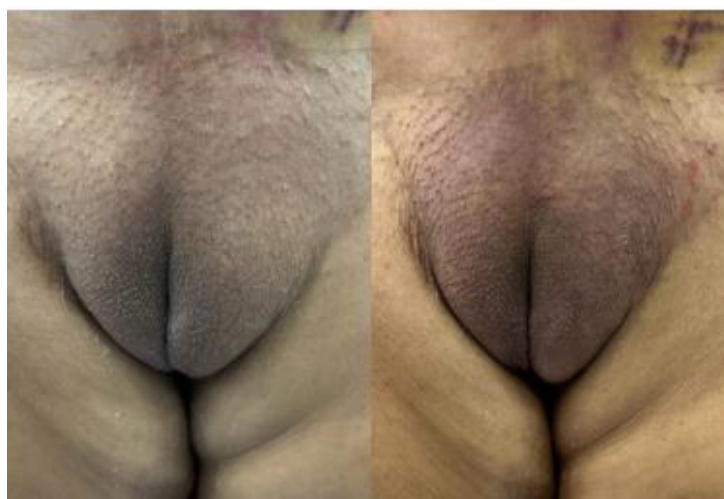

Figure 08: Woman ZFL, 80 Years Old - Patient Of Dra. Ana Carolina Rodrigues

## V. Conclusion

Through the review of articles and diverse clinical cases and their instances analyzed within this work, the technology proved to be effective in all patient profiles, both for localized fat and sagging in women who presented aesthetic complaints.

## References

- [1] BALDANZA, Renata Francisco; ABREU, Nelsio Rodrigues De. A Comunicação Na Mídia E Os Símbolos De Beleza: Reflexões Sobre Influência Da Indústria Cultural Da Difusão De Valores Estéticos. IN: INTERCOM SUDESTE 2006 - XI Simpósio De Ciências Da Comunicação Na Região Sudeste. Ribeirão Preto. 2006
- [2] Badin, A. Z. D., Casagrande, C., Roberts, T. III, Saltz, R., Moraes, L. M., Santiago, M., & Chiaratti, M. G. (2001). Minimally Invasive Facial Rejuvenation Endolaser Mid-Face Lift. *Aesthetic Plastic Surgery*, 25(6), 447–453. <https://doi.org/10.1007/S00266-001-0023-9>
- [3] BIONDO, Sonia. A Busca Da Beleza E Seus Riscos. *Revista Veja*, Edição Especial Nº 26, Ano 36, São Paulo, Setembro 2003.
- [4] Brito, RRR. A Concepção De Corpo E Autoimagem Feminina Na Pós Modernidade. Campos Dos Goytacazes, RJ: Universidade Estadual Do Norte Fluminense
- [5] Darcy Ribeiro –UENF, 2016.6. Miele, L. Harmonização Íntima Feminina. Rio Grande De Sul. Disponível Em: <https://www.clinicakore.com.br/tratamentos/ginecologia/harmonizacao-intima-feminina/>. Acesso Em: 28 De Jun.2021.
- [6] Dell’Avanzato R, Endolift: “The “Lunch-Time” Laser Lifting For The Lower Eyelids. *Data Da Publicação: 27 Dez 2022;29(2)*. Disponível Em: <https://www.lasertherapyjournal.com/ltj/article/view/307>.
- [7] Dell’Avanzato, R. (2022). Endolift® The “Lunch-Time” Laser Lifting For The Lower Eyelids. *Laser Therapy*, 29. <https://doi.org/10.4081/Ltj.2022.307.2>.
- [8] Nilforoushzadeh, M. A., Heidari-Kharaji, M., Fakhim, T., Hosseini, S. T., Rafiee, S., Shahverdi, M., & Najari Nobari, N. (2023). Efficacy Evaluation Of Endolift Laser For Treatment Of Nasolabial Folds Marionette Lines. *Skin Research And Technology*, 29(10), E13480. <https://doi.org/10.1111/Srt.13480>
- [9] Dias L, Almeida D, Petry CB, Souza MS, Souza DM. Laser De Diodo 1470nm: Uma Inovadora, Eficiente E Segura Técnica De Rejuvenescimento. *Aesthetic Orofacial Science*. 15 Jul 2023;05(02):48-58. Disponível Em: <https://ahof.emnuvens.com.br/ahof/article/view/167>. DOI: <https://doi.org/10.51670/Aos.V4i2.167>
- [10] Dornelles, R. F. V., Silva, A. L., Missel, J., & Centurión, P. (2013). Laserlipólise Com Diodo 980 Nm: Experiência Com 400 Casos. *Revista Brasileira De Cirurgia Plástica*, 28(1), 124–129. <https://www.rbcp.org.br/56>.
- [11] Wolfenson, M., Roncatti, C., Alencar, A. H., Barros, T., Silva Neto, J. F., & Santos Filho, F. C. N. (2011). Laserlipólise: Redução Da Pele E Prevenção De Umbigo Flácido Nas Lipoplastias Seguindo Parâmetros De Segurança No Uso Do Laser De Diodo – Com Duplo Comprimento De Onda 924 E 975 Nm. *Revista Brasileira De Cirurgia Plástica*, 26(2), 259–265.
- [12] Dorneles, APC. Mulheres Latinas Americanas E/Em Comunicação: Os Usos E Apropriações De Publicações De Cosméticos Nos Contextos De Brasil E México. 2020. Disponível Em: [http://www.repositorio.jesuita.org.br/bitstream/handle/UNISINOS/9314/Ana%20Paula%20Cardoso%20Dorneles\\_.pdf?sequence=1&isallowed=Y](http://www.repositorio.jesuita.org.br/bitstream/handle/UNISINOS/9314/Ana%20Paula%20Cardoso%20Dorneles_.pdf?sequence=1&isallowed=Y). Acesso Em 15 De Junho De 2021.
- [13] DUDELZAK, J., Hussain, M., & Goldberg, D. J. (2017). “Laser-Assisted Liposuction: An Update On Current Technology And Clinical Applications.” *Dermatologic Surgery*, 43(3), 317-326. DOI: 10.1097/DSS.0000000000000973.
- [14] DUNCAN, D. I. (2012). “Role Of The 1440-Nm Nd:YAG Wavelength In Laser-Assisted Liposuction: Clinical Evaluation And Review Of The Literature.” *Aesthetic Surgery Journal*, 32(1), 65-77. DOI: 10.1177/1090820X11441575.
- [15] Ferreira, GG, & Aguiñy, BG (2013). Movimentos Sociais De Sexualidade E Gênero: Análise Do Acesso Às Políticas Públicas. *Revista Katálysis*, 16(2), 223–232. <https://doi.org/10.1590/S1414-49802013000200008>
- [16] Goldman, M. P., & Gold, M. H. (2017). Advances In Laser Applications In Dermatology And Aesthetic Medicine. *Journal Of Clinical And Aesthetic Dermatology*, 10(5), 24-30.
- [17] Silva, MJ Da, Paiva, ACS, & Costa, IMM Da.(2017).A Vagina Pós-Orgânica: Intervenções E Saberes Sobre O Corpo Feminino Acerca Do “Embelezamento Íntimo”. *Horizontes Antropológicos*, 23,259–281. <https://doi.org/10.1590/S0104-71832017000100009>.
- [18] LEO ANNALISA DI. Soft Lifting Com Fibra Óptica Laser: Um Nuovo Approccio Nel Contouring Del Terzo Inferiore Del Volto. *Scuola Internazionale Di Medicina Estetica*. Roma. 22 Jan 2021. P. 13-32
- [19] LORDÉLO, P. Et Al. Radiofrequency In The Female Genital Laxity - A Pilot Study. *Revista Pesquisa Em Fisioterapia*, [S. L.], V. 4, N. 2, 2014. DOI: 10.17267/2238-2704rpf.V4i2.448. Disponível Em: <https://www5.bahiana.edu.br/index.php/fisioterapia/article/view/448>. Acesso Em: 2 Out. 2021.
- [20] LORDÉLO, Patrícia Et Al. Radiofrequency In Female External Genital Cosmetics And Sexual Function: A Randomized Clinical Trial. *International Urogynecology Journal*, V. 27, N.11, P. 1681-1687, 2016. Doi:10.1007/S00192-016-3020-X
- [21] Longo, L., Dell’Avanzato, R., & Longo, D. (2022). ENDOLIFT® And Multi-Wavelength Laser Photobiomodulation: A Randomized Controlled Trial Study On 96 Subjects, Treating Skin Laxity Of The Lower Third Of The Face. *Laser Therapy*, 29(2), 115–120. <https://doi.org/10.4081/Ltj.2022.298>.
- [22] Marysabel, Q, & Oscar, S. Efectividad De La Técnica Endoláser Con Plataforma Diodo 980 Nm En La Ritidosis Grado I Y II. *RILMED*, Volumen 3 Nº 1 – Marzo 2023.
- [23] MOYA, M., Valdés, C., & Arrazola, J. M. (2020). “The Role Of Laser Lipolysis In Body Contouring: A Systematic Review.” *Journal Of Cosmetic And Laser Therapy*, 22(6), 315-322. DOI: 10.1080/14764172.2020.1754783.
- [24] MELO, Ariadne Da Silva; SANTOS, Natálie Kristine Barros Dos. Autoimagem Genital De Pacientes Assistidas Pelo Setor De Fisioterapia Dermatofuncional De Uma Clínica Escola Em Maceió-Alagoas. 2019. 31 F. Trabalho De Conclusão De Curso (Bacharelado Em Fisioterapia) - Curso De Fisioterapia, Centro Universitário CESMAC, Maceió-AL, 2019.
- [25] Mordon, S. R., Wassmer, B., Reynaud, J. P., & Zemmouri, J. (2008). Mathematical Modeling Of Laser Lipolysis. *Biomedical Engineering Online*, 7, 10. <https://doi.org/10.1186/1475-925X-7-10>
- [26] Nilforoushzadeh, M. A., Fakhim, T., Heidari-Kharaji, M., Et Al. (2023). Efficacy Of Endolift Laser For Arm And Under Abdomen Fat Reduction. *Journal Of Cosmetic Dermatology*, 00, 1-5. <https://doi.org/10.1111/Jocd.15684.7>
- [27] Nilforoushzadeh, M. A., Fakhim, T., Heidari-Kharaji, M., Torkamaniha, E., Nouri, M., Roohaninasab, M., Behrangi, E., Hanifnia, A., & Goodarzi, A. (2022). Endolift Laser: An Effective Treatment Modality For Forehead Wrinkles And Frown Lines. *Journal Of Cosmetic Dermatology*, 21(6), 2463-2468. <https://doi.org/10.1111/Jocd.14884>
- [28] Nilforoushzadeh, M. A., Fakhim, T., Heidari-Kharaji, M., Hanifnia, A. R., Hejazi, S., &



- [29] Torkamaniha, E. (2021). Efficacy Evaluation Of Endolift-Based Subcision On Acne Scar Treatment. *Journal Of Cosmetic Dermatology*, 20(8), 2579–2582. <https://doi.org/10.1111/jocd.13876>.
- [30] Ruiz-Esparza, J. (2014). Minimally Invasive Body Contouring With Laser Lipolysis: A Review Of 1000 Cases. *Dermatologic Surgery*, 40(8), 876–881.
- [31] Roberto, M. (2020). Endolift Para O Melhor Lifting Não Cirúrgico De Rosto E Corpo. *Dermatologia E Cosmetologia*, Dubai, Emirados Árabes Unidos.
- [32] Sigova, D., Kaliterna, J., Abdelmaksoud, A., & Kamalska, M. (2023). Progressive Lipodystrophy: Topical Laser Treatment With Endolift® Procedure Using Eufoton® Lasemar®1500 1470-Nm Wavelength. *Journal Of Applied Laser Cosmetology*, 41(1), Ahead Of Print. <https://doi.org/10.56609/Jac.V41i1.66>
- [33] Silva, R. P., Et Al. (2022). Cadaveric Studies For Advancing Minimally Invasive Aesthetic Procedures: Preserving Anatomy And Ensuring Safety. *Aesthetic Plastic Surgery*, 46(2), 345–350.
- [34] Scrimali, L., & Lomeo, G. (2015). Endolaser Soft Lift: From Theory To Practice. *Aesthetic Medicine*, 1(1), 28–29.
- [35] Scrimali, L., Lomeo, G., Dell'Avanzato, R., & Crippa, A. (2013). Endolaser Soft-Lift: A New Approach On Body Contouring. Perspective And Suggestions. *European Journal Of Aesthetic Medicine And Dermatology*, 3(3), 86–90.
- [36] Trelles, M. A., Moreno-Moraga, J., & Alcolea, J. M. (2019). Safety And Efficacy Of Subcutaneous Laser-Assisted Lipolysis In Body Contouring. *Lasers In Medical Science*, 34(3), 615–623.
- [37] Kaluf R, Araujo GAZ, Martins DL, Campos LCB, Magalhães RC, Santos Júnior AJ. Tratamento Da Região Pubiana Na Abdominoplastia De Pacientes Após Grande Perda Ponderal. *Rev Bras Cir Plást.* 2008;23(4):302-4.
- [38] Alter GJ. Management Of The Mons Pubis And Labia Majora In The Massive Weight Loss Patient. *Aesthet Surg J.* 2009;29(5):432-42.
- [39] Nóbrega SS, Silva HLA. Rejuvenescimento Da Região Pudenda, Associada Ou Não À Dermolipectomia Abdominal. *Rev Bras Cir Plast.* 2009;24(3):351
- [40] ANDRE, FERNANDO SANFELICE, Bruna Jacobowski, And RAPHAEL S. SANFELICE ANDRÉ. "Lifting Of The Mons Pubis After Massive Weigth Loss." *Revista Brasileira De Cirurgia Plástica* 28 (2023): 627-632.
- [41] WOLFENSON, Moisés; DOS SANTOS FILHO, Fernando Cerqueira Norberto. Cervicofacial Laxity Reduction With Thermotherapy With Diode Laser ( $\lambda=975$ ). *Aesthetic Facial Surgery*, P. 597-610, 2021.
- [42] WOLFENSON, Moisés; HOCHMAN, Bernardo; FERREIRA, Lydia Massako. Laser Lipolysis: Skin Tightening In Lipoplasty Using A Diode Laser. *Plastic And Reconstructive Surgery*, V. 135, N. 5, P. 1369-1377, 2015.
- [43] Wolfenson, M., Ferreira, LM, Figueiredo, J., Alves, B. (2023). Lipólise A Laser: Reafirmação Da Pele Em Lipoplastia Utilizando Laser De Diodo Duplo HPL. In: Avelar, JM, Cavalcanti Ribeiro, R. (Eds) *Contorno Corporal*. Springer, Cham. [https://doi.org/10.1007/978-3-031-42802-9\\_33](https://doi.org/10.1007/978-3-031-42802-9_33)
- [44] SADOUGHIFAR, R. Et Al. Nonsurgical Eyelid Ptosis: Topical Treatment With Endolift® Direct Optical Energy. *Journal Of Applied Cosmetology*, V. 41, N. 1, P. 33/36-33/36, 2023.