

Prosthodontic Treatment Of A Patient With Combination Syndrome: A Clinical Case Report.

Authors

1.Dr.Vandana, 2.Dr. Vidisha, 3.Dr Apinder Singh, 4.Dr. Sukhvinder Singh noble, 5. Dr. Navyanshi

1. Dr. Vandana, PG Resident, Department of Prosthodontics ,ITS Dental college, Greater Noida, Uttar Pradesh

2. Dr. Vidisha, PG Resident, Department of Prosthodontics ,ITS Dental college, Greater Noida, Uttar Pradesh

3. Dr. Apinder Singh, PG Resident, Department of Prosthodontics, Maharaja Ganga Singh dental college and research centre, Shri Ganganagar, Rajasthan

4.Dr. Sukhvinder Singh Noble, PG Resident, Department of prosthodontics, Rishiraj college of dental science and research centre, Bhopal, Madhya Pradesh.

5.Dr. Navyanshi Jain , Tutor, Department of Oral surgery , Rishiraj College of Dental Sciences, Bhopal, Madhya Pradesh.

Corresponding Author

Dr. Vandana (PG Resident)

ITS Dental college , Greater Noida

Date of Submission: 01-09-2024

Date of Acceptance: 11-09-2024

I. Introduction:

Rehabilitating patients with a toothless upper jaw (edentulous maxilla) opposed by natural lower front teeth poses significant challenges for clinicians. This condition, known as Combination Syndrome (Kelly, 1972), is characterized by:

- Bone loss in the front upper jaw
- Overgrowth of the tuberosities
- Excessive tissue growth on the hard palate
- Over-eruption of lower front teeth
- Bone loss and ridge shrinkage under the posterior lower denture bases

Also referred to as Anterior Hyperfunction Syndrome, this condition requires careful consideration and expertise to manage its complex oral features and restore optimal oral function and aesthetics.

According to Tolstunov ², CS can be classified into the following

1. Class I. Maxilla: completely edentulous alveolar ridge. Mandible: Modification 1 (M1): partially edentulous ridge with preserved anterior teeth only. Modification 2 (M2): stable “fixed” full dentition (natural teeth or implant-supported crowns/bridges). Modification 3 (M3): partially edentulous ridge with preserved teeth in anterior and one posterior region.

2. Class II. Maxilla: partially edentulous alveolar ridge with teeth present in both posterior regions, edentulous and atrophic anterior region. Mandible: modifications are the same as in Class I (M1, M2, and M3).

3. Class III. Maxilla: partially edentulous alveolar ridge with teeth present in one posterior region only, edentulous and atrophic anterior and one posterior region. Mandible: modifications are consistent with Classes I and II (M1, M2, M3A, and M3B).

The present report details the prosthodontic management of a patient with a combination syndrome.

II. Case Report:

A 63-year-old female patient was referred to the department for restorative treatment. The patient's chief complaints were inadequate retention of maxillary complete denture and inability to chew comfortably. Clinically, the patient displayed flabby tissue of the maxillary ridge, overgrowth of the maxillary tuberosities, and over-erupting mandibular anterior teeth with spacing between mandibular central incisors (figure 1&2). The patient rejected any surgery and implant therapy due to financial considerations. The patient agreed to have a new complete denture and a mandibular removable partial denture.

III. Procedure:

1. Preliminary impression of the maxillary arch with impression compound and mandibular arch with irreversible hydrocolloid materials was made and poured with dental stone. (FIG 3&4)
2. A custom tray was fabricated for the maxillary arch impression using cold cure acrylic material.
3. Border molding of maxillary arch was done using green stick compound and final impression was obtained using zinc oxide eugenol impression paste after removing the wax spacer and making relief holes and was poured with dental stone. (FIG 5)
4. A custom tray was fabricated on the mandibular primary cast and border molding was done in conventional manner using green stick compound and functional impression (pickup impression) was obtained using irreversible hydrocolloid for dentulous area and zinc oxide eugenol impression paste for edentulous region simultaneously and was poured with dental stone. (FIG 6)
5. Record bases were fabricated over the master cast and jaw relation was recorded in the conventional manner. (FIG 7)
6. After the jaw relation, the maxillary and mandibular master casts were mounted in centric relation on the articulator.
7. Teeth arrangement was done followed by try in. (FIG 8)
8. After try in, the denture was fabricated in the conventional manner. (FIG 9)

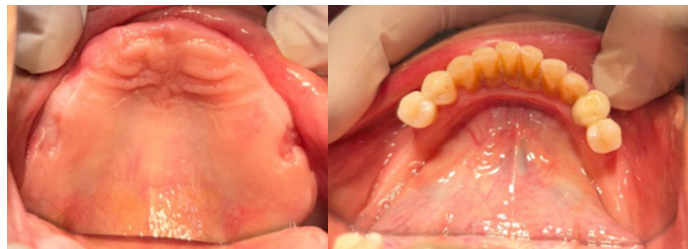

FIG 1- MAXILLARY ARCH

FIG 2- MANDIBULAR ARCH

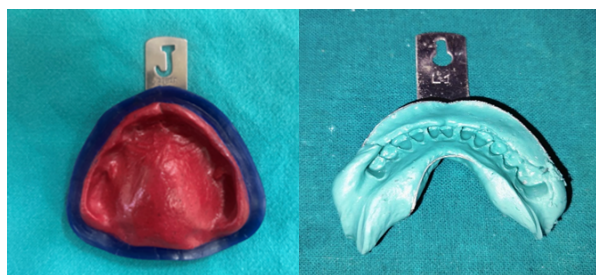


FIG 3- PRIMARY IMPRESSION OF MAXILLARY ARCH

FIG 4- PRIMARY IMPRESSION OF MANDIBULAR ARCH

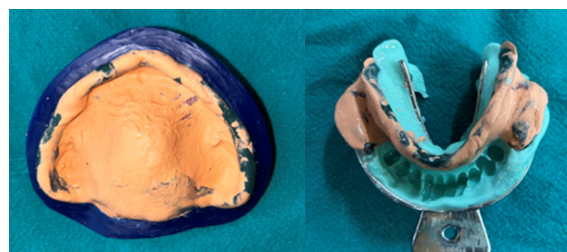

FIG 5- FINAL IMPRESSION

FIG 6-FINAL DUAL IMPRESSION

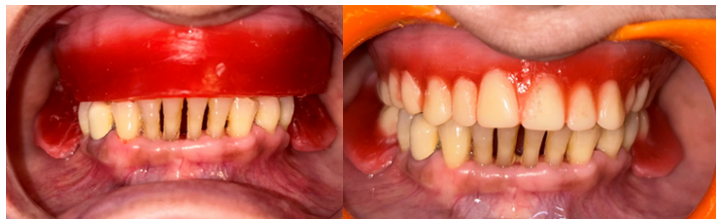

FIG 7- JAW RELATION RECORDED

FIG 8- TRY IN

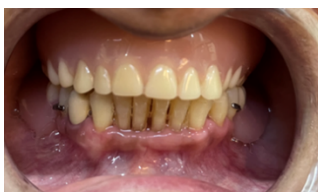

FIG 9- DENTURE DELIVERY

IV. Discussion :

Treatment of patients with an edentulous maxilla opposed to natural mandibular anterior teeth and a distal-extension RPD is considered a challenge for dental practitioners. Combination syndrome has a prevalence rate of approximately 24% for denture patients [3]. Therefore, it is necessary for dentists to understand the particular problems of patients and provide a comprehensive treatment plan. Increasing pressure on the premaxillary alveolar ridge and loss of adequate posterior occlusal contacts are important factors in relation to combination syndrome [4]. The bone loss in the midline of the maxilla observed by Kelly (1972) was 0.43 mm/year. López-Roldán et al (2009) [5] and Barber et al (1990) [6] reported similar results (0.32 mm/year and 0.36 mm/year, respectively) among patients wearing a maxillary complete denture and mandibular overdentures on two implants, a situation in which the prosthetics are biomechanically similar to Kelly's cases. Maximum support of the denture-bearing area, preservation of the mandibular posterior abutment, and balanced occlusion were all proposed to prevent bone loss and excess pressure on the anterior maxillary alveolar ridge. Similarly, Van Waas et al (1993) [7] suggested the avoidance of total tooth extraction, the preservation of a few teeth, and the use of overdentures. In the present case, the mucostatic impression technique with relief at the anterior maxillary flabby tissue was applied to accurately record the entire functional denture-bearing area (Figure 3,4). Meanwhile, a proper occlusal plane, the balancing of tooth contacts during excursive movements, the elimination of anterior contacts, and remounting techniques were used to gain better distribution of occlusal force and reduce stress on the anterior maxillary alveolar ridge. For further distribution of force, the maxillary denture was relined with soft lining material (Permasoft-acrylic based autopolymerized resilient lining material). Auto polymerized resilient liner materials allow the clinician to reline a removable denture directly, intraorally. To provide an adequate shock absorption effect, the optimum liner thickness of approximately 2-3mm is required [8]

V. Conclusion:

The clinician should carefully plan the management of such patients in order to preserve the health of the oral tissues and provide them with a functioning prosthesis that reduces the chance for the combination syndrome to occur. Hence, thorough diagnosis, proper treatment planning and accurate execution of that plan will result in an exceptional outcome.

References:

- [1] Glossary Of Prosthodontic Terms Terms (2005) J Prosthet Dent 94: 10-92.
- [2] Kelly E (1972) Changes Caused By A Mandibular Removable Partial Denture Opposing A Maxillary Complete Denture. J Prosthet Dent 27: 140-150.
- [3] Shen K, Gongloff Rk. Prevalence Of The 'Combination Syndrome 'Among Denture Patients. J Prosthet Dent 1989; 62: 642-4.
- [4] Jameson Ws. The Use Of Linear Occlusion To Treat A Patient With Combination Syndrome: A Clinical Report. J Prosthet Dent 2001; 85: 15-9
- [5] López-Roldán A, Abad Ds, Ber Tomeu Ig, Castillo Eg, Otaolaurruch Es. Bone Resorption Processes In Patients Wearing Overdentures. A 6-Years Retrospective Study. Med Oral Patol Oral Cir Bucal 2009; 14: 203-9.

- [6] Barber Hd, Scott Rf, Maxson Bb, Fonseca Rj. Evaluation Of Anterior Maxillary Alveolar Ridge Resorption When Opposed By The Transmandibular Implant. *J Oral Maxillofac Surg* 1990; 48: 1283-7
- [7] Van Waas Ma, Jonkman Re, Kalk W, Van't Hof Ma, Plooij J, Vanos Jh. Differences Two Years After Tooth Extraction In Mandibular Bone Reduction In Patients Treated With Immediate Overdentures Or With Immediate Complete Dentures. *J Dent Res* 1993; 72: 1001-4.
- [8] Kazanji Mnm & Watkinson Ac. 'Influence Of Thickness, Boxing And Storage On The Softness Of Resilient Denture Lining Materials'. *J Prosthet Dent* 1988, 59; 6: 677-80