

Morphology And Histology Of The Placenta In Sickle Cell Anaemia Pregnancies – A Case-Control Study

Dr Ujwala Bhanarkar

Assistant Professor, Department Of Anatomy, All India Institute Of Medical Sciences, Kalyani, West Bengal

Dr Sudhir V Pandit

Professor And Head, Department Of Anatomy, IGMC, Nagpur, Maharashtra

Dr Archana Rathod

Professor And Head, Department Of Gynecological Oncology, State Cancer Institute And Government Medical College, Aurangabad, Maharashtra

Abstract:

The placenta forms a functional unit between the mother and the fetus, and any pathological event concerning the mother or the fetus will influence the normal function of the placenta, resulting in morphological changes. There is a paucity of literature on the histopathology of the placenta in sickle cell anaemia during pregnancy. Hence, the present study was undertaken to analyze the spectrum of histopathological changes in the placenta in sickle cell anaemia during pregnancy. This prospective study on placenta from mothers with prior consent who delivered at a tertiary care centre for a period of 2 years was undertaken in the present study. 112 mothers willing to undergo the study were selected from the admission list and divided into two groups: (1) sickle cell anaemia group (n=56) and (2) control group (n=56) based on inclusion and exclusion criteria. The morphometric parameters, viz. placental weight, placental diameter, placental thickness, and umbilical cord length, were reduced in the placenta of the sickle cell disease group as compared to the control. Fetal loss was found in the sickle cell disease group. Histopathological examination of the placenta in sickle cell anaemia shows decreased villous vascularity, excessive syncytial knots, increased fibrinoid necrosis of the villi, increased villous stromal fibrosis, and increased endarteritis obliterans of the fetal stem vessels.

Date of Submission: 20-08-2024

Date of Acceptance: 30-08-2024

I. Introduction

The fetus, placenta, and mother form a triad that significantly influences pregnancy outcomes. Evaluating the placenta in instances of adverse pregnancy outcomes and maternal conditions offers crucial insights for both obstetricians and neonatologists (1). Sickle cell anaemia is a potentially dangerous haematological disorder that can occur during pregnancy, affecting many vital organs. It is linked to late abortions, prematurity, low birth weight, and stillbirths, collectively resulting in increased perinatal loss (2,3).

The placenta is a Latin word derived from the Greek word “PLAKOUS” meaning circular cake. The development of the placenta begins as soon as the blastocyst implants. A small group of cells opposed to its inner surface form the embryoblast. The trophoblastic cells of the implanting embryonic pole of the blastocyst proliferate to form a double-layered trophoblast. The outer of the two layers is transformed into a syncytiotrophoblast by the fusion of neighbouring trophoblastic cells and is covered with branching finger-like extensions that deeply invade the endometrium. The cells which have not yet achieved contact with the maternal tissues remain discrete and are called cytotrophoblast cells. The process of lacuna formation starts at the implantation pole and extends all over the blastocyst within a few days (4). The thicker trophoblast at the implantation pole is later transformed into the placenta. Trabeculae which keep their contact with the trophoblast shell are called anchoring villi, and the lacunar system is converted into the intervillous space.

Sickle cell anaemia is a genetic blood disorder that affects red blood cells and is caused by a mutation in the gene that produces haemoglobin. Macroscopic placental lesions seen in Sickle cell anaemia disease are calcification and infarction. Histologically, abnormal villous vascularity can be seen. The terminal villi of the mature placenta usually contain between 2 and 6 capillary vessels which are sinusoidally dilated. “villous hypervascularity” implies small non-dilated blood vessels, and hypervascularity implies an increased number of vascular channels (5).

Syncytial knots in more than 30% of the villi are considered excessive. Deficiency of vasculo-syncytial membranes is defined as <6% of villi showing vasculo-syncytial membranes (5). Homogeneous eosinophilic deposits called Fibrinoid necrosis of villi staining with Periodic acid Schiff are found at various sites in the placenta. An incidence of more than 3 per cent of the villi showing a marked increase in the stromal content of fibrous tissue is considered abnormal. Endarteritis Obliterans is a vascular lesion characterized by swelling and proliferation of the intimal cells of the fetal stem arteries with thickening and reduplication of the subendothelial basement membrane leading to surrounding or almost complete obliteration of the lumen (5).

II. Material And Methods

The sample size of the study comprised 80% of the average value of sickle cell anaemia cases in the last five years, and based on this sample size, the number of cases in the control group was decided. One hundred and twelve mothers who agreed to participate in the study were selected from the admission list or randomly. They were then divided into two groups: the anaemia group and the control group according to the inclusion and exclusion criteria. Written consent was taken from the mothers after explaining the study details, and the mother's proforma was maintained. The general shape of the placenta was evaluated. The fetal surface was inspected for colour and transparency, subchorionic thrombus, umbilical cord insertion, and the attachment of fetal membranes. The maternal surface of the placenta was inspected for completeness, adherent blood clots, calcification, and infarction. The thickness of the placenta was taken at the center (maximum thickness area) with a long knitting needle inserted in it. The placenta was then weighed without the cord and membranes and left for fixation in 10% formal saline for 24–48 hours. After fixation, the placenta was cut into vertical strips (bread loaf manner) of 0.5 cm thickness each, and the gross lesions were re-examined. A tissue block was prepared, and the slides were stained. One hundred terminal villi were counted in the maternal sub-division of each of the sections. Thus, in each placenta, four hundred villi were counted, and different histological features were quantified. The mean number of villi showing syncytial knots, vasculo-syncytial membranes, fibrinoid necrosis, and villous stromal fibrosis was also determined.

III. Results

This study involves a comparative analysis of 112 placentae divided into two equal groups: 56 (50%) placentae were from mothers with sickle cell anaemia (Hb < 7g/dl and sickle cell positive) who formed the anaemia group, and 56 (50%) placentae were from normal term mothers (Hb ≥ 11g/dl) who formed the control group. The mean and standard deviation were calculated for different parameters in both groups. The comparison of the means was done using the student's unpaired 't' test. The test of proportion was applied wherever necessary.

The product movement correlation (r) between the placental weight and birth weight in the normal group was 0.8914, whereas in the anaemia group, it was 0.7903. This indicates a high degree of correlation between the placental weight and the birth weight. Calcification was seen in 33/56 (58.92%) placentae of the control group and 7/56 (12.49%) placentae of the anaemia group, whereas infarction was seen in 2/56 (3.57%) placentae of the control group and 5/56 (8.92%) of the anaemia group (Table 1) (Figure 1).

Villous vascularity was decreased in 1/56 (1.78%) placentae of the control group and 24/56 (42.86%) of the anaemia group (Figure 2). Though increased villous vascularity was seen in 8/56 (14.28%) placentae of the control group and 4/56 (7.14%) of the anaemia group, the difference in the proportion of placentae showing increased villous vascularity between the two groups was statistically not significant ($p > 0.005$) (Figure 3). Increased syncytial knots were seen in 11/56 (19.64%) placentae of the control group and 26/56 (46.42%) placentae of the anaemia group. The difference in the proportion of placentae showing high villous syncytial knot counts (>30% of the villi) between the two groups was statistically significant ($p < 0.001$).

Increased fibrinoid necrosis of villi was seen in 7/56 (12.49%) placentae of the control group and 18/56 (32.14%) placentae of the anaemia group (Figure 4). The difference in proportion of placentae showing fibrinoid necrosis in >3 percent of the villi between the two groups was statistically very significant ($p < 0.001$). Villous stromal fibrosis was seen in 4/56 (7.14%) placentae of the control group and 16/56 (28.57%) placentae of the anaemia group. The difference in the proportion of placentae showing an increase in stromal fibrosis in >3 percent of the villi between the two groups was statistically very significant ($p < 0.001$) (Figure 5). Increased endarteritis obliterans of fetal stem vessels were seen in 3/56 (5.35%) placentae of the control group and 12/56 (21.42%) placentae of the anaemia group (Table 2) (Figure 6).

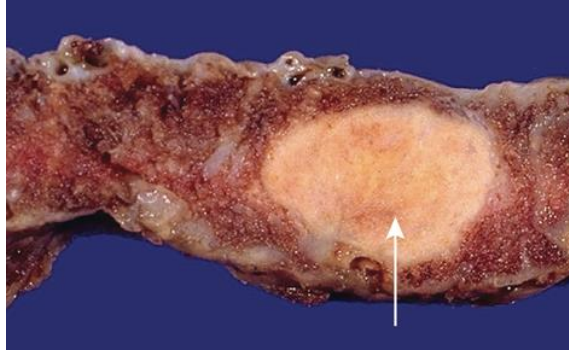


Figure 1: Cut section of placenta showing infarction (marked by arrow)

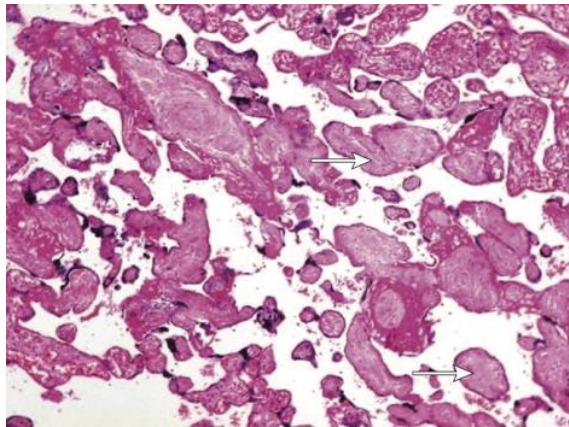


Figure 2: Photomicrograph of placenta showing hypovascular villi (marked by arrow)

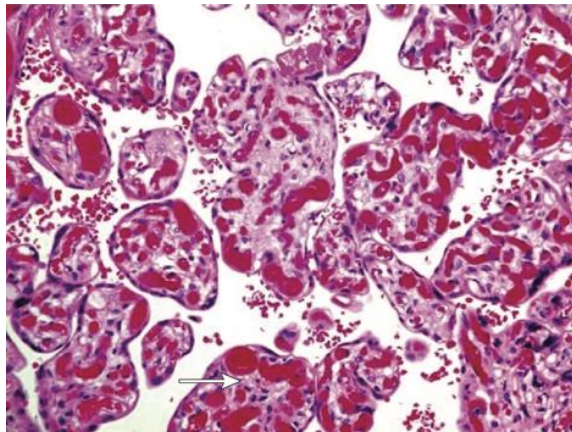


Figure 3: Photomicrograph of placenta showing hypervascular villi (marked by arrow)

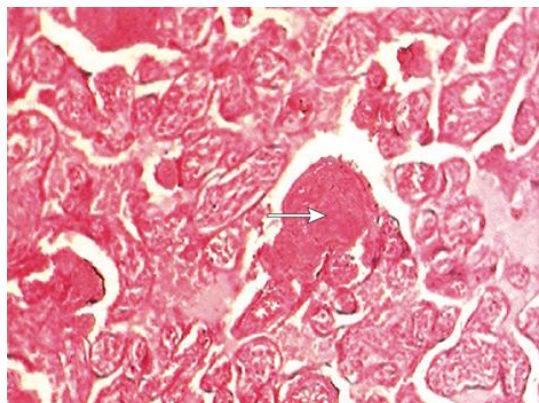


Figure 4: Photomicrograph of placenta showing fibrinoid necrosis (marked by arrow)

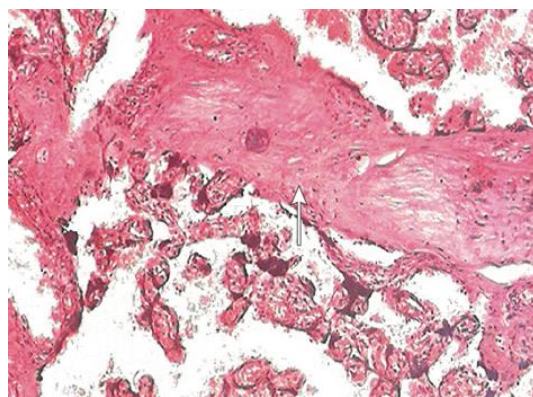


Figure 5: Photomicrograph of placenta showing intervillous fibrosis (marked by arrow)

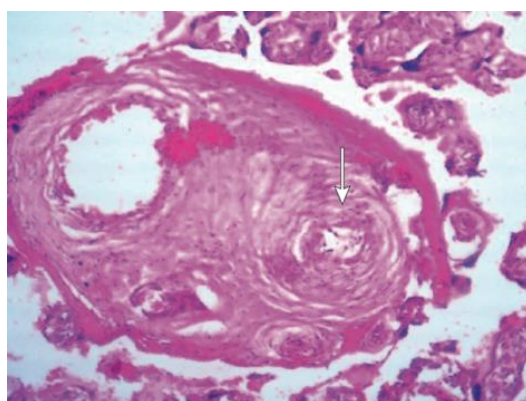


Figure 6: Photomicrograph of placenta showing endarteritis obliterans (marked by arrow)

Table 1: Incidence of calcification and infarction

Macroscopic Lesions	Control group (n=56)	Anaemia group (n=56)	z value	p value
Calcification				
Absent	33 (58.92%)	49 (87.5%)	3.414	<.0027
Present	23 (41.46%)	7 (12.49%)		
Infarction				
Absent	54 (96.42%)	51 (91.07%)	1.171	>0.05
Present	2 (3.57%)	5 (8.92%)		

Table 2: Histopathological findings

Microscopic Lesions	Control group (n=56)	Anaemia group (n=56)	z value	p value
Decreased villous vascularity	1 (1.78%)	24 (42.86%)	6.226	<0.0001
Increased villous vascularity	8 (14.28%)	4 (7.14%)	1.261	>0.05
Increased syncytial knots	11 (19.64%)	26 (46.42%)	3.245	<0.0012
Increased fibrinoid necrosis	7 (12.49%)	18 (32.14%)	2.587	<0.0097
Villous stromal fibrosis	4 (7.14%)	16 (28.57%)	3.081	<0.002
Endarteritis obliterans	3 (5.35%)	12 (21.42%)	2.874	<0.003

IV. Discussion

The placenta is a vital organ that supports the growth and development of the fetus by facilitating the exchange of nutrients, gases, and waste products between the maternal and fetal blood supplies. Any pathological event affecting either the mother or the fetus can have a significant impact on the function and morphology of the placenta. This study aimed to investigate the histopathological changes in the placenta associated with sickle cell anaemia during pregnancy. Sickle cell anaemia is a genetic disorder characterized by the presence of abnormal haemoglobin, known as haemoglobin S (HbS), in red blood cells. This condition can lead to various complications, including vaso-occlusive crises, chronic haemolysis, and anaemia. During pregnancy, women with sickle cell anaemia are at an increased risk of developing complications that can affect both maternal and fetal health (8).

In this study, the morphometric parameters of the placenta, including placental weight, diameter, thickness, and umbilical cord length, were found to be reduced in the sickle cell anaemia group compared to the control group. These findings were in correlation with the previous studies (9, 10). This finding suggests that

placental development may be compromised in pregnancies affected by sickle cell anaemia, potentially leading to adverse pregnancy outcomes (10).

Histopathological examination of the placenta revealed several significant differences between the sickle cell anaemia group and the control group. Decreased villous vascularity, increased syncytial knots, increased fibrinoid necrosis, increased villous stromal fibrosis, and increased endarteritis obliterans of fetal stem vessels were more frequently observed in the placentae of the sickle cell anaemia group (10). These findings which are in correlation with the present study indicate that sickle cell anaemia is associated with distinct histopathological changes in the placenta that may contribute to the increased risk of adverse pregnancy outcomes in affected women. The decreased villous vascularity observed in the sickle cell anaemia group suggests impaired blood flow within the placental villi, which can compromise the exchange of nutrients and gases between the maternal and fetal blood supplies. This impairment may contribute to fetal growth restriction and low birth weight, which are commonly observed in pregnancies affected by sickle cell anaemia.

Excessive syncytial knots, which are indicative of increased syncytiotrophoblast turnover, were also more frequently observed in the sickle cell anaemia group. Syncytial knots are formed as a result of increased syncytiotrophoblast proliferation and apoptosis, which can be triggered by hypoxia and other stressors. The presence of excessive syncytial knots may reflect the placental response to the chronic hypoxia and oxidative stress associated with sickle cell anaemia. Increased fibrinoid necrosis of the villi, characterized by the deposition of fibrin-like material within the villous stroma, was another notable finding in the sickle cell anaemia group. Fibrinoid necrosis is indicative of tissue damage and can disrupt the normal structure and function of the placenta. This pathological change may further compromise placental function and contribute to adverse pregnancy outcomes.

Villous stromal fibrosis, characterized by increased deposition of fibrous tissue within the villous stroma, was also more frequently observed in the sickle cell anaemia group. This finding suggests that chronic placental inflammation and tissue remodelling are more pronounced in pregnancies affected by sickle cell anaemia. Villous stromal fibrosis can impair the exchange of nutrients and gases between the maternal and fetal blood supplies, potentially leading to fetal growth restriction and other complications. Endarteritis obliterans, a vascular lesion characterized by intimal proliferation and luminal obliteration of fetal stem vessels, was another significant finding in the sickle cell anaemia group. This lesion can reduce blood flow within the placenta and contribute to fetal hypoxia and growth restriction. The increased incidence of endarteritis obliterans in the sickle cell anaemia group highlights the impact of this haematological disorder on placental vasculature and function.

V. Conclusion

In conclusion, this study demonstrates that sickle cell anaemia is associated with distinct histopathological changes in the placenta, including decreased villous vascularity, increased syncytial knots, increased fibrinoid necrosis, increased villous stromal fibrosis, and increased endarteritis obliterans of fetal stem vessels. These changes may contribute to the increased risk of adverse pregnancy outcomes, such as fetal growth restriction, low birth weight, and stillbirths, in women with sickle cell anaemia. Further research is needed to elucidate the underlying mechanisms of these placental changes and to develop targeted interventions to improve pregnancy outcomes in affected women.

Acknowledgement - We sincerely acknowledge all the patients who contributed to the study without whom the study could not be possible.

Declaration of Interest - The authors declare that there is no conflict of interest in this study.

References

- [1] Langston C, Kaplan C, Macpherson T, Mancini E, Peevy K, Clark B. Practice Guideline For Examination Of The Placenta. Arch Pathol Lab Med 1997; 121:449-472.
- [2] Klebanoff Ma, Shiono Ph, Selby Ju, Trachtenberg Ai, Gaubard Bi. Anemia And Spontaneous Preterm Birth. Am J Obstet Gynaecol 1991; 164: 59-63.
- [3] Lieberman E, Ryan KJ, Monson Rr. Association Of Maternal Hematocrit With Premature Labour. Am J Obstet. Gynaecol. 1988; 159:107.
- [4] Collins P. Embryology And Development. In: Bannister Lh, Berry Mm, Collins P, Dyson M, Dussek Je, Ferguson Mwj Eds. Grays Anatomy. London: Churchill Livingstone; 1995. 166-173.
- [5] Fox H. Pathology Of Placenta. 2nd Edn Philadelphia: W.B. Saunders Co.Ltd; 1997.
- [6] Shah D.Guidelines For Antenatal Monitoring Of The Fetus.J Obstet Gynec India1998; 48(6).79
- [7] Geoffrey Tsaras, Amma Owusu-Ansah, Freda Owusu Boateng, Yaw Amoateng-Adjepong, Complications Associated With Sickle Cell Trait: A Brief Narrative Review,
- [8] The American Journal Of Medicine, Volume 122, Issue 6,2009, Pages 507-512 Doi: 10.1016/J.AmJmed.2008.12.020.
- [9] Shegekar T, Pajai S. A Comprehensive Review Of Pregnancy In Sickle Cell Disease. Cureus. 2023;15. 10.7759/Cureus.41165.
- [10] Kurrey P, Kumar A, Yogesh As, Shukla Ck. Association Of Sickle Cell Anaemia In Morphology Of Full Term Placenta In Chhattisgarh Region. Biomedical Research. 2012;23(1):43-46
- [11] Rathod K, Jaiswal K, Shrivastava A, Shrikhande A. Study Of Placenta In Sickle Cell Disorders. Ind J Pathol Microbiol. 2007;50. 698-701.