

The Pyramid Lift[®] Injection Technique With BAT

Sergio Noviello Md, Faacs, Fwacs

Andrea Maroni Md

Massimiliano Tocchio Md

Carlo Chirilli Md

Tiziano Mirabello Md

Gualtiero Cogliandro Md

Sergio Noviello Academy - Milan - Italy

Abstract

Introduction

Facial tissue augmentation procedures with hyaluronic acid dermal fillers have become increasingly popular worldwide. The goal of these treatments is to create oval shape and smooth surface, restoring volume and brighten a natural appearance. Various techniques for tissue augmentation have been utilized and described.

Methods

With the Pyramid Lift[®] injection technique with BAT, we suggest to prefer contouring and projection instead of volumising. The filler is administered with an innovative column technique through each entry point.

Results

Between March 2023 and May 2024, 110 female patients underwent a nonsurgical facial tissue augmentation procedure with injectable fillers using this technique. 99 patients (90%) reported that they were satisfied or extremely satisfied with their procedure. No serious complications were observed.

Conclusion

The advantages of the Pyramid Lift[®] injection technique with BAT are enhancing the projection and contour of selected facial areas improving shadows and lights, reducing the risk of complications like swelling, bruising and vascular injuries.

Keywords: hyaluronic acid, filler technique, projection.

Date of Submission: 05-08-2024

Date of Acceptance: 15-08-2024

I. Introduction

Facial tissue augmentation with hyaluronic acid dermal fillers is a minimally invasive procedure that has become increasingly popular in recent years (1). Tissues like skin, fat, muscles become thinner with age due to a decrease in collagen and elastin (1). Bones resorption plays also a role of paramount importance. In elderly patients, filler injection aims to provide rejuvenating support to the upper, mid and lower third of the face. However, the procedure is usually performed even in younger patients to improve harmony and balance, emphasizing projection and contour, brightening a natural appearance (2). Moreover hyaluronic acid fillers can also be used in the treatment of postoperative, accidental, and post-inflammatory scars or of asymmetric shape (3). Herein, we describe the Pyramid Lift[®] technique with Bloodless Atraumatic Technique (BAT) for tissue augmentation with hyaluronic acid performed in cosmetic medicine in outpatient settings.

II. Methods

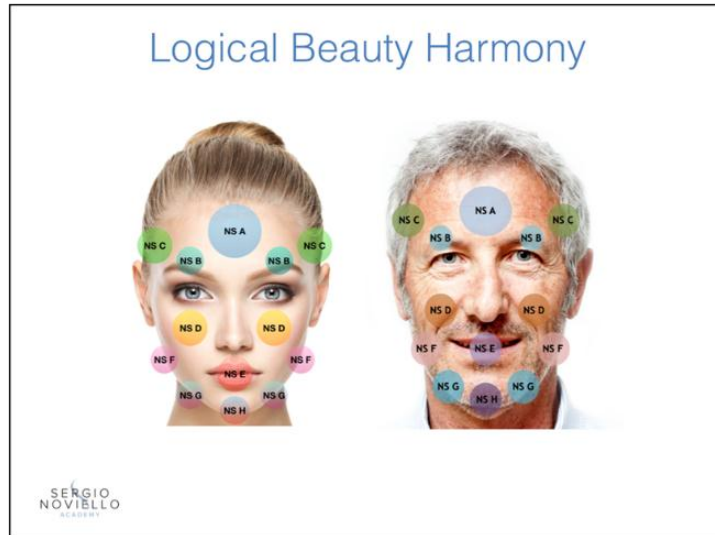
A topical antimicrobial agent (Germoxid) containing Chlorhexidine was used to disinfect the skin. Germoxid is a ready-to-use skin disinfectant, with long-term bactericidal action. Chlorhexidine shows proven broad-spectrum activity against Gram Positive and Gram-Negative bacteria. The molecular structure of Chlorhexidine has a high affinity with epidermis proteins which leads to rapid and persistent absorption at the skin level.

Germoxid allows you to quickly and effectively disinfect the skin in general without wasting time; just spray it directly on the part to be treated; does not irritate, burn or stain. The product is safe for operators: Chlorhexidine has maximum compatibility with the epidermis.

Between March 2023 and May 2024, 110 female patients underwent a nonsurgical facial tissue augmentation procedure with injectable fillers using this technique.

The injections were always preceded by a thorough assessment of the patients, through the Logical Beauty Harmony strategy (4).

Figure 1 - Logical Beauty Harmony and Natural Shape Zones.



LBH is a proven system for the use of fillers in aesthetic medicine based on the so-called Natural Shape zones (NS). The NS zones are made up of strategic areas of sequential injection that allow you to recreate, improve or restore projections, contours, lights and shadows of the face, guaranteeing natural results and expressiveness. This protocol is adaptable to different ages, genders and targets.

Starting from recent acquisitions of clinical anatomy, pathophysiology of aging, rheology of products (5) and observing the characteristics of harmony of each individual we have developed an approach that uses injectables in a targeted way using support and lifting vectors at the level of the upper, middle third and lower face, first injecting deeply and then moving to the surface through a multilayer strategy.


This system allows us to avoid an unnatural result of the face and to optimize the patient's characteristics in an effective, simple and individual way: reshaping the forehead, the eyebrow and the temporal area; redefine the natural projection of the cheek; reshape the chin, angle and jaw line; improve the harmony of the lips.

Through the Pyramid Lift® □ injection technique with BAT fillers are administered with an innovative column technique through each entry point.

The system was born from the observation that when using fillers we cannot consider the injections a real restoration of the volumes of the face. If we compare what happens in facial lipofilling procedures where we usually inject intervals between 15 ml and 30 ml of adipose tissue, it is clearly evident that the use of 2 ml or 3 ml of hyaluronic acid cannot be considered a volumetric restoration.

From this consideration the need to prefer the restoration of the contours of the facial profiles and the increases in the projection of specific areas of the face, placing the idea of restoring the tissue volumes in the background. In this direction, the idea of opting for technical solutions that allow the lights and shadows of the face to be enhanced to emphasize beauty and harmony.

Figure 2 - Lights and shadows emphasize beauty and harmony.



In the world of beauty, shadows and light dance together like two artists on a stage, creating a living work of art: the human face. Every line, every curve, every shade of skin tells a story, and the way light and shadow interact on it can transform an ordinary face into an extraordinary masterpiece.

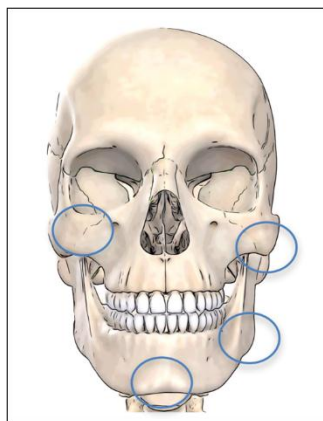
Imagine a face illuminated by the light of sunset, gently gliding over cheeks and lips, accentuating their shape and colour. The warm light envelops every detail, making the eyes shine like precious gems. Shadows, on the other hand, add depth and mystery. A light shadow under the cheekbones not only defines the contour of the face, but also evokes a sense of elegance and refinement. It is in this play of light and shadow that the true essence of beauty is revealed.

The shadows may also reveal imperfections: it is precisely in those imperfections that the uniqueness of each face lies. Every wrinkle tells a laugh, every scar a story of resilience. Light, on the other hand, is an embrace that celebrates these characteristics, enhancing the authentic beauty of who we are.

In a photoshoot, an experienced make-up artist knows exactly how to use bright and dark to enhance the beauty of a face. With a strategic touch of illuminant and a skilful play of shadows, a face can look radiant and magnetic, capable of capturing the attention and hearts of viewers.

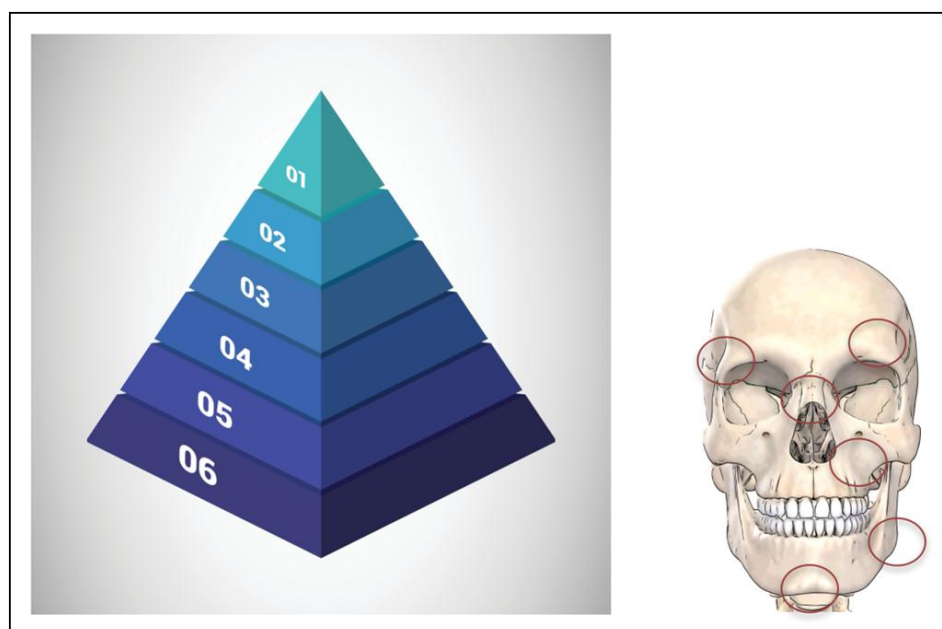
In conclusion, shadows and lights are not just visual elements; they are tools that, when used skilfully, can reveal the intrinsic beauty of any individual.

Figure 3 - Bony projections



Furthermore, the careful analysis of the bony projections of the skeleton such as the pogonion of the chin, the angle of the jaw, the projection of the cheekbone, the orbital rim at the level of the temporal crest, with an acute and non-rounded appearance, suggests the use of fillers at a deep level with deposition of material with a pyramidal appearance (hence the name of the Pyramid Lift® □ strategy) instead of the classic bolus injection.

Figure 4 - Pyramid Lift Injection Technique



This alternative injection method is permitted by the wide range of fillers on the market, with different rheological characteristics, in order to offer the necessary elasticity for such performances.

The rheological characteristics of injectable materials based on hyaluronic acid deserve a brief mention.

Each type of hyaluronic acid filler has a different concentration of HA and is developed using many different cross-linking methods (6).

Understanding the rheologic properties of fillers can help injectors to identify the correct product for each region or indication. Hyaluronic acid fillers placed superficially in the skin to enhance fine wrinkles will require different characteristics than one placed at a deeper level to create support and projection. Every region of the face is subjected to different deformation from overlying tissues: skin, muscle, and fat. These distortion cause the filler to deform in different ways.

Viscoelasticity is a characteristic of a filler that shows both viscous and elastic behavior when shear deformation affects its shape. Viscous materials keep distorting as long as shear deformation is maintained but do not recover after the stress (e.g., honey).

Elastic substances distort under shear deformation and recover when the stress is removed (e.g. rubber).

Viscosity and elasticity are of paramount importance for fillers because they undergo to different types of shear force during and after the injection. During fillers injection when the filler is extruded from the needle, the filler behaves almost like a viscous material. However, once released into facial tissue, the filler exhibits elastic behavior as it can almost recover its original shape.

There are 4 parameters used to describe these properties: G^* (measures hardness), G' (measures elasticity), G'' (measures viscosity), and $\tan \delta$ (measures the ratio between viscosity and elasticity).

Tab. 1 - Parameters used to describe rheologic properties

G^* = HARDNESS
G' = ELASTICITY
G'' = VISCOSITY
$TAN \delta = G''/G'$

G^* , is the energy required to distort filler using shear deformation. This term is referred to hardness, or rather how complex it is to change filler's shape.

G' , is the energy fraction of G^* acquired by the filler during stress and applied to recover the previous shape. G' measures how much it can recover its shape after shear distortion.

G'' , represents the energy fraction of G^* lost on deformation. G'' reflects the inability of the gel to recover its shape after the distortion is removed.

$Tan \delta$ is a measure of the ratio of viscous to elastic components, defined as $\tan \delta = G''/G'$. $Tan \delta$ determines whether the material is mainly elastic ($\tan \delta < 1$), exhibiting a gel-like behavior, or whether it is mainly viscous ($\tan \delta > 1$), exhibiting a honey-like behavior.

Fillers must be viscoelastic. A filler completely elastic would be very difficult to inject through a needle. A filler completely viscous would deform on distortion and would not preserve its shape for a notable amount of time. When water, a substance with no elasticity and very low viscosity, is infiltrated in the subcutaneous tissue the result is temporary due to the failure of elasticity.

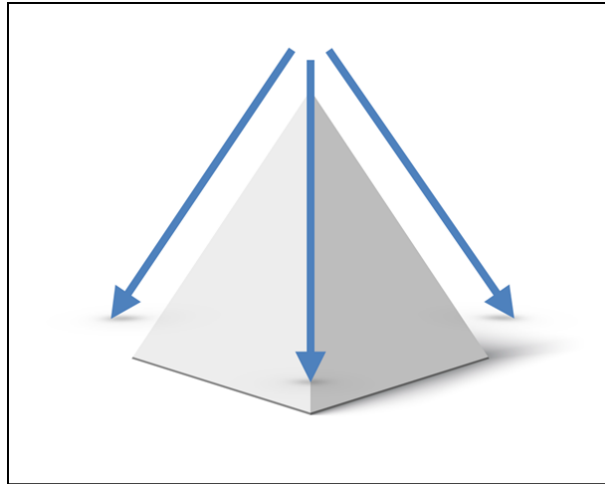
The productive process determines the viscoelastic characteristics of fillers. Gel hardness and G' are proportional to the level of cross-linking. G' values of fillers usually range from 1 to 1000 Pa (Pascal). Adding sterile saline to a filler reduces its hyaluronic acid concentration and decreases G^* , G' , and G'' .

The injectable will present lower viscosity and lower elasticity, resulting softer, but it will at the same time last less.

The Pyramid Lift® □ injection technique

The Pyramid Lift® □ technique consists of a needle injection of hyaluronic acid-based filler, which differs from the bolus method in that the deposition of material does not occur exclusively in a single point but by directing the needle in four directions along the sides of a hypothetical pyramid whose vertex represents the entry point. Most of the hyaluronic acid is deposited on the periosteal plane. But the technique involves the release through each entry point, retrogradely, of a further fraction of material in column or towering mode right along the sides of the pyramid itself. The elasticity of the products used, to varying degrees, allows for an increase in the projection of the facial tissues in the specific injection areas.

Figure 5 - Pyramid Lift Injection Technique with deposition of material directing the needle in four directions along the sides of a hypothetical pyramid.



Small releases of 0.1 to 0.4 ml were made at the injection area.

Filler injections of hyaluronic acid were made preferably using very small needles, 27-gauge to 33-gauge if possible, in order to fulfill the requirements of the Bloodless Atraumatic Technique (BAT) (7). The BAT allows to enhance facial harmony with control and precision without violating important and sensitive anatomical structure like mucosa, vessels, muscles which reduces pain, postoperative discomfort, swelling, bruising, long lasting edema and the possibility of infection. The BAT is a sequential method based on patient's aesthetic need that can reduce infiltration errors and can yield predictable and reliable results. Bloodless Atraumatic Technique injection offers objective improvements in side effects and complications, recovery and the overall patient experience, but do not happen in a predictable manner without substantial commitment of the medical staff and effort primarily of the aesthetic physician.

The use of Bloodless Atraumatic Technique significantly decreased the pain level and discomfort in our practice. Our experience adds to the mounting evidence that physicians and surgeons should consider using the BAT and reduce classical technique. Offering this redelineated level of patient journey needs that injectors study all the entire method and strictly follow the processes and techniques.

Afterwards, a gentle massage of the injected areas was performed in order to maintain projection and contour. Patient satisfaction was evaluated with a four-point scale: disappointed, neutral, satisfied, extremely satisfied (4). The patients were advised to avoid hot showers, saunas and heavy exercise for the first 24 hours after filler injection. Touch-up treatment was administered one week after the initial treatment if required.

III. Results

Between March 2023 and May 2024, 110 female patients underwent a nonsurgical facial tissue augmentation procedure with injectable fillers using the Pyramid Lift® □ technique with BAT described above.


Patients' medical records were reviewed retrospectively. The mean age was 38.1 years, with a range of 25 to 56 years. The patients had not been treated with hyaluronic acid in the prior 12 months. The exclusion criteria were having an autoimmune disease, allergy to hyaluronic acid, and current treatment with anticoagulants.

A total volume of approximately 0.4 to 3.0 ml hyaluronic acid filler was injected where needed, following the strategy of the Logical beauty Harmony, at the level of the pogonion of the chin, the angle of the jaw, the cheekbone, the orbital rim (temporal crest), with a pyramidal appearance instead of the classic bolus injection.

Figure 6 - Projection and Contour with Pyramid Lift Injection Technique - Immediate post treatment.

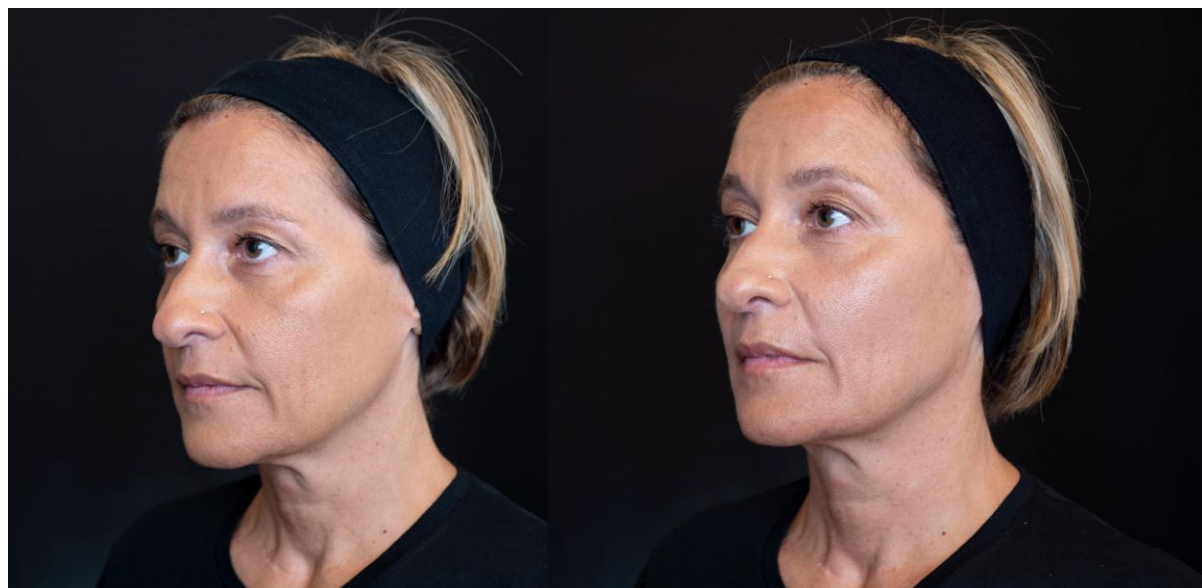

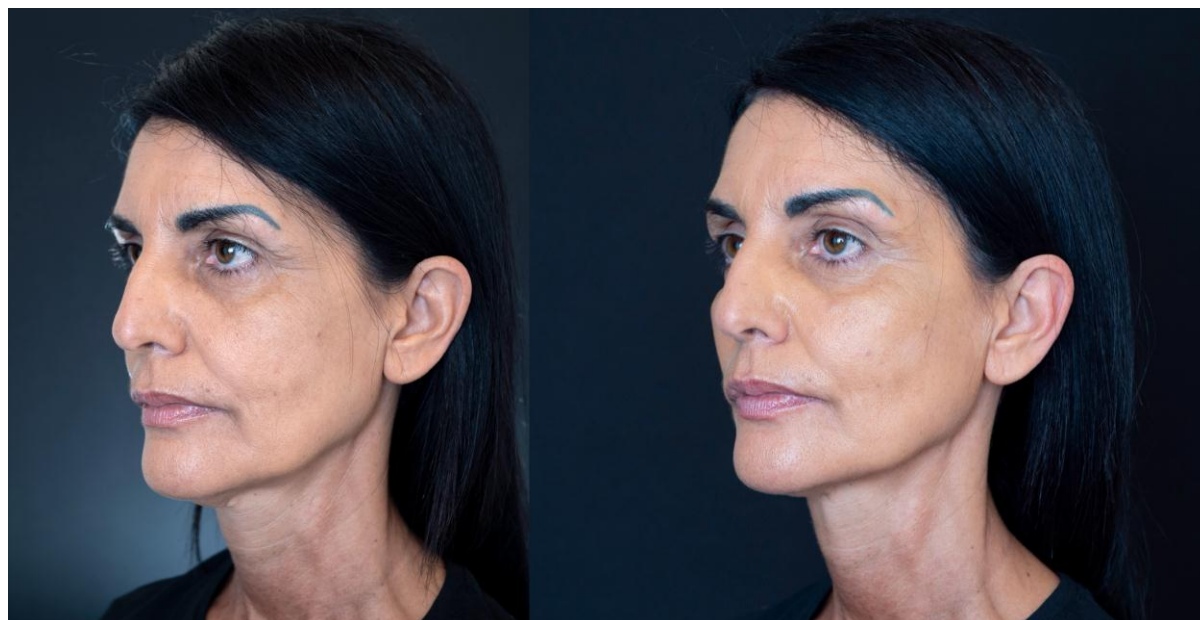Figure 7 - Projection and Contour with Pyramid Lift Injection Technique - Immediate post treatment.



The results were evaluated immediately after the procedure and one week later. A total volume of 0.3 to 1.2 ml of hyaluronic acid was administered to 33 patients (30%) to correct projection two weeks after the initial injection. Hundred-five patients (95%) reported that they were satisfied or extremely satisfied with their contour procedure. Six patients (7%) did not expressed any comments and three patients (2%) reported being disappointed with the results. The latter two had unrealistic expectations and were not completely pleased with the appearance of their face.

Very minimal pain if not and just a small amount of redness were observed at the needle entry points in a few cases. However no bleeding, bruising swelling or serious complications like infection, discoloration, lumps, necrosis or foreign body granuloma reaction occurred.

Figure 8 - Projection and Contour with Pyramid Lift Injection Technique - Immediate post treatment.



IV. Discussion

Facial tissue augmentation procedures with hyaluronic acid dermal fillers has become increasingly popular worldwide (8). The goal of these treatments is to create oval shape and smooth surface, restoring volume and brighten natural appearance. Various techniques for tissue augmentation have been utilized and described. There is no single way to achieve the intended results. However, anatomical knowledge and the use of appropriate products and techniques are essential for a natural appearance (9).

Hyaluronic acid fillers are the most commonly used products for facial tissue antiageing purposes and enhancement of harmony and various injection techniques have been described. The depth of the injection plays always a crucial role in achieving optimal cosmetic outcomes (10). Kane et al. compared the injection of hyaluronic acid into the mid-face using needle and microcannula injection techniques. They indicated that using a needle provides a more reliable administration of hyaluronic acid deep to the supraperiosteal zone (11). The injection type options include linear threading, fanning, cross-hatching, serial puncture and bolus (12).

Bolus injection, particularly employing the Pyramid Lift® □ technique with needle and fanning technique with cannula are the preferred techniques for improving projection and contour. The bolus infiltration technique uses injections above all on the supraperiosteal plane in the deepest layers, whereas the fanning technique with cannula uses the administration of filler into the subcutaneous plane. Multilayer techniques exploit precisely this double injection plane.

Furthermore, superficial fanning, linear threading or cross-hatching injections with needles can attenuate shadows and wrinkles or enhance lights in certain areas of the face.

Facial changes may be efficiently and effectively compensated for with HA filler injections. Depending on each specific patient's anatomy, volume loss, degree of bone resorption, and ptosis of fat compartments, both supraperiosteal and subcutaneous injections may be performed and combined to reshape and contour upper, mid and lower thirds.

Although young patients with limited deficit can usually be improved with injections limited to the deep fat compartments, older patients with significant defects need double plane injection treatment to optimize outcomes.

The Tri-Site Bolus technique proposed by Carey (13) was adapted by several doctors in order to achieve a similar effect, that is, create deep pillars supporting the superficial structures.

Shamban described a close technique for the midface employing 2 three-point rows of supra-periosteal depot injections of 0.1 to 0.2 mL, found within a treatment area delineated by 2 lines (14).

We had previously administered single multiple injections of hyaluronic acid fillers with a needle. Then we began using a technique that requires a cannula, and we also performed multiple punctures with a needle. Most recently, we used the Pyramid Lift® □ injection technique with BAT detailed above. To the best of our knowledge, Pyramid Lift® □ injection technique has not been described previously.

In this technique, the needle injection of hyaluronic acid-based filler, differs from the bolus method in that the deposition of material does not occur exclusively in a single point but by directing the needle in four directions along the sides of a hypothetical pyramid. The technique involves the release through each entry point, retrogradely, of a further fraction of material supraperiosteal in column mode right along the sides of the pyramid itself. Moreover, as stated previously, hyaluronic acid fillers should be carefully identified based on rheologic characteristics to guarantee a natural look as well as optimal treatment outcomes, i.e. injectables with the necessary elasticity.

Acknowledgements

The authors would like to thank the whole team of the BAT center in Milan, the entire surgical team of the Universo Salute - Vista Vision Clinical Center and all the professionals of the Sergio Noviello Academy. Special thanks to Boro Maletic for his trust.

Conflicts of interest

The authors declare that there are no conflicts of interest.

Bibliography

- [1]. De La Guardia C, Virno A, Musumeci M, Bernardin A, Silberberg Mb. Rheologic And Physicochemical Characteristics Of Hyaluronic Acid Fillers: Overview And Relationship To Product Performance. *Facial Plast Surg.* 2022 Apr;38(2):116-123. Doi: 10.1055/S-0041-1741560. Epub 2022 Feb 3. Pmid: 35114708; Pmcid: Pmc9188840.
- [2]. Braz A, Eduardo Ccp. Reshaping The Lower Face Using Injectable Fillers. *Indian J Plast Surg.* 2020 Aug;53(2):207-218. Doi: 10.1055/S-0040-1716185. Epub 2020 Aug 29. Pmid: 32884187; Pmcid: Pmc7458843.
- [3]. Manzoni Apd, Venier Nab. Hyaluronic Acid Filler Correction Of Scars And Asymmetries Secondary To Cleft Lip Repair. *Dermatol Surg.* 2022 Nov 1;48(11):1264-1266. Doi: 10.1097/Dss.0000000000003615. Erratum In: *Dermatol Surg.* 2023 Mar 01;49(3):316. Doi: 10.1097/Dss.0000000000003740. Pmid: 36342260.
- [4]. Noviello S, Gritzalas K, Maroni A, Tocchio M, Cogliandro G, Di Benedetto N. Logical Beauty Harmony And Natural Shape Zones (Nsz). *International Journal Of Case Reports (Issn:2572-8776)* 2020. Ijcr: <https://Escipub.Com/International-Journal-Of-Case-Reports/>
- [5]. Trévidic P, Kaufman-Janette J, Weinkle S, Wu R, Dhillon B, Antunes S, Macé E, Maffert P. Injection Guidelines For Treating Midface Volume Deficiency With Hyaluronic Acid Fillers: The Atp Approach (Anatomy, Techniques, Products). *Aesthet Surg J.* 2022 Aug 1;42(8):920-934. Doi: 10.1093/Asj/Sjac007. Pmid: 35039828; Pmcid: Pmc9373948.
- [6]. Fagien S, Bertucci V, Von Grote E, Mashburn Jh. Rheologic And Physicochemical Properties Used To Differentiate Injectable Hyaluronic Acid Filler Products. *Plast Reconstr Surg.* 2019 Apr;143(4):707e-720e. Doi: 10.1097/Prs.0000000000005429. Pmid: 30921116; Pmcid: Pmc7597953.
- [7]. Noviello S., De Santis A., Tocchio M. Face-Lift With Bloodless Atraumatic Technique (Bat). Reducing Downtime, Side-Effects And Complications. *Plast Surg Mod Tech.* 2016;1
- [8]. Wongprasert P, Dreiss Ca, Murray G. Evaluating Hyaluronic Acid Dermal Fillers: A Critique Of Current Characterization Methods. *Dermatol Ther.* 2022 Jun;35(6):E15453. Doi: 10.1111/Dth.15453. Epub 2022 Apr 5. Pmid: 35293660; Pmcid: Pmc9285697.
- [9]. Corduff N, Juniarti L, Lim Ts, Lin F, Mariwalla K, Pavicic T, Quiambao A, Siew Tw, Suwanchinda A, Tseng Fw, Vachiramon V, Youn Cs, Ho Wws. Current Practices In Hyaluronic Acid Dermal Filler Treatment In Asia Pacific And Practical Approaches To Achieving Safe And Natural-Looking Results. *Clin Cosmet Investig Dermatol.* 2022 Jul 1;15:1213-1223. Doi: 10.2147/Ccid.S363583. Pmid: 35800454; Pmcid: Pmc9255720.
- [10]. Micheels P, Besse S, Sarazin D, Vincent Ag, Portnova N, Diana Ms. Quantifying Depth Of Injection Of Hyaluronic Acid In The Dermis: Data From Clinical, Laboratory, And Ultrasound Settings. *J Drugs Dermatol.* 2016 Apr;15(4):483-90. Pmid: 27050704.
- [11]. Glogau Rg, Kane Ma. Effect Of Injection Techniques On The Rate Of Local Adverse Events In Patients Implanted With Nonanimal Hyaluronic Acid Gel Dermal Fillers. *Dermatol Surg.* 2008 Jun;34 Suppl 1:S105-9. Doi: 10.1111/J.1524-4725.2008.34251.X. Pmid: 18547173.
- [12]. Sundaram H, Liew S, Signorini M, Vieira Braz A, Fagien S, Swift A, De Boule Kl, Raspaldo H, Trindade De Almeida Ar, Monheit G; Global Aesthetics Consensus Group. Global Aesthetics Consensus: Hyaluronic Acid Fillers And Botulinum Toxin Type A-Recommendations For Combined Treatment And Optimizing Outcomes In Diverse Patient Populations. *Plast Reconstr Surg.* 2016 May;137(5):1410-1423. Doi: 10.1097/Prs.0000000000002119. Pmid: 27119917; Pmcid: Pmc5242215.
- [13]. Sundaram H, Shamban A, Schlessinger J, Kaufman-Janette J, Joseph Jh, Lupin M, Draelos Z, Carey W, Smith S, Eaton L. Efficacy And Safety Of A New Resilient Hyaluronic Acid Filler In The Correction Of Moderate-To-Severe Dynamic Perioral Rhytides: A 52-Week Prospective, Multicenter, Controlled, Randomized, Evaluator-Blinded Study. *Dermatol Surg.* 2022 Jan 1;48(1):87-93. Doi: 10.1097/Dss.0000000000003238. Pmid: 34608092; Pmcid: Pmc8667798.
- [14]. Shamban A. Customized Approach To Facial Enhancement. *Facial Plast Surg Clin North Am.* 2015 Nov;23(4):471-7. Doi: 10.1016/J.Fsc.2015.07.008. Pmid: 26505543.