

Decoding Time: Tooth Coronal Index As A Forensic Tool For Age Assessment In Population Of North Western India

Dr Kriti Agarwal^{1*}, Dr Akshay Bhargava², Dr Krishna Sireesha Sundaragiri³,
Dr Shikha Saxena³, Dr Bharat Sankhla³, Dr Geetika Sobti⁴, Dr Jaishree Thanvi⁵,
Kritika Karwasra⁶, Dr Meenakshi⁷, Dr Ghata⁷, Dr Reena Pabri⁸

¹(Post Graduate, Department Of Oral Pathology Ruhs College Of Dental Sciences Jaipur, Rajasthan, India)

²(Professor And Head Of Dept., Department Of Oral Pathology Ruhs College Of Dental Sciences Jaipur, Rajasthan, India)

³(Professor, Department Of Oral Pathology Ruhs College Of Dental Sciences Jaipur, Rajasthan, India)

⁴(Associate Professor And Head Of Dept., Department Of Oral Radiology Ruhs College Of Dental Sciences Jaipur, Rajasthan, India)

⁵(Associate Professor, Department Of Oral Radiology Ruhs College Of Dental Sciences Jaipur, Rajasthan, India)

⁶(Phd Student, Department Of Ieor, Iit Bombay, India)

⁷(Associate Professor, Department Of Oral Pathology Ruhs College Of Dental Sciences Jaipur, Rajasthan, India)

⁸(Senior Demonstrator, Department Of Oral Pathology Ruhs College Of Dental Sciences Jaipur, Rajasthan, India)

Abstract:

Background: The Tooth Coronal Index (TCI) is a dental measurement used in forensic anthropology to estimate age at death. It is based on the observation that as a person ages, secondary dentin gradually accumulates at the base of the tooth crown, reducing the height of the pulp cavity. The TCI is calculated by dividing the height of the coronal pulp cavity by the height of the crown and expressing it as a percentage. This non-invasive method is particularly useful in cases where other skeletal age indicators are unavailable or unreliable, and it has been applied in various populations to improve the accuracy of age estimation in adults. Its simplicity and effectiveness make it a valuable tool in both archaeological research and modern forensic investigations.

Materials and Methods: In the current study, the cone-beam computed tomography (CBCT) scans of 93 people between the ages of 20-70 years were examined retrospectively in department of Oral Radiology. The coronal height of the crown as well as the height of the coronal pulp cavity of mandibular first molar and second premolar were calculated and TCI was measured. The data were then subjected to statistical analysis after being compared to the subject's real age and the TCI of their teeth. The Welch method was applied, p value, t value and slope were determined. Sum of square regression and linear regression was also calculated.

Results: Negative correlation was observed between real age and TCI of mandibular first molar and second premolar. Statistically significant results was observed between actual age and TCI for mandibular second premolar.

Conclusion: On CBCT scans, tooth coronal index has the potential to determine an individual's age. It is more reliable for males and showed negative correlation with age. It is easy to use, less expensive and applicable to both living people and unidentified corpses.

Key Word: Forensic odontology; Cone Beam Computed Tomography; Age Estimation

Date of Submission: 28-07-2024

Date of Acceptance: 08-08-2024

I. Introduction

In forensic odontology, determining a person's age is a crucial part of biological identification. The teeth and bones of the craniofacial complex are important identifying markers for forensic odontology.¹ Estimating someone's age is a challenging undertaking that requires a multidisciplinary approach.² Determining the age of victims is crucial for identifying missing bodies or skeletal remains from crimes, disasters and accidents. Anthropometric techniques for determining a person's gender, age, height, and ethnicity provide

details about the person that police investigators can use to better understand missing persons reports.³ Because teeth are resistant to a variety of taphonomic processes, diseases, medication use, and endocrine status, they are preferred over bone mineralization in forensic and archaeological investigations.⁴⁻⁶ As the hardest part of the body, teeth can be retained after death for a very long period without undergoing significant alterations.⁷⁻⁸ Radiographic, biochemical, and morphological techniques can all be used to estimate an individual's age from their teeth.

The most popular approach was initially employed by Gustafson.⁹ and modified by Johanson.¹⁰ Other methods include cementum annulations and dentinal translucency.¹¹⁻¹² These techniques are inappropriate for use on living people since they necessitate the extraction of teeth. Thus, non-invasive radiological techniques are developed for living individuals.

Bodecker discovered in 1925 that the apposition of secondary dentine corresponded to chronological age. Due to secondary dentin deposition, the pulp shrinks in size as people age.¹³ Using radiographs of extracted teeth, Ikeda et al. established the tooth coronal index (TCI) in 1985 to estimate age.¹⁴ Drusini conducted research on age estimation using TCI in 1993 using radiographs of living subjects.¹⁵ To create a regressive formula for the Western population, numerous studies have been conducted. Nevertheless, there is uncertainty over the reproducibility of these characteristics because different ethnic groups may have different values,¹⁶ moreover different studies have been conducted using different radiographic techniques resulting in subsequent variations in TCI measurements and hence varied results. Thus, this study aims to estimate age using tooth measurements applying the more precise radiographic technique of CBCT and to assess the reliability of TCI in age assessment in population of North Western India.

II. Material And Methods

A retrospective study was conducted on CBCT scans of 20-70 years patients who were referred to the Department of Oral Radiology as an aid for diagnosis of their primary complaint in the year of 2023. The research was approved by the Institutional Ethical Committee (RUHS-CDS/EC/2023/PG-The/002). 186 CBCT scans (93 mandibular second premolar and 93 mandibular first molar) from 93 individuals (58 males and 35 females) in age group 20-70 years were evaluated using software CS 3D Imaging V 3.8.7 of CBCT machine CS9300 and correlated with patient actual age. The sample size was calculated using G-Power 3.1.9.2 software considering the correlation Coefficient (ρ) to be measured at 0.3, power of the study at 80% and the margin of the error at 5%, the sample size needed was 84 which was rounded off to 90.

The ideal quality CBCT scans without any artifact in age between 20 years to 70 years were included which were divided into five age groups (20-30,31-40,41-50,51-60,61-70). The permanent mandibular first molar and mandibular second premolar were selected for TCI measurements on CBCT. The exclusion criteria were, teeth which showed any pathology such as caries, grossly decayed, restored, endodontically or prosthetically restored teeth, teeth which were badly rotated or showed an enamel overlap, and teeth which showed developmental anomalies related to size, shape and structure.

Measurement Of Tci

On sagittal section of the scan, straight line was drawn from mesial to distal aspect on the cemento-enamel junction—the point where the anatomical crown and root separates (CEJ Line). Two lines horizontal and parallel to the CEJ line were drawn; one tangential to the highest cusp tip and other tangential to the highest pulp horn (Figure 1a Figure 1b). Then the following measurements were acquired on mandibular first molar (TCI Molar) and mandibular second premolar (TCI Premolar) on CBCT scans:

- 1) Crown height (CH): vertical measurement taken from line to highest cusp point.¹³
- 2) Coronal pulp cavity height (CPCH): measured vertically from the highest pulp horn tip to the cervical line.¹⁸
- 3) TCI = $CPCH \times 100/CH$.¹⁸

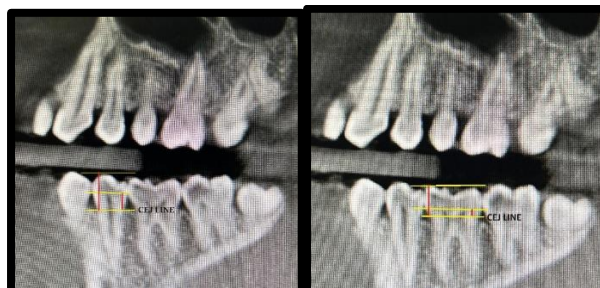

Figure 1: a) Sagittal section of CBCT with measurements on mandibular second

Figure 1: b) Sagittal section of CBCT with measurements on mandibular first molar premolar

The observations were summarized and tabulated in an excel spreadsheet and subjected to statistical analysis of Welch t-test. A line of best fit and an equation were used to illustrate linear regression for different age and gender groupings. The study's power was 80% when $P < 0.05$ was deemed statistically significant, maintaining α error at 5% and β error at 20%.

III. Result

The Welch t-test method was used to check the significant difference between means of different study groups (actual age, TCI Molar and TCI Premolar). Using TCI Molar, the mean for predicted age was 43.591 ± 5.218 years and using TCI premolar it was 44.057 ± 5.698 years when compared to the actual age (43.591 ± 14.005 years) (Table 1). So the actual age and the predicted age using TCI values are similar for whole population. A lower regression sum of squares value for TCI Premolar (276.91) is observed compared to predictions made using TCI Molar values (305.17) (Table 2), making TCI Premolar a better predictor of patient age. Figure 2 presents the graph for scattered plot and linear regression lines of actual age, predicted age using TCI Molar values and TCI Premolar values. The regression sum of squares for males using TCI Premolar was (360.26) when compared to TCI Molar (365.68) thus, TCI Premolar prediction again yielded better results for males, while for females TCI Molar prediction (362.09) performed better in contrast to TCI Premolar (437.41) (Table 3).

Table 1: Descriptive statistics for Actual age and predicted age using TCI Molar and Premolar values.

	N	Mean	SD	SE
Actual Age	93	43.591	14.005	1.45
Predicted age using TCI Molar	93	43.591	5.218	0.541
Predicted age using TCI Premolar	93	44.057	5.698	0.591

N: Sample size, SD: Standard deviation, SE: Standard Error Mean

Table 2: Comparison of mean difference of actual age from calculated age using TCI Molar and TCI Premolar values

	N	Mean	SD	SE	Slope	Intercept	r^2
TCI Molar	93	43.591	5.218	1.588	-0.598	62.484	305.17
TCI Pre Molar	93	44.057	5.698	1.576	-0.653	64.688	276.91

N: Sample size, SD: Standard deviation, SE: Standard Error Mean, r^2 : Regression sum of square

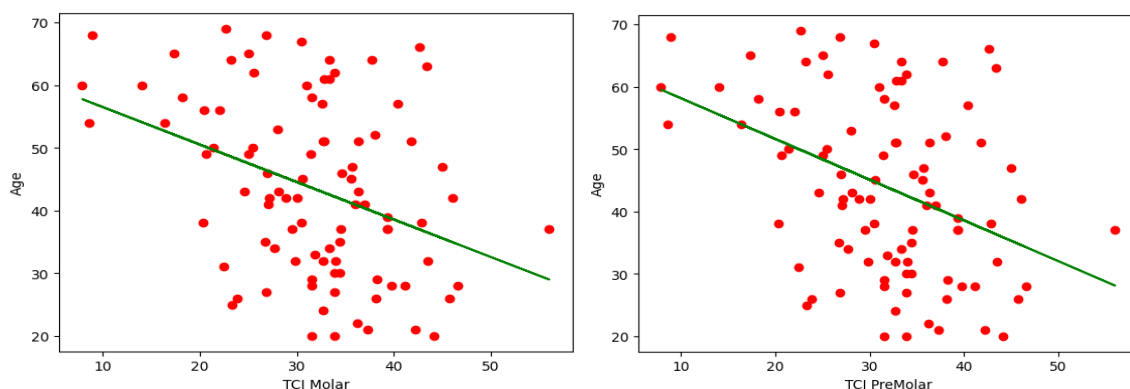


Figure 2: a) Scatter plot and regression line of age on TCI values for Molars (combined sample), b) Scatter plot and regression line of age on TCI values for Premolars (combined sample)

Table 3: Comparison of mean difference of actual age from calculated age in male and female group

MALE	N	Mean	SD	Slope	Intercept	r^2
Actual Age	58	44.4915	14.704			
TCI Molar	58	44.4915	5.9776	-0.6481	65.7014	365.68
TCI Premolar	58	44.4915	2.723	-0.2468	52.7334	360.26

<i>FEMALE</i>						
Actual Age	35	42.5142	12.891			
TCI Molar	35	42.5142	0.9473	-0.0984	45.4886	362.089
TCI Premolar	35	42.5143	1.1828	0.1708	37.067	437.41

N: Sample size, SD: Standard deviation, r^2 : Regression sum of square

IV. Discussion

The measurement of the pulp cavity volume and the development of the third molar are the two parameters that can be used to determine an adult's age.¹⁷ Radiography can be used to measure how much the pulp cavity has shrunk as a result of secondary dentine deposition with ageing.¹⁸ Secondary dentin deposition can be indirectly quantified by evaluating the pulp/tooth index.¹⁹

This is the first study which was conducted specifically on north western Indian population to measure the morphometric values of pulp on 186 CBCT samples for the mandibular first molar and mandibular second premolar, thereby adding on the existing literature which were performed in south India³¹, Italy²³, Malavi²², Iraq²⁷, Egypt³⁰, Australian²⁶ population.

Prior researches by Talabani RM et al.²⁷, Da, El Morsi et al.³⁰, HL Ahmed khan³³ employed digital panoramic radiographs for age assessment while Igbigbi and Nyirenda²² and Gotmare SS et al.³¹ used conventional OPG for the same and Koranne VV et al.²⁹ had used IOPA in paralleling technique. However, due to the panoramic images susceptibility to distortion, enlargement, and unsharpness^{27,28}, CBCT was utilised in the present investigation, similar to the study done by Doni BR²⁰.

Similar to our study most of the researchers like Doni BR²⁰, Koranne²⁹, Igbigbi and Nyirenda²², Gotmare³¹ used the same teeth mandibular first molar and mandibular second premolar for TCI calculation, while Agematsu²¹ used mandibular central incisors along with mandibular second premolars, Talabani²⁷ used only mandibular first molar and HL Ahmed khan³³ used only mandibular first premolars. In contrast Da EL Morsi³¹ used all the mandibular molars except third molars and all the mandibular premolars.

The present investigation findings of negative correlation between the predicted age and the TCI is supported by studies of Drusini¹⁵ in Italy, Zadinska et al.²³ in Italy, Agematsu et al²¹ in Japan, Igbigbi and Nyirenda²² in Malavi, Karkhanis²⁶ et al in Australia, Talabani et al²⁷ in Iraq. While Da, El Morsi³¹ in Egypt, Shrestha²⁴ and Gotmare³¹ in India have found positive correlation between predicted age and TCI.

Based on different statistical data the research conducted by Doni BR²⁰, Igbigbi and Nyirenda²² are in accordance of present study indicating mandibular second premolar to be a better predictor for age estimation in contrast to the study conducted by Talabani²⁷ which supports mandibular first molar.

According to present study there is gender difference in age predicted by TCI which is also supported by Agematsu et al²¹ Igbigbi and Nyirenda²². Igbigbi and Nyirenda²² concluded that gender significantly affects age estimation using TCI because estrogen influences the production of secondary dentin, so there is a need for sex-specific formulae in sampled population³² which is contraindicatory to that of Drusini et al¹⁷ Zadinska et al²³ Shrestha²⁴ Khattab et al²⁵ and Karkhanis et al²⁶ which found no differences in TCI based on gender. TCI is a reliable, reproducible, easy to conduct, non-invasive age estimation method based on radiography.

V. Conclusion

According to the present study, age estimation from TCI on the mandibular second premolar can be simply applied to living humans and does not require highly specialized equipment. The current study's findings, which are legitimate given the small sample size, demonstrated that TCI was more accurate in treating the male population than the female one. We conducted our study on a group of people living in Western India. However, comparable research needs to be carried out on a bigger sample in order to reduce standard errors, obtain maximum reproducibility, and develop a universal formula across all ethnic groups and gender.

References

- [1] Koranne VV, Mhapuskar AA, Marathe SP, Joshi SA, Saddiwal RS, Nisa SU. Age estimation in Indian adults by the coronal pulp cavity index. *J Forensic Dent Sci.* 2017;9(3):177. doi:10.4103/jfo.jfids_60_16
- [2] Santoro V, De Donno A, Marrone M, Campobasso CP, Introna F. Forensic age estimation of living individuals: a retrospective analysis. *Forensic Sci Int* 2009; 193(1-3):129.e1-4. <https://doi.org/10.1016/j.forsciint.2009.09.014>
- [3] Karen Boaz, Chhavi Gupta. Dimorphism in human maxillary and mandibular canines in establishment of gender. *jfds* [Internet]. 2009;1(1):42-4. Available from: <https://www.jfds.org/index.php/jfds/article/view/219>
- [4] Maber M, Liversidge HM, Hector MP. Accuracy of age estimation of radiographic methods using developing teeth. *Forensic Sci Int.* 2006;159 Suppl 1:S68-S73. doi:10.1016/j.forsciint.2006.02.019
- [5] Willems G. A review of the most commonly used dental age estimation techniques. *J Forensic Odontostomatol.* 2001;19(1):9-17. Yang F, Jacobs R, Willems G. Dental age estimation through volume matching of teeth imaged by cone-beam CT. *Forensic Sci Int.* 2006 May 15;159 Suppl 1:S78-83.
- [6] Cameriere R, Ferrante L, Belcastro MG, Bonfiglioli B, Rastelli E, Cingolani M. Age estimation by pulp/tooth ratio in canines by peri-apical X-rays. *J Forensic Sci* 2007;52:166-70.

- [7] Joseph CC, Reddy BH, Cherian NM, Kannan SK, George G, Jose S. Intraoral dental radiography for adult age estimation: A reliable technique. *J Indian Acad Oral Med Radiol* 2013;25:287-90.
- [8] GUSTAFSON G. Age determination on teeth. *J Am Dent Assoc*. 1950;41(1):45-54. doi:10.14219/jada.archive.1950.0132
- [9] Johanson G. Age determination from teeth. *Odontol Revy* 1971;22:1-126.
- [10] Kagerer P, Grupe G. Age-at-death diagnosis and determination of life-history parameters by incremental lines in human dental cementum as an identification aid. *Forensic Sci Int*. 2001;118(1):75-82. doi:10.1016/s0379-0738(00)00382-0
- [11] Wittwer-Backofen U, Gampe J, Vaupel JW. Tooth cementum annulation for age estimation: results from a large known-age validation study. *Am J Phys Anthropol*. 2004;123(2):119-129. doi:10.1002/ajpa.10303
- [12] Koranne VV, Mhapuskar AA, Marathe SP, Joshi SA, Saddiwal RS, Nisa SU. Age estimation in Indian adults by the coronal pulp cavity index. *J Forensic Dent Sci*. 2017;9(3):177. doi:10.4103/jfo.jfds_60_16
- [13] Ikeda N, Umetsu K, Kashimura S, Suzuki T, Oumi M. Estimation of age from teeth with their soft X-ray findings. *Nihon Hoigaku Zasshi* 1985;39:244-50.
- [14] Drusini AG. Age estimation from teeth using soft X-ray findings. *Anthropol Anz* 1993;51:41-6.
- [15] Saxena S. Age estimation of Indian adults from orthopantomographs. *Braz Oral Res* 2011;25:225-9.
- [16] Sharma S, Karjodkar F, Sansare K, Mehra A, Sharma A, Saalim M. Age Estimation Using the Tooth Coronal Index on Mandibular First Premolars on Digital Panoramic Radiographs in an Indian Population. *Front Dent*. 2023;20:6. Published 2023 Apr 11. doi:10.18502/ffd.v20i6.12465
- [17] Drusini AG, Toso O, Ranzato C. The coronal pulp cavity index: A biomarker for age determination in human adults. *Am J Phys Anthropol* 1997;103:353-63.
- [18] Veera SD, Kannabiran J, Suratkal N, Chidananda DB, Gujjar KR, Goli S. Coronal pulp biomarker: A lesser known age estimation modality. *J Indian Acad Oral Med Radiol* 2014;26:398.
- [19] Grover S, Marya CM, Avinash J, Pruthi N. Estimation of dental age and its comparison with chronological age: accuracy of two radiographic methods. *Med Sci Law*. 2012;52(1):32-35. doi:10.1258/msl.2011.011021
- [20] Doni BR, Patil SR, Agrawal R, Ghazi N, Araki K, Dewangan G, Alam MK. Tooth Coronal Index: A Novel Tool For Age Estimation on Cone-Beam Computed Tomography. *Pesqui Bras Odontopediatria Clin Integr [Internet]*. 2021 Nov. 13 [cited 2024 Jun. 14];21:e0215.
- [21] Agematsu H, Sameda H, Hashimoto M, Matsunaga S, Abe S, Kim HJ, et al. Three-dimensional observation of decrease in pulp cavity volume using micro-CT: Age-related change. *Bull Tokyo Dent Coll* 2010;51:1-6.
- [22] Igbigbi PS, Nyirenda SK. Age estimation of Malawian adults from dental radiographs. *West Afr J Med* 2005;24:329-33.
- [23] Zadinska E, Drusini AG, Carrara N. The comparison between two age estimation methods based on human teeth. *Anthropol Rev* 2000;63:95-101
- [24] Shrestha M. Comparative evaluation of two established age estimation techniques (Two histological and radiological) by image analysis software using single tooth. *J Forensic Res* 2014;5:1-6.
- [25] Khattab NA, Marzouk HM, AbdelWahab TM. Application of tooth coronal index for age estimation among adult Egyptians. *Schoolary Res* 2013;1-15.
- [26] Karkhanis S, Mack P, Franklin D. Age estimation standards for a Western Australian population using the coronal pulp cavity index. *Forensic Sci Int* 2013;231:412.e1-6.
- [27] Talabani RM, Baban MT, Mahmood MA. Age estimation using lower permanent first molars on a panoramic radiograph: A digital image analysis. *J For Dent Sci* 2015; 7(2):158-62. <https://doi.org/10.4103/0975-1475.154597>
- [28] Devlin H, Yuan J. Object position and image magnification in dental panoramic radiography: a theoretical analysis. *Dentomaxillofac Radiol* 2013; 42(1):29951683. <https://doi.org/10.1259/dmfr/29951683>
- [29] Koranne VV, Mhapuskar AA, Marathe SP, Joshi SA, Saddiwal RS, Nisa SU. Age estimation in Indian adults by the coronal pulp cavity index. *J Forensic Dent Sci* 2017; 9(3):177. https://doi.org/10.4103/jfo.jfds_60_16
- [30] El Morsi DA, Rezk HM, Aziza A, El – Sherbiny M Tooth Coronal Pulp Index as a Tool for Age Estimation in Egyptian Population. *J Forensic Sci Criminol* 2015 2(5): 502
- [31] Gotmare SS, Shah T, Periera T, et al. The coronal pulp cavity index: A forensic tool for age determination in adults. *Dent Res J (Isfahan)*. 2019;16(3):160-165.
- [32] Kvaal SI, Kolltveit KM, Thomsen IO, Solheim T. Age estimation of adults from dental radiographs. *Forensic Sci Int*. 1995 Jul 28;74(3):175-85. doi: 10.1016/0379-0738(95)01760-g. PMID: 7557754.
- [33] Ahmed Khan HL, Murthykumar K, Sekaran S, Ganapathy D. Digital Panoramic Radiographs for Age Prediction Utilizing the Tooth Coronal Index of First Mandibular Bicuspid Among the South Indian Population. *Cureus*. 2023;15(9):e45870. Published 2023 Sep 24. doi:10.7759/cureus.45870.