

## Occult Breast Cancer Presenting As Axillary Lymphadenopathy: A Case Report

Dr. Rubama Karim<sup>1</sup>, Prof. Dr. Qamruzzaman Chowdhury<sup>2</sup>, Dr. Leea Amin<sup>3</sup>

Dr. Jannataul Ferdause<sup>4</sup>, Dr. Sura Jukrup Momtahena<sup>5</sup>,

Dr. Aditi Paul Chowdhury<sup>6</sup>, Dr. Nowshin Taslima Hossain<sup>7</sup>

Junior Consultant, Radiation Oncology, Ahsania Mission Cancer & General Hospital, Dhaka, Bangladesh

Senior Consultant, Radiation Oncology, Ahsania Mission Cancer & General Hospital, Dhaka, Bangladesh

Consultant, Surgery, Ahsania Mission Cancer & General Hospital, Dhaka, Bangladesh

Associate Consultant, Radiation Oncology, Ahsania Mission Cancer & General Hospital, Dhaka, Bangladesh

Consultant, Radiation Oncology, Ahsania Mission Cancer & General Hospital, Dhaka, Bangladesh

Junior Consultant, Radiation Oncology, Ahsania Mission Cancer & General Hospital, Dhaka, Bangladesh

Junior Consultant, Radiation Oncology, Ahsania Mission Cancer & General Hospital, Dhaka, Bangladesh

---

### Abstract

**Background:** Occult breast cancer (OBC) presenting as axillary lymphadenopathy is a rare and diagnostically challenging condition, where metastatic disease is identified in the axillary lymph nodes without a detectable primary tumor in the breast.

**Case Presentation:** We report the case of Fatema Begum, a 65-year-old postmenopausal woman who presented with a huge, firm lump in her right axilla. Biopsy confirmed invasive ductal carcinoma, and mammography revealed no abnormalities in the breasts. Advanced imaging, including CT and MRI, was employed to further evaluate the extent of the disease. The patient underwent neoadjuvant chemotherapy with AC regimen, resulting in a significant reduction in the size of the axillary lymph node. This was followed by a right modified radical mastectomy with axillary clearance, three cycles of taxanes, and radiotherapy to the right chest wall and axilla. The patient was prescribed letrozole thereafter due to ER and PR positivity. Trastuzumab was recommended but not administered due to financial constraints.

**Conclusion:** Axillary lymphadenopathy should raise high suspicion of breast pathology and thorough investigations should be done to exclude breast origin. Occult Breast Cancer is treated conventionally using chemotherapy, surgery, radiotherapy and hormonal therapy. More case reports may help in standardizing treatment guidelines for this cancer.

**Keywords:** Carcinoma, Occult Breast Cancer, Axilla, Axillary Lymphadenopathy

---

Date of Submission: 22-07-2024

Date of Acceptance: 02-08-2024

---

### I. Introduction

Occult breast cancer (OBC) is a rare presentation of breast malignancy, characterized by the presence of metastatic disease, commonly in the axillary lymph nodes, without an identifiable primary tumor in the breast through clinical examination or conventional imaging techniques such as mammography or ultrasound. This condition poses significant diagnostic and therapeutic challenges due to the absence of detectable primary lesions, making it a unique clinical entity in breast cancer management (1). The detection and treatment of OBC are critical, as the absence of a primary tumor often leads to delays in diagnosis and appropriate treatment, impacting patient outcomes (2). OBC accounts for approximately 0.1% to 1% of all breast cancer cases, with varying prevalence reported globally. Studies have indicated that the incidence of OBC presenting as isolated axillary lymphadenopathy is relatively low but clinically significant (3,4). In a retrospective review of patients treated for OBC at a comprehensive cancer center, it was found that the condition remains a diagnostic enigma, with many cases requiring extensive imaging and histopathological evaluation to confirm the diagnosis (5). The rarity of OBC presenting as axillary lymphadenopathy is further highlighted by studies reporting that only a small percentage of breast cancer patients initially present with this clinical scenario, necessitating a high index of suspicion and thorough diagnostic workup (6). The clinical presentation of OBC is often non-specific, with patients typically presenting with axillary lymphadenopathy without a palpable breast mass. This presentation complicates the diagnostic process, as the primary tumor is not visible through conventional imaging methods. Advanced imaging techniques such as magnetic resonance imaging (MRI) have shown promise in identifying occult lesions that are not detectable by mammography or ultrasound. MRI has been found to detect occult breast

cancer in a significant proportion of patients, thereby aiding in the accurate diagnosis and facilitating appropriate treatment planning (7,8). Despite the advancements in imaging, the diagnostic workup for OBC remains challenging. Differential diagnosis is crucial to rule out other causes of axillary lymphadenopathy, such as lymphoma or metastatic disease from non-breast primaries. Biopsy and histopathological examination of the axillary lymph nodes are essential steps in confirming the diagnosis of OBC (9). The management of OBC involves a combination of surgical and systemic therapies. Surgical options include mastectomy and axillary lymph node dissection, which aim to remove the metastatic nodes and reduce the risk of local recurrence. Studies have shown that aggressive surgical intervention can lead to better outcomes compared to less invasive treatments (10). Radiotherapy is also an important component of the treatment regimen, particularly in cases where breast-conserving surgery is performed or when the primary tumor remains undetectable. The role of systemic therapies, including chemotherapy and hormonal therapy, is well established in the management of OBC, with treatment decisions often guided by the tumor's biological characteristics and receptor status (11). Prognosis and outcomes for patients with OBC vary depending on several factors, including the extent of metastatic involvement, the biological characteristics of the tumor, and the timeliness of diagnosis and treatment. Studies have reported that patients with OBC generally have a prognosis similar to those with detectable primary breast tumors when treated appropriately (12). However, the absence of a primary tumor can complicate treatment decisions and impact survival rates. Data from various studies indicate that timely diagnosis and comprehensive treatment approaches are crucial for improving survival outcomes in patients with OBC (13). In conclusion, OBC presenting as axillary lymphadenopathy is a rare but significant clinical entity that poses unique diagnostic and therapeutic challenges. Advanced imaging techniques such as MRI play a critical role in detecting occult lesions and guiding treatment decisions. A multidisciplinary approach involving surgery, radiotherapy, and systemic therapies is essential for managing this condition effectively. Further research is needed to develop standardized diagnostic and treatment protocols to improve outcomes for patients with OBC. The case of a Bangladeshi postmenopausal patient with OBC underscores the importance of awareness and comprehensive diagnostic workup in managing this rare presentation of breast cancer.

## II. Case Presentation

**Patient Information:** Fatema Begum, a 65-year-old postmenopausal woman, presented with a significant, hard lump in the right axilla. She had no prior history of breast cancer or any significant comorbidities.

**Clinical Presentation:** The patient reported the sudden discovery of a large, hard lump in her right axilla, which prompted her to seek medical attention. On physical examination, the lump was found to be firm and non-tender, located in the right axillary region. No palpable masses were detected in either breast during the clinical examination.

### Initial Diagnostic Workup:

- **Biopsy:** A core biopsy of the axillary lump was performed. Histopathological analysis confirmed the presence of invasive ductal carcinoma.
- **Mammography:** Bilateral mammography showed no evidence of a primary breast tumor, but did confirm the presence of axillary lymphadenopathy on the right side.
- **CT Scan:** A contrast-enhanced CT scan of the chest revealed an ill-defined mass in the right axilla with no significant findings in the breast tissue and no evidence of pulmonary metastases. **Ultrasound (USG):** An ultrasound examination of the whole abdomen showed normal findings, with no abnormalities detected in the liver, kidneys, spleen, pancreas, or gallbladder. The liver was noted to be mildly enlarged, but without focal lesions.
- **Hematological Profile:** Blood tests showed a hemoglobin level of 14.5 g/dL and a white blood cell count of 9000/cumm. Tumor markers included CA 15.3 at 17.7 and CA 125 at 6.7, both within normal ranges.
- **Immunohistochemistry:** The biopsy specimen tested positive for estrogen receptor (ER), progesterone receptor (PR), and HER2, indicating a triple-positive breast cancer profile.

**Multidisciplinary Tumor Board Review:** The case was presented at a multidisciplinary tumor board. PET-CT scan was recommended but due to financial constraint, patient could not do it. The board advised initiating neoadjuvant chemotherapy as a first-line treatment.

### Treatment Course:

- **Neoadjuvant Chemotherapy:** The patient was started on chemotherapy with AC regimen. After four cycles of chemotherapy, there was a notable reduction in the size of the axillary lymph node.
- **Surgery:** Following the positive response to chemotherapy, the patient underwent a right modified radical mastectomy with axillary clearance. The histopathology report post-surgery showed ypT0ypN1yMx, indicating no residual tumor in the breast but presence of metastasis in one lymph node.

- **Adjuvant Therapy:** Post-operatively, the patient received three cycles of paclitaxel. This was followed by radiotherapy to the right chest wall and axilla, with a total dose of 4005 cGy delivered over 15 fractions. The patient then started letrozole, a hormonal therapy, due to the positive ER and PR status. Trastuzumab was recommended for HER2 positivity but was declined by the patient due to financial constraints.

**Radiotherapy Details:**

- **Radiotherapy Plan:** The treatment included radiation to the right chest wall and supraclavicular region using a telecobalt machine. The prescribed radiation dose was 4005 cGy, administered in 267 cGy fractions over 15 sessions.

**Follow-Up and Outcome:** At the follow-up visit, the patient reported no new complaints. A thorough clinical examination and subsequent investigations revealed no new abnormalities. The patient showed a good response to the treatment regimen, with no signs of recurrence or metastasis.

**Impression:** Fatema Begum was diagnosed with occult breast cancer presenting as axillary lymphadenopathy, a rare but challenging clinical scenario. The patient underwent a comprehensive and multidisciplinary treatment approach that included neoadjuvant chemotherapy, surgery, adjuvant chemotherapy, radiotherapy, and hormonal therapy. Despite financial constraints limiting the use of some therapeutic options, the patient's condition showed significant improvement, underscoring the importance of a tailored treatment plan in managing such complex cases.

### III. Discussion

Occult breast cancer (OBC) presenting as axillary lymphadenopathy is a rare and diagnostically challenging condition, with patients often exhibiting axillary metastases without a detectable primary tumor in the breast through conventional imaging techniques. This case of a 65-year-old postmenopausal woman, Fatema Begum, exemplifies the complexities and diagnostic hurdles associated with OBC. The initial presentation with a large, hard axillary lump that was confirmed to be invasive ductal carcinoma via biopsy, without detectable abnormalities in breast mammography, aligns with the typical presentation of OBC (12). Advanced imaging modalities, such as MRI, have shown increased sensitivity in identifying occult primary tumors in patients with axillary metastases. Studies have demonstrated that MRI can detect primary breast lesions that are otherwise missed by mammography and ultrasound, thus playing a crucial role in the diagnostic workup of OBC (12,14). In this case, despite the absence of abnormalities on mammography, the utilization of MRI could have potentially identified the primary lesion, highlighting the importance of advanced imaging in such diagnostic dilemmas. The treatment strategies for OBC often involve a combination of neoadjuvant chemotherapy, surgery, and adjuvant therapies. In this case, the patient underwent neoadjuvant chemotherapy with an AC regimen, which led to a significant reduction in the size of the axillary lymph node. This approach is consistent with the findings of several studies that advocate for the use of neoadjuvant chemotherapy in managing OBC, as it can effectively reduce tumor burden and improve surgical outcomes (15,16). The subsequent modified radical mastectomy with axillary clearance further aligns with the standard treatment protocols for OBC, which aim to achieve local control and prevent recurrence (17). The role of radiotherapy in OBC management is well-documented, with studies indicating that radiotherapy to the breast and regional lymph nodes significantly reduces the risk of locoregional recurrence. Shannon et al. (2002) reported that patients receiving radiotherapy had significantly lower locoregional recurrence rates compared to those who did not, underscoring the necessity of including radiotherapy in the treatment regimen (18). In this case, the patient received radiotherapy to the right chest wall and axilla post-surgery, which likely contributed to the favorable outcome observed during follow-up. Hormonal therapy, particularly in ER and PR-positive tumors, is another critical component of OBC treatment. The patient's initiation of letrozole therapy aligns with standard practices for managing hormone receptor-positive breast cancer, as supported by the findings of multiple studies (15,17). Despite the recommendation for trastuzumab due to HER2 positivity, the patient's financial constraints prevented its use. This highlights a significant barrier in the management of OBC, where the cost of targeted therapies can limit their accessibility and potentially impact patient outcomes. Comparative studies have shown that the prognosis for patients with OBC who receive comprehensive treatment is generally favorable, with outcomes comparable to those of patients with detectable primary tumors. Chen et al. (2004) reported a 5-year overall survival rate of 87% in patients with MRI-detected OBC, while Kuerer et al. (1999) noted significantly improved disease-free survival rates in patients who achieved a complete pathologic response after neoadjuvant chemotherapy (12,15). These findings underscore the importance of a multidisciplinary approach in managing OBC to optimize patient outcomes. However, it is essential to acknowledge the prognostic factors that can influence outcomes in OBC patients. Studies have identified the number of involved lymph nodes and the molecular subtype of the tumor as critical determinants of prognosis. He et al. (2012) reported that patients with four or more positive lymph nodes had significantly worse

outcomes, while those with triple-negative tumors were at higher risk of recurrence and poorer survival (17). In this case, the presence of HER2 positivity, despite the patient's refusal of trastuzumab, highlights the need for tailored treatment plans that consider both clinical and socioeconomic factors. In conclusion, the case of Fatema Begum illustrates the diagnostic and therapeutic complexities of managing OBC presenting as axillary lymphadenopathy. The integration of advanced imaging, neoadjuvant chemotherapy, surgical intervention, radiotherapy, and hormonal therapy forms the cornerstone of effective management. Comparative analyses with existing literature reinforce the importance of a multidisciplinary approach and highlight the critical prognostic factors that influence outcomes. Continued research and efforts to improve access to comprehensive care are essential to enhance the prognosis and quality of life for patients with OBC.

#### *Limitations of The Study*

Anti-Her-2 agent could not be incorporated in the treatment due to financial constraint of the patient.

### **IV. Conclusion**

In conclusion, the case of Fatema Begum highlights the complex diagnostic and therapeutic challenges associated with occult breast cancer (OBC) presenting as axillary lymphadenopathy. Despite the absence of a detectable primary tumor in the breast, a multidisciplinary approach that included neoadjuvant chemotherapy, surgical intervention, and adjuvant therapies resulted in a favorable outcome. This case underscores the importance of advanced imaging techniques, such as MRI, in identifying occult primary tumors and guiding treatment strategies. It also emphasizes the need for tailored treatment plans that consider both clinical and socioeconomic factors, particularly in resource-limited settings. The successful management of this case reinforces the efficacy of comprehensive treatment protocols in improving prognosis and quality of life for patients with OBC.

**Funding:** No funding sources

**Conflict of interest:** None declared

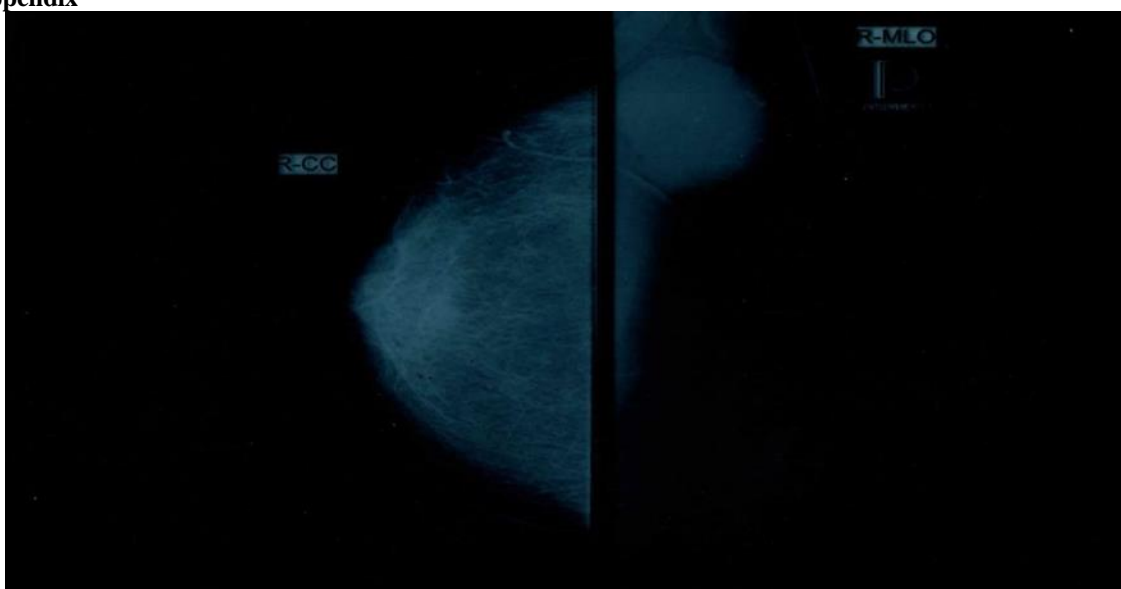
**Ethical approval:** The study was approved by the Institutional Ethics Committee

### **References**

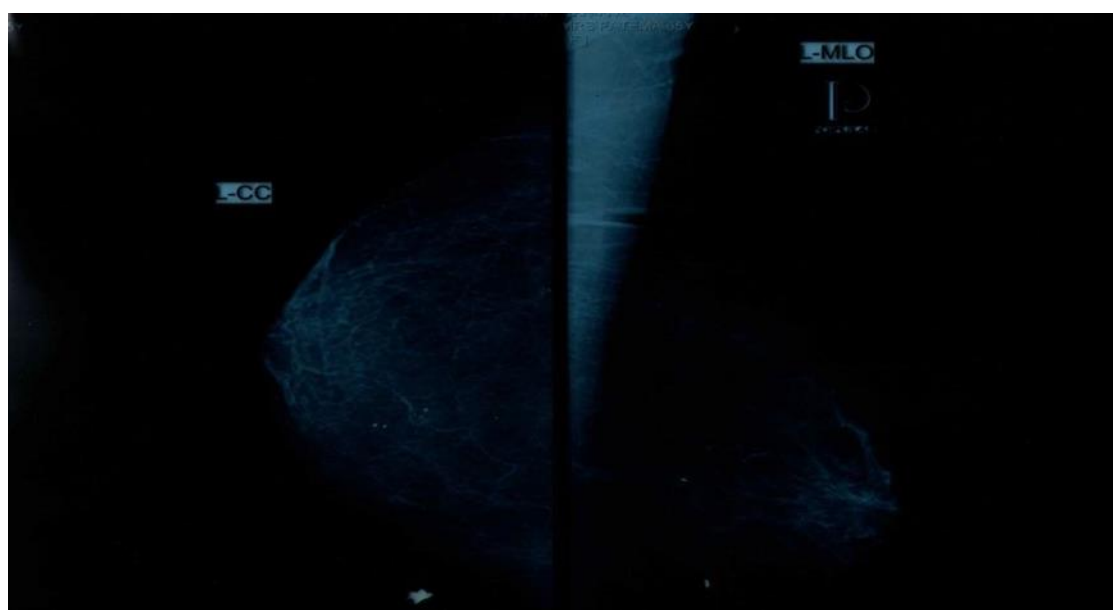
- [1] Buchanan Cl, Morris Ea, Dom Pl, Borgen Pi, Van Zee Kj. Utility Of Breast Magnetic Resonance Imaging In Patients With Occult Primary Breast Cancer. *Ann Surg Oncol* [Internet]. 2005 Dec 1 [Cited 2024 Jun 9];12(12):1045–53. Available From: <https://doi.org/10.1245/aso.2005.03.520>
- [2] Brill Kl, Brenin Dr. Occult Breast Cancer And Axillary Mass. *Curr Treat Options In Oncol* [Internet]. 2001 Apr 1 [Cited 2024 Jun 9];2(2):149–55. Available From: <https://doi.org/10.1007/s11864-001-0057-x>
- [3] Fayanju Om, Jeffe Db, Margenthaler Ja. Occult Primary Breast Cancer At A Comprehensive Cancer Center. *Journal Of Surgical Research* [Internet]. 2013 Dec 1 [Cited 2024 Jun 9];185(2):684–9. Available From: [https://www.journalofsurgicalresearch.com/article/S0022-4804\(13\)00609-4/abstract](https://www.journalofsurgicalresearch.com/article/S0022-4804(13)00609-4/abstract)
- [4] Foroudi F, Tiver Kw. Occult Breast Carcinoma Presenting As Axillary Metastases1. *International Journal Of Radiation Oncology, Biology, Physics* [Internet]. 2000 Apr 1 [Cited 2024 Jun 9];47(1):143–7. Available From: [https://www.redjournal.org/article/S0360-3016\(99\)00542-8/abstract](https://www.redjournal.org/article/S0360-3016(99)00542-8/abstract)
- [5] Crotch-Harvey M. Occult Breast Carcinoma Presenting With Axillary Lymphadenopathy. *Breast Cancer Research* [Internet]. 2011 Nov 4 [Cited 2024 Jun 9];13(1):P40. Available From: <https://doi.org/10.1186/bcr2992>
- [6] Akashi-Tanaka S, Fukutomi T, Miyakawa K, Uchiyama N, Nanasawa T, Tsuda H. Contrast-Enhanced Computed Tomography Detection Of Occult Breast Cancers Presenting As Axillary Masses. *Breast Cancer Res Treat*. 1999 May;55(1):97–101.
- [7] Lu H, Xu Yl, Zhang Sp, Lang Rg, Zee Cs, Liu Pf, Et Al. Breast Magnetic Resonance Imaging In Patients With Occult Breast Carcinoma: Evaluation On Feasibility And Correlation With Histopathological Findings. *Chin Med J (Engl)*. 2011 Jun;124(12):1790–5.
- [8] Olson Ja, Morris Ea, Zee Kvj, Linehan Dc, Borgen Pi. Magnetic Resonance Imaging Facilitates Breast Conservation For Occult Breast Cancer. *Ann Surg Oncol* [Internet]. 2000 Jul 1 [Cited 2024 Jun 9];7(6):411–5. Available From: <https://doi.org/10.1007/s10434-000-0411-4>
- [9] Knapper Wh. Management Of Occult Breast Cancer Presenting As An Axillary Metastasis. *Seminars In Surgical Oncology* [Internet]. 1991 [Cited 2024 Jun 9];7(5):311–3. Available From: <https://onlinelibrary.wiley.com/doi/abs/10.1002/ssu.2980070515>
- [10] Blanchard Dk, Farley Dr. Retrospective Study Of Women Presenting With Axillary Metastases From Occult Breast Carcinoma. *World Journal Of Surgery* [Internet]. 2004 [Cited 2024 Jun 9];28(6):535–9. Available From: <https://onlinelibrary.wiley.com/doi/abs/10.1007/s00268-004-7290-y>
- [11] Fancellu A, Mulas S, Cottu P, Cherchi A, Ermini Rl, Giuliani G, Et Al. Occult Breast Cancer Presenting As Axillary Lymph Node Metastases: A Single-Institution Experience With A Challenging Diagnostic And Therapeutic Dilemma. *European Journal Of Surgical Oncology* [Internet]. 2012 Oct 1 [Cited 2024 Jun 9];38(10):1005. Available From: [https://www.ejso.com/article/S0748-7983\(12\)01012-8/abstract](https://www.ejso.com/article/S0748-7983(12)01012-8/abstract)
- [12] Chen C, Orel Sg, Harris E, Schnall Md, Czerniecki Bj, Solin Lj. Outcome After Treatment Of Patients With Mammographically Occult, Magnetic Resonance Imaging—Detected Breast Cancer Presenting With Axillary Lymphadenopathy. *Clinical Breast Cancer* [Internet]. 2004 Apr 1 [Cited 2024 Jun 9];5(1):72–7. Available From: [https://www.clinical-breast-cancer.com/article/S1526-8209\(11\)70842-4/abstract](https://www.clinical-breast-cancer.com/article/S1526-8209(11)70842-4/abstract)
- [13] Lloyd Ms, Nash Ag. “Occult” Breast Cancer. *Ann R Coll Surg Engl*. 2001 Nov;83(6):420–4.
- [14] Bresser J De, Vos B De, Ent F Van Der, Hulswé K. Breast Mri In Clinically And Mammographically Occult Breast Cancer

- Presenting With An Axillary Metastasis: A Systematic Review. *European Journal Of Surgical Oncology* [Internet]. 2010 Feb 1 [Cited 2024 Jun 10];36(2):114–9. Available From: [https://www.ejso.com/article/S0748-7983\(09\)00468-5/fulltext](https://www.ejso.com/article/S0748-7983(09)00468-5/fulltext)
- [15] Kuerer Hm, Newman La, Smith Tl, Ames Fc, Hunt Kk, Dhingra K, Et Al. Clinical Course Of Breast Cancer Patients With Complete Pathologic Primary Tumor And Axillary Lymph Node Response To Doxorubicin-Based Neoadjuvant Chemotherapy. *J Clin Oncol*. 1999 Feb;17(2):460–9.
- [16] Cohen Bl, Collier Al, Kelly Kn, Goel N, Kesmodel Sb, Yakoub D, Et Al. Surgical Management Of The Axilla In Patients With Occult Breast Cancer (Ct0 N+) After Neoadjuvant Chemotherapy. *Ann Surg Oncol* [Internet]. 2020 Jun 1 [Cited 2024 Jun 10];27(6):1830–41. Available From: <https://doi.org/10.1245/s10434-020-08227-w>
- [17] He M, Tang Lc, Yu Kd, Cao Ay, Shen Zz, Shao Zm, Et Al. Treatment Outcomes And Unfavorable Prognostic Factors In Patients With Occult Breast Cancer. *European Journal Of Surgical Oncology* [Internet]. 2012 Nov 1 [Cited 2024 Jun 10];38(11):1022–8. Available From: [https://www.ejso.com/article/S0748-7983\(12\)01221-8/abstract](https://www.ejso.com/article/S0748-7983(12)01221-8/abstract)
- [18] Shannon C, Walsh G, Sapunar F, A’hern R, Smith I. Occult Primary Breast Carcinoma Presenting As Axillary Lymphadenopathy. *The Breast* [Internet]. 2002 Oct 1 [Cited 2024 Jun 10];11(5):414–8. Available From: [https://www.thebreastonline.com/article/S0960-9776\(02\)90455-8/abstract](https://www.thebreastonline.com/article/S0960-9776(02)90455-8/abstract)

## Appendix



**Figure 1: X-Ray View Of Right Side**



**Figure 2: X-Ray View Of Left Side**