

Ultrasonographic And Mri Diagnosis Of Rotator Cuff Pathologies

Dr. Nikunj Desai

(Professor At Radio-Diagnosis Department , Gcs Medical College, Hospital And Research Centre , Ahmedabad)

Dr. Dhruvin Doshi

(3rd Year Resident In Gcs Medical College, Ahmedabad)

Dr. Asutosh Dave

(Head Of Department At Radio-Diagnosis Department , Gcs Medical College, Hospital And Research Centre , Ahmedabad)

Dr. Radhi Sonpura

(3rd Year Resident In Gcs Medical College, Ahmedabad)

Dr. Kavisha Goswami

(3rd Year Resident In Gcs Medical College, Ahmedabad)

Dr. Harsh Prashnani

(3rd Year Resident In Gcs Medical College, Ahmedabad)

Dr. Krishn Nandania

(3rd Year Resident In Gcs Medical College, Ahmedabad)

Abstract :

Objective : to evaluate the role of effectiveness of ultrasonography and mr in diagnosis of rotator cuff pathologies

Patients & methods : this prospective study included 50 patients referred for ultrasound and mri because of shoulder pain. All patients were examined clinically, followed by radiography of the affected shoulder. High-resolution ultrasound examination of the involved shoulder was performed together with an examination of the contralateral normal shoulder, followed by mri of the symptomatic shoulder in all 50 patients.

Study type : prospective study

Results : in the present study, the majority of patients were in age group 25–65 years, 58 % were males and 42 % were females (of a total of 50 patients). On ultrasound, of 50 patients, 22 (44 %) patients had full-thickness tears, 17 (34%) partial-thickness tears, 10 (20 %) patients had tendinosis and 1 (2%) patient did not have any abnormality.

On mri conducted in 50 patients, 12 (24%) patients had partial-thickness tears, while 28 (56 %) patients had full-thickness tears, and 10 (20%) patients had tendinosis .

Conclusion : both mr and u/s are valid diagnostic modalities in detecting , characterizing & discriminating the rotator cuff disorders . U/s may have some challenges in few patients with rotator cuff pathologies , while mr provides accurate diagnosis even without contrast. A wide availability, cost effectiveness and better tolerability of ultrasonography make it a modality of first choice for evaluating rotator cuff tears .

Keywords : full thickness tear (ftt) , mri, partial thickness tear (ptt) , rotator cuff tear , u/s (usg) .

Date of Submission: 08-07-2024

Date of Acceptance: 18-07-2024

I. Introduction :

- Shoulder joint is such a unique and complicated joint of the body. It gives a great range of motion. The glenohumeral joint is a synovial joint, type of ball and socket joint. Due to large articular surface of

humeral head as compared to small articular surface of glenoid cavity, there is more chance of dislocation and subluxation. Joint stability is provided by rotator cuff muscles (supraspinatus, infraspinatus , teres minor and subscapularis) , long head of biceps, related bony process and extra capsular ligaments. Muscles of the rotator cuff helps to lift & rotate the head of humerus . (11,12)

- Depending on the pathophysiology of shoulder joint, it is divided into the two main type : (1) Primary rotator cuff disorders (Impingement syndrome or intrinsic tendinosis). (2) Secondary (consequences of glenohumeral instability) .
- Anteriorly unstable humeral head usually causes narrowing of coraco-acromial outlet, which is the cause for rotator cuff pathology . (13 , 17)
- U/S is inexpensive, fast, dynamic and easily accessible method for evaluation of tears. However glenoid rim fracture, labral tear & ligamental capsular injury is very well diagnosed by MRI. MRI has the superior ability to evaluate both internal structures & soft tissue surrounding the joint . (1,6)

II. Patients & Methods :

Our study include 50 patients (29 male and 21 female) with age ranging from 25 to 65 years, who complains of shoulder pain or/and limitation of its movement mainly abduction movement . The patient referred from orthopedic surgery & physiotherapy department for U/S & MRI scan . After U/S & MRI , the findings were analyzed and correlated with arthroscopic & orthopedic surgical findings. Patients with hemiplegia , neurological deficit or referred pain to shoulder due to some primary pathology somewhere else , excluded from the study.

Methods :

- Full clinical history
- Plain x-ray shoulder (A - P)
- Real time U / S

We used the high frequency superficial Hockey stick and high frequency linear probe . First examine the biceps tendon by resting patient's forearm in a supine position on his/her thigh . Next examine the subscapularis tendon by rotating the patients arm externally . Then supraspinatus tendon by extending patients arm posteriorly and placing the palmars side of the hand on posterior aspect of iliac wing with elbow flexed . Lastly the posterior shoulder was examined for posterior glenohumeral joint, infraspinatus and teres minor .

Mr Imaging:

MR examination was performed with 1.5 tesla , with phased array shoulder coil . Patient lying in supine position with arm in supine or slightly externally rotated and away from the chest .

Image Analysis:

- In tendinosis, U/S findings – Heterogeneous bulky tendon , while in MRI intact tendon with T2 & STIR high signal intensity .
- Partial thickness tear appeared as anechoic fluid filled defect in part of the tendon (in bursal side, articular side or in the substance of tendon) while on MRI there is focal disruption of tendon with T2 & STIR high signal intensity within .
- Full thickness tear on U/S appears as fluid filled defect in the whole tendon while in MRI there is complete disruption of the tendon from its superior to its inferior border with high signal intensity equal to T2W & T2WI with fat suppression with loss of convexity in one of them. MRI also detects the anterior, superior or posterior labral tear . AP value < 0.05 was considered significant .

III. Results:

This study included 50 patients (29 males & 21 females) with age ranging from 25 to 65 years . Patients were devided into further groups according to their final diagnosis through U/S & MR findings in correlation to arthroscopic and orthopedic surgical data .

Age incidence.

Sr.no	Agegroup (in years)	Number of patients	Percentage
1	<25	5	10
2	26-35	5	10
3	36-45	7	14
4	46-55	15	30
5	56-65	18	36
6	Total	50	100

Out of 50 patients, 29 were males (58%) and 21 (42%) were females Thus, the M: F ratio was 1.3: 1 . Our study found no statically significant differences in the prevalence of rotator cuff tears between genders , which correlates with the results of the study carried by **Milgrom et a**

Gender	Number of Patients	Percentage
Male	29	58%
Female	21	42%

Even a small pathology of shoulder joint is better evaluated by MRI . USG is powerful and accurate method for rotator cuff tears and other rotator cuff abnormality .

This study included 50 patients, divided into further groups according to their final diagnosis .

1. 28 patients with Complete tear .
2. 12 patients with partial tear .
3. 10 patients with Tendinosis .

In the present study, 35 patients (70%) had pain involving the right shoulder and 15 patients (30%) had pain involving the left shoulder . Thus , the right shoulder was more frequently involved than the left shoulder . This correlates with the results of the study by **Bouaziz et al.** who found right shoulder involvement (68%) to be more frequent than left shoulder involvement (32%) .

Pain Location	Number of Patients	Percentage
Right Shoulder	35	70%
left shoulder	15	30%

Tendon involved	Partial tear		Complete tear	
	USG	MRI	USG	MRI
Subscapularis	2	1	4	5
Supraspinatus	15	11	17	21
Infraspinatus	0	0	1	2
Teres minor	0	0	0	0
Total	17	12	22	28

During MRI scan , we also found some osseous abnormality associated with rotator cuff disorders. Out of 20 patients of rotator cuff disorder , 10 patients (50 %) were having AC joint hypertrophy which diagnosed equally by USG and MRI. 1 patient had downward sloping of acromian which could be diagnosed only by MRI examination .

An ultrasound examination revealed rotator cuff tears in 39 patients. Similar results were reported by **Brandt et al. Singiseti et al.** found that, in detection of supraspinatus tendon tears, ultrasonography attained sensitivity of 89% and specificity of 43%. For detection of subscapularis tendon tears , ultrasonography attained sensitivity of 30%. Sensitivity, specificity and predictive values were good in larger full-thickness tears but were significantly reduced in subcentimetre and partial-thickness tears, particularly those involving the tendon of the subscapularis muscle.

In the present study, MRI showed rotator cuff tears in 40 patients of whom 12 patients had partial-thickness tears and 28 patients had full-thickness tears. Similar results were reported by **McMonagle et a , Fischer et al.** showed that ultrasonography and MRI are comparable and ultrasound is beneficial in revision cases. In their study, accuracy of 91.1% was seen for detection of tears of the supraspinatus tendon, 84.4% for the infraspinatus tendon and 77.8% for the subscapularis tendon .

In the present study, in 6 (12%) cases bicep tendon sheath effusion was seen on usg examination, while on MRI 7 (14%) cases of bicep tendon sheath effusion were seen. Thus, USG and MRI showed a high agreement for detection of bicep tendon sheath effusion. Similar results were reported by **Alasaarela et al.** who reported effusion of bicep tendon sheath in 24 shoulders on MRI and in 20 patients on USG. They found a good agreement between USG and MRI for detection of effusion of the biceps tendon sheath. **Chen H et al.** examined 125 patients to compare physical examination with musculoskeletal ultrasound in diagnosing long head tendinitis and concluded that these tests were limited by poor sensitivity. US can be an image modality of choice in diagnosing biceps pathology .

IV. Discussion :

This study included 50 patients (29 males & 21 females) with age ranging from 45 to 65 years. Patients were divided into further groups according to their final diagnosis through U/S & MR findings in correlation to arthroscopic and orthopedic surgical data .

On ultrasound, of 50 patients, 22 (44 %) patients had full-thickness tears, 17 (34%) partial-thickness tears, 10 (20 %) patients had tendinosis and 1 (2%) patient did not have any abnormality .

Out of the 17 patients with partial-thickness tears, 10 patients showed hypoechoic defects that involved the articular surface and 7 patients showed hypoechoic defects that involved the bursal surface .

Out of 22 patients with full-thickness tears, 12 patients had tears without retraction and 10 patients had tears with retraction .

On MRI conducted in 50 patients, 12 (24 %) patients had partial-thickness tears, while 28 (56 %) patients had full-thickness tears, and 10 (20%) patients had tendinosis .

in 40 patients MRI showed rotator cuff tears. In 12 patients diagnosed with partial-thickness tears, 7 patients showed defects involving the articular surface and 5 patients had defects along the bursal surface. In 28 patients diagnosed with full-thickness tears, 12 patients had full-thickness tears without retraction and 16 patients had full-thickness tears with retraction .

Of 50 patients, in 4 (8%) patients the biceps tendon in the intertubercle sulcus was not visualised on usg and the same results were seen on MRI. In 13 out of 50 patients, biceps tendon effusion was seen in 6 patients (46%) on USG and in 7 patients (54%) on MRI .

Teres minor is a critical external rotator of the shoulder, accounting for up to 45% of external rotation power. Whether intact or hypertrophied, the teres minor can supply adequate force to external rotation and maintain the capacity to do daily activities like eating and drinking while also reducing the symptoms of the other cuff tendon tear .

USG and MRI both are successful imaging modality for both rotator cuff and non rotator cuff disorder & they give important role in management of rotator cuff pathologies. MRI of shoulder widely used for assessing the impingement and instability related clinical condition .

Rotator cuff tears are a frequent finding in patients with shoulder pain. Non-invasive imaging modalities such as ultrasonography and MRI are used for evaluating rotator cuff pathologies. USG can be used as a primary modality because its accuracy in detecting partial- and full-thickness rotator cuff tears is comparable to MRI, as mentioned in literature. Our data were analysed with the kappa values .

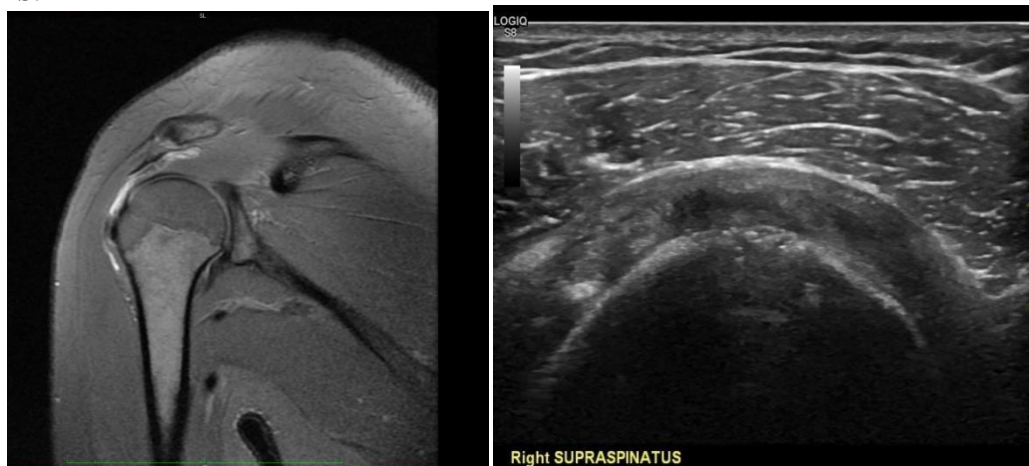V. Conclusion :

USG and MRI are the valid diagnostic modality for detecting, evaluating and characterizing the rotator cuff disorder with no significant comparable difference. USG is ideal for screening tool, as it is cheap, non invasive, rapid , dynamic assessment, widely available and ideal for the patients who are unsuitable for MRI examination .

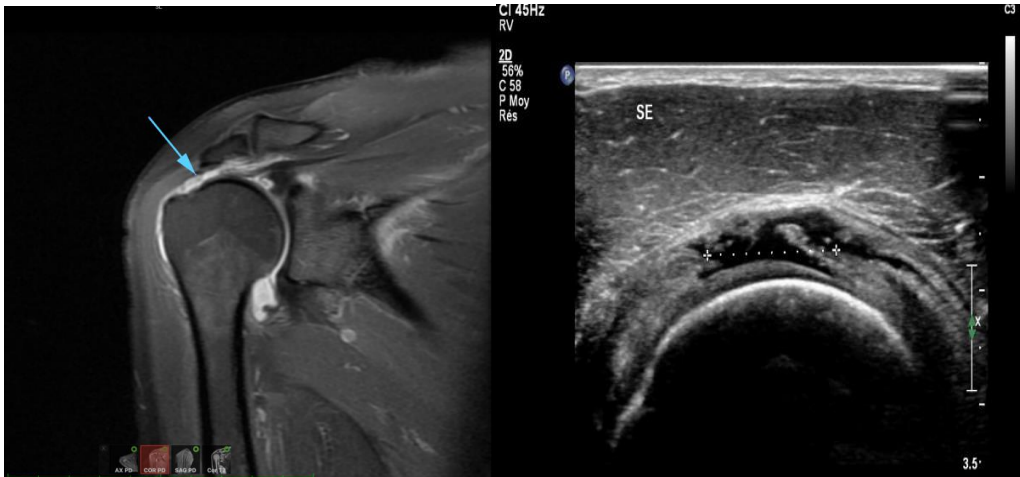
MR is indicated when there is an abnormality related to labrum, articular cartilage, bone marrow or deep soft tissue. In shoulder instability USG has many challenges while MR provides accurate diagnosis even without contrast .

Conflicts of interest : none

IMAGES:

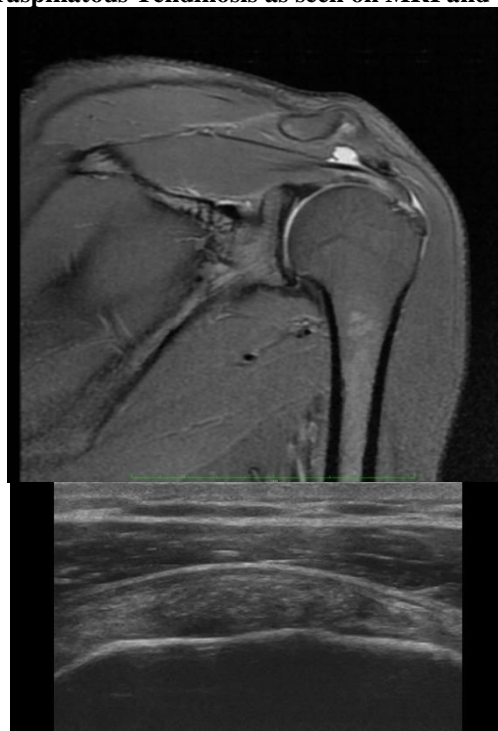

Partial thickness tear in supraspinatus tendon as seen on MRI and USG .



Full thickness tear in supraspinatus tendon as seen on MRI and USG .

Supraspinatous Tendinosis as seen on MRI and USG .



Hill sach's defect (Due to recurrent anterior dislocation) as seen on MRI .

