

An Varied Presentations & Early Diagnosis of Gallbladder Cancer in Indian Setup: A Case Series and Literature Review

Dr.Dewat Ram Nakipuria

Associate Prof Department of General Surgery, Sharda School of
Medical Sciences & Research, Greater Noida-201310,UP

Dr.Jappan Singh Jot

PG Resident , Department of General
Surgery, Sharda School of Medical
Sciences & Research, Greater Noida-201310, Uttar Pradesh

Dr.Dewat Ram Nakipuria

Associate Professor, Department of
General Surgery, Sharda School of
Medical Sciences & Research, Greater Noida-201310, Uttar Pradesh

Dr. Vikram Singh Chauhan

Prof & Head, Department of General
Surgery, Sharda School of Medical Sciences & Research, Greater Noida
201310, Uttar Pradesh

ABSTRACT

Background: Gallbladder cancer was first described in 1777^[1]. But even after 247 years later, late diagnosis and absence of effective treatment for many patients remain typical feature of this disease^[2]. Although it is rare disease, with annual incidence estimated to be 1 to 2 per 100,000^[3], with approximately 2500 annual deaths in a country like India^[4]. Gallbladder cancer is a highly aggressive malignancy with a low survival rate. Almost all cases are diagnosed at an advanced stage beyond when surgical cure is impossible. Gallbladder cancer mimics or coexists with gallstone disease and is often missed. 50% of gallbladder carcinoma is diagnosed intraoperatively. **Aims & Objective:** So early diagnosis including strict scrutiny of such symptomatic patients is essential for decreasing the morbidity and mortality of gallbladder cancer^[5]. **Material & Method:** This Case series includes a retrospective study among Seven patients in our tertiary care hospital & Medical College. Carcinoma of Gall Bladder was either suspected on imaging or incidentally diagnosed intra-operatively or post operatively by histopathology report of cholecystectomy specimen. All Seven patients underwent lap or open cholecystectomy. 6 patients were diagnosed post operatively by histopathology report, whereas One patient with no records of previous cholecystectomy was diagnosed on USG guided biopsy from the liver mass. All patients had a stage of < T2N1M1. All patients presented with either pain right upper abdomen, right hypochondrium mass, deep jaundice or ascites.

Conclusion: Our case series underscores the importance of vigilance for presentations of gallbladder cancer, especially in younger patients and highlights the diagnostic challenges posed by its varied clinical manifestations. Understanding such nuances is crucial for early detection and optimal management of this aggressive malignancy to reduce high morbidity and mortality associated with it.

Key Words: Gall Bladder, Gall Bladder Carcinoma, Metastases, Early Diagnosis, Cholecystectomy

Date of Submission: 09-06-2024

Date of Acceptance: 21-06-2024

I. INTRODUCTION:

Cancer of Gall bladder is a rare malignancy that occurs predominantly in the elderly. Being an aggressive tumour, the 5 year survival rate is as low as 5%^[6]. In the Indian Subcontinent, although rare it is still the commonest hepato-biliary malignancy, Northern India is the most affected region. Among women it is the commonest gastrointestinal malignancy. It is usually diagnosed late and is aggressive with 50% of carcinoma gall bladder cases being unresectable at diagnosis. Gallstones are the most important risk factor, and up to 95% of

patients with gall bladder cancer have gallstones [7]. Chronic Inflammation following cholelithiasis is the main predisposing factor for malignancy. Larger stones (>3 cm) are associated with a 10 fold higher risk of cancer [8]. The risk of gall bladder cancer is higher in patients with symptomatic than asymptomatic gallstones. Signs and symptoms of carcinoma of gallbladder are generally indistinguishable from those associated with cholecystitis and cholelithiasis as jaundice, weight loss, anorexia, ascites and abdominal mass. The other precancerous lesions include porcelain gallbladder, sclerosing cholangitis, anomalous pancreaticobiliary junction and exposure to carcinogens (nitrosamines, azotoluene). More than half of gallbladder cancers are not diagnosed before cholecystectomy.

II. AIMS & OBJECTIVE:

This case series aims to report our experience with Carcinoma Gallbladder in our tertiary care hospital, Sharda School of Medical Sciences & Research. This study was a retrospective study on seven Patients in this tertiary care centre from February 2024 to April 2024. As a reference, this hospital performed 200 cholecystectomies between February 2024 and April 2024. Carcinoma Gall Bladder was either suspected on imaging or incidentally diagnosed intra-operatively or post operatively by histopathology report of cholecystectomy specimen.

Detecting gallbladder carcinoma in its early stages can be difficult, despite improvements in ultrasound and computed tomography (CT) imaging. Most diagnoses of Gallbladder cancer are made at advanced stages, with the majority being found incidentally during surgery for cholelithiasis. The presented case series demonstrates the varied presentations of CA gallbladder and importance of diagnosing Gallbladder malignancy at an early stage.

CASE SERIES : For Following seven Patients

Case 1

The first case was a 50 year old hypertensive and diabetic male with a history of gastroesophageal reflux disease who presented with 2-months history of upper abdominal pain and weight loss. On examination : P/A: Inspection: scaphoid, no visible veins or stretch marks, umbilicus centrally placed, inverted. Palpation: soft, nontender, non-distended, no palpable lump. An ultrasound of the whole abdomen revealed cholelithiasis (few calculi, largest-19mm), CBD -4mm, grade I fatty liver with mild hepatomegaly. The patient underwent laparoscopic cholecystectomy. Intra op findings: GB thick and distended, oedematous, enlarged to about 8 inches with dense adhesions to the duodenum and dense omental fat. Excised gallbladder was sent for histopathological examination which revealed differentiated adenocarcinoma of gallbladder

.Case 2

The next patient was a 65 year old hypertensive female who presented with on-off episodes of right side upper abdominal pain since 2 years with loss of appetite and weight loss with history of jaundice 2 months managed by quack. On examination : P/A: Inspection: scaphoid, no visible veins or stretch marks, umbilicus centrally placed, inverted

Palpation: soft, nontender, non-distended, no palpable lump. An ultrasound of the whole abdomen revealed cholelithiasis (single 15mm calculi), CBD -3mm. The patient underwent open cholecystectomy. Intra op findings: gb embedded in the liver bed, gb wall thickened, stomach densely adhered to gb body, frozen calots anatomy post op period was uneventful. Excised gallbladder was sent for histopathological examination which revealed moderately differentiated adenocarcinoma of gallbladder, biliary type. post operatively due to high suspicion of CA gb CA19.9 was sent which was 168.86U/mL (reference levels:0 – 37 U/mL)

Case 3

59 year old female who presented with on-off episodes of right side upper abdominal pain since 6 months with loss of appetite and weight loss with history of passage of dark coloured urine and deep progressive jaundice since 2 months. Past history of open cholecystectomy done 2 years ago following which she never went for a follow up for HPE and no documents available for the mentioned surgery. On examination : P/A: Inspection: protuberant, no visible veins or stretch marks, umbilicus centrally placed, inverted. Palpation: soft, nontender, non-distended, 6x4cm lump is palpable in the right hypochondrium in the mid clavicular line 4cm below the right subcostal margin moving with respiration. BT on admission – 25.60mg/dl, direct -22.72 mg/dl. An ultrasound of the whole abdomen revealed hypoechoic lesion in the right lobe of the liver. CECT was done which showed possibility of residual CA gb, MRCP revealed metastasis to the liver parenchyma, obstructive intra hepatic biliary dilatation. usg guided biopsy was taken from segment V of the liver which proved to be metastatic adenocarcinoma. PTBD couldn't be done due to monetary constraints. The patient underwent open cholecystectomy. Intra op findings: gb embedded in the liver bed, gb wall thickened, stomach densely adhered to gb body, frozen calots anatomy post op period was uneventful. Excised gallbladder was sent for

histopathological examination which revealed moderately differentiated adenocarcinoma of gallbladder , biliary type . post operatively due to high suspicion of CA gb CA19.9 was sent which was 168.86U/mL (reference levels:0 – 37 U/mL) .

Case 4

The next patient was a 48 year old diabetic female who presented with on –off episodes of right side upper abdominal pain since 1 month with generalized body weakness and multiple episodes of nonbilious vomiting . on examination : P/A: Inspection: scaphoid , no visible veins or stretch marks, umbilicus centrally placed, inverted

Palpation: soft , nontender , non distended , no palpable lump . An ultrasound of the whole abdomen revealed cholelithiasis (single 15mm calculi) ,CBD -6mm.The patient underwent laparoscopic cholecystectomy .Intra op findings : dense omental adhesions with the gall bladder ,normal calots anatomy , multiple small stones ,distended gall bladder.Post op period was uneventful.Excised gallbladder was sent for histopathological examination which revealed low grade biliary intraepithelial neoplasia . post operatively due to high suspicion of CA GB.CA19.9 was sent which was WNL 10.63U/mL (reference levels:0 – 37 U/mL) and CA-125 -11.40 (reference levels : 0-35 U/mL) .

Case 5

The next patient was a 65 year old hypothyroid female who presented with on –off episodes of right side upper abdominal pain since 1 years with LG fever since 7days and dyspepsia since 6months . on examination : P/A: Inspection: scaphoid , no visible veins or stretch marksumbilicus centrally placed, inverted.Palpation: soft ,nontender,non distended ,no palpable lump .An ultrasound of the whole abdomen revealed cholelithiasis (single 20mm calculi) ,CBD -4.4mm.The patient underwent laparoscopic cholecystectomy .Intra op findings : large distended gall bladder elongated gall bladder with grade 4 adhesions to omentum with liver and GB ,multiple diffuse pearly white lesions ,rounded to hemispherical in shape on under surface of diaphragm 6x5cm pearly white diffuse lesions seen on omental surface.Other areas of the wall has similar pearly white eruptions of varying sizes .Excised gallbladder along with pearly white lesions on the undersurface of the diaphragm were sent for histopathological examination which revealed moderately differentiated adenocarcinoma of gallbladder metastatic deposits on the undersurface of the diaphragm respectively.Post operatively PET scan was done .

Case 6

The next patient was 16 year old male child who presented with on & off episodes of right side upper abdominal pain since 4 years with no h/o loss of appetite,weight loss,jaundice .On examination : P/A: Inspection: scaphoi,no visible veins or stretch marks,umbilicus centrally placed,inverted.Palpation: soft ,nontender,non distended ,no palpable lump . An ultrasound of the whole abdomen revealed cholelithiasis (single 13mm calculi) ,CBD -3mm .The patient underwent laparoscopic cholecystectomy.Intra op findings : minimal omental adhesions,calots triangle anatomy normal,CVS ascertain ned,distended gall bladder,elongated gall bladder.Excised gallbladder was sent for histopathological examination which revealed low grade biliary intraepithelial neoplasia with focal cholesterosis .

Case 7

A 44-year-old woman with a history of progressively worsening abdominal distension and dyspnoea over the past two months. Past h/o laparoscopic cholecystectomy eight months earlier for cholelithiasis. At that time, ultrasound examination revealed multiple gallstones, the largest measuring 10mm, normal GB wall thickness . The surgical procedure was uneventful, with mild omental adhesions noted and normal Calot's anatomy. She did no subsequent follow-up post-surgery . Tracing her HPE it was revealed that excised sample was showing s/o adenocarcinoma of GB . Patient started developing symptoms after six months post-surgery, prompting her to seek treatment from local practitioner, which proved ineffective. Currently she exhibited no weight loss, appetite changes, or jaundice. P/A: Inspection: Distended, no visible veins or stretch marks, umbilicus centrally placed, everted. Palpation: Abdominal palpation revealed gross ascites without shifting dullness or palpable masses, although small nodules (2-2.5cm) were palpable in the right iliac fossa and lumbar region.

Table 1: Clinical features of 7 cases of CA Gall Bladder

No.	Age/sex	fever	Right upper quadrant pain	Jaundice	Abdominal mass	Weight loss	Ascites	Edema	comorbidity
1.	50y/male	No	yes	No	No	Yes	No	No	HTN , T2DM
2.	65y/female	No	yes	Yes	No	Yes	No	No	HTN
3.	59y/female	No	yes	Yes	Yes	Yes	No	Yes	-
4.	48y/female	No	yes	No	No	No	No	No	T2DM
5.	65y/female	Yes	Yes	No	No	No	No	No	Hypothyroid
6.	16y/male	No	Yes	No	No	No	No	No	-
7.	44y/female	No	Yes	No	No	Yes	Yes	Yes	

Investigation: Vital signs upon presentation of all the seven patients were within normal limits. They were conscious, alert, and oriented.

Laboratory tests are shown in table 2

USG whole abdomen of majority of the patients showed nothing much significant except for features of cholelithiasis i.e. multiple calculi in the lumen of the gallbladder. However USG of 3rd patient was significant it showed hypoechoic lesion in the right lobe of the liver, gross central and peripheral IHBR dilatation, mild hepatomegaly. Usg of 7th patient showed gross ascites with thick internal septations, b/l gross pleural effusion, 60-70cc collection in the GB fossa.

CECT whole abdomen was done in patients 3rd and 7th. cect of 3rd patient : hepatomegaly with a large heterogeneously enhancing mass lesion with its epicentre in the GB fossa with extensions, lymphadenopathy and bilobar intrahepatic biliary radicles along with a similar lesion in segment 8 of right lobe of the liver likely residual carcinoma of gallbladder (Fig. 1a)

Cect whole abdomen of 7th patient : A large, hypodense, multiloculated, multiseptated lesion in the peritoneal cavity with multiple enhancing septa s/o neoplastic etiology. (Fig. 1b)

Histopathology report of 5 patients i.e 1st, 2nd, 3rd, 5th and 7th showed low to moderately differentiated adenocarcinoma of the gallbladder (Fig 2a, 2b). However, histopathology report of the 4th and 6th patient showed biliary intraepithelial neoplasia (Fig. 2c).

Tumour markers were sent post operatively in patients 2nd, 3rd and 4th, which is as follows :-

TUMOUR MARKER	PATIENT 2	PATIENT 3	PATIENT 4
CA-19.9 (0-37U/mL)	168.86	47.64	10.63
CA-125 (0-35U/mL)	13.30	-	11.40
CEA (0-2.5ng/mL)	2.08	27.06	-

Table 2: Blood Investigations :---

Investigations	Pt.1	Pt.2	Pt.3	Pt.4	Pt.5	Pt.6	Pt.7
Hb	14	11.80	11.30	13.2	12.70	12.30	8.9
Total Leucocyte Count	9.26	7.90	11.65	8.50	13.60	5.00	10.2
Haematocrit	46.50	36.60	36.70	43.9	42.30	40.90	24
Platelet	316	385	382	368	181	242	121
Bilirubin Total	0.78	1.81	25.60	0.72	0.39	0.61	0.80
Bilirubin Direct	0.25	1.22	22.72	0.19	0.13	0.13	0.61
Bilirubin Indirect	0.53	0.59	2.88	0.53	0.26	0.48	0.19
SGOT	25	291	52.80	33.50	42.50	34.10	91
SGPT	26	299	36	24	43	31	76

An Varied Presentations & Early Diagnosis of Gallbladder Cancer in Indian Setup: A Case ..

Alkaline Phosphatase	112	433	414	96	130	225	80
Urea	30.60	20.20	18.40	19.20	33.40	20.50	19
Creatinine	0.70	0.70	0.40	0.60	0.60	0.60	0.5
Potassium	4.70	3.60	3.20	4.20	4.10	4.50	3.8
Sodium	140	137	137	138	136	138	142
Chloride	100	102	102	104	103	100	104
Prothrombin Time	15.9	15	19.1	14.8	14.0	15.6	15.2
INR Value	1.12	1.00	2.1	1.00	1.1	1.2	1.16

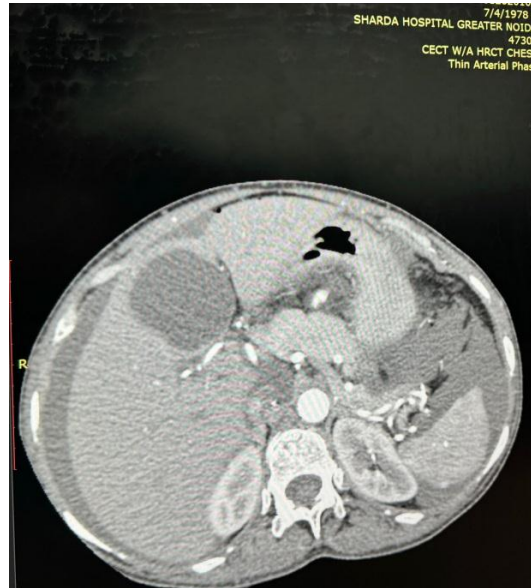


Fig.1a Ct Scan showing Carcinoma Gall Bladder

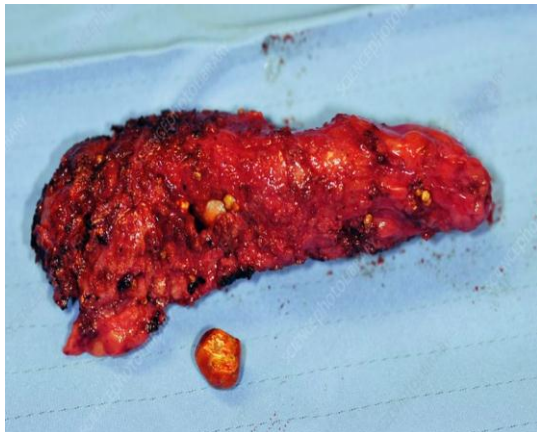

Fig. Excised Carcinomatous GB

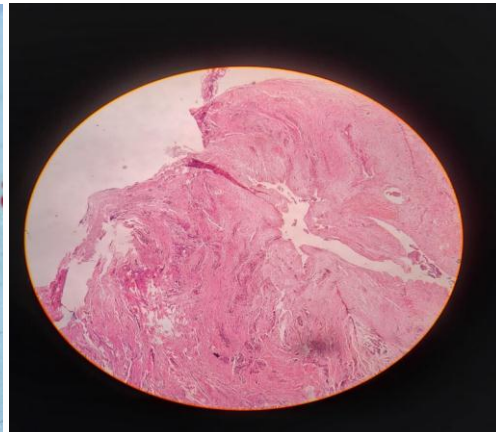


Fig. 2b Histopathologically CA GB

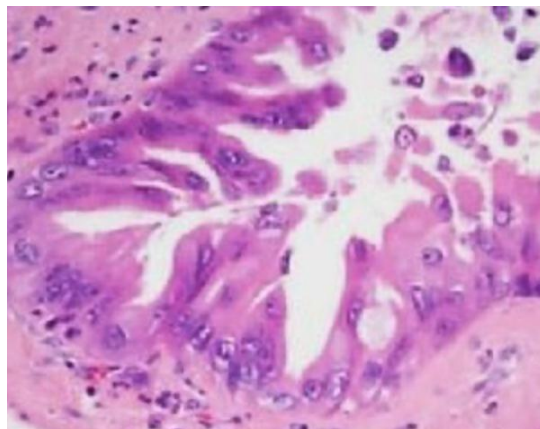


Fig. 2c Microscopic CA Gall Bladder

Treatment :

Laparoscopic cholecystectomy was done in all the patients except for 2nd patient who underwent open cholecystectomy due to frozen calots triangle anatomy, as there was no preoperative diagnosis of CA gall bladder, it was only post operatively that the HPE report revealed it to be malignant .In 3rd patient who did not have any records of previous surgery , USG guided biopsy from the segment V of the liver was taken which showed metastatic deposits from adenocarcinoma of the gallbladder . In the same patient , MRCP was done which showed obstructive intrahepatic biliary dilatation , PTBD was advised but pt. refused due to monetary constraints . Further management of any these patients could not be done due to unavailability of oncosurgeon and oncologist in the present center . in 7th patient given the suspicion of a neoplastic etiology based on contrast-enhanced computed tomography (CECT) findings of peritoneal deposits, an excisional biopsy(Fig.3a , 3b) of these deposits was performed under local anesthesia. Histopathological examination confirmed metastatic deposits from gallbladder cancer, thus solidifying the diagnosis.

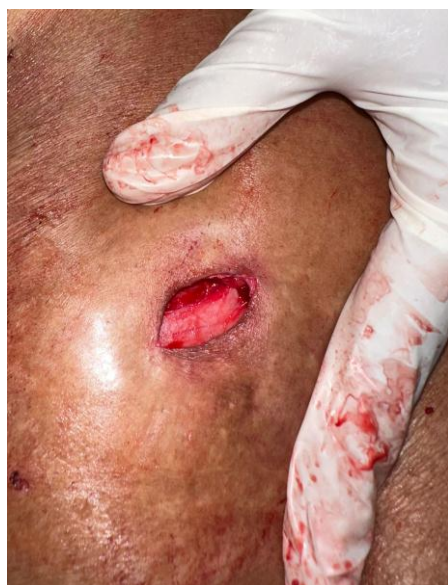

Fig.3a Metastatic Deposit

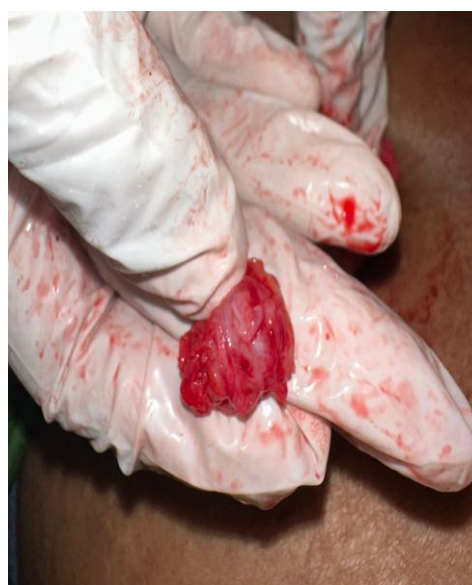

Fig.3b :Excised Tissue +ve for CA

Outcome and Follow up :

All the patient laparoscopic /open cholecystectomy , intraoperatively except for 1 patient, calots triangle dissection was not difficult, Post operatively on histopathological examination they were diagnosed with CA gall bladder, hence were referred to oncosurgery centre for radical management . Currently 2 of the patients are on chemotherapy from a tertiary care center. (Gemcitabine, Cisplatin ,5 –FU) .

III. DISCUSSION:

Gallbladder cancer typically manifests at an advanced stage, contributing to its dismal 5-year survival rate of 3-5%. The asymptomatic nature of the disease often leads to late diagnosis, with symptomatic patients displaying dyspepsia or biliary colic. Since early Gallbladder cancer mimics or coexists with gallstones, swift detection of early malignancy is a difficult task and that too in a country like India where patients are ignorant and present late (Hsing Aw et al , 2007)^[8] . Symptoms early in the disease process can also be vague, often leading to a delay in diagnosis . Hence screening for such patients will be essential in prolonging the survival of patients The commonest symptom of gallbladder cancer is right upper abdominal pain. Other warning signs include weight loss, anorexia, nausea and/or vomiting, jaundice, and itching (Lohe F et al ,2009)^[9]. Routine serum tests are non-diagnostic and do not significantly improve the identification of Gallbladder cancer preoperatively (Ritts Re Jr et al , 1994)^[10] . Serum tumor markers, carcinoembryonic antigen (CEA), and carbohydrate antigen 19-9 (CA 19-9) are frequently elevated in patients with Gallbladder cancer, but are not useful in its diagnosis because of their lack of sensitivity and specificity (Wibbenmeyer La et al,1995)^[11] .

Ultrasound and CT has greatly improved preoperative diagnosis of Gallbladder cancer. Patients who present with symptomatic gallstone disease are subjected to ultrasound as an initial study. The most common ultrasound findings include calcified and echogenic mucosal masses, which can be associated with cholelithiasis or porcelain gallbladder (Kumar A et al ,1994)^[12] .The most useful, non-invasive imaging studies for evaluating Gallbladder cancer preoperatively include CT, magnetic resonance imaging (MRI),and/or magnetic resonance cholangiopancreatography (MRCP).CT has been shown to be useful in defining the extent of GBC and in determining the resectability in advanced stages (Kumar A et al)^[12] .MRI and MRCP have also been shown to be useful in preoperative staging of GBC with a high sensitivity in identifying hepatic invasion and lymph node metastasis.

Regarding our seven patients, the first patient had two risk factors that predisposed him to gallbladder carcinoma. These included age and GERD likely due to H.pylori .This patient presented with RUQ pain since 2 months as well as an unintentional 15 kg weight loss. Ultrasound revealed a distended gallbladder and multiple gall stones largest measuring 19 mm . uneventful lap cholecystectomy was done .Histopathology of this patient came back as adenocarcinoma .Our next patient had five risk factors these included female gender, age > 60 ,diabetes mellitus, cholelithiasis and obesity.This patient presented with on – off episodes of right upper abdominal pain for 2 years,she underwent lap converted to open cholecystectomy due to frozen calots anatomy.This patient was incidentally found to have adenocarcinoma on histopathology Our third patient was outside post operated case of open cholecystectomy done 2years bac , he lost in follow up and presented to us later with deep progressive jaundice .Her USG guided biopsy from the liver mass revealed metastatic deposits from the adenocarcinoma of the gallbladder .Our fourth patient was also a female,48 years of age ,with cholelithiasis and acute cholecystitis. She presented with epigastric abdominal pain.underwent lap cholecystectomy and incidently diagnosed adenocarcinoma of GB on histopathology report.Our fifth patient was a 65year old hypothyroid female which presented with on-off episodes of right upper abdominal pain with dyspepsia.she was also diagnosed with CA gb post operatively on histopathological examination . our sixth case was an usual presentation in a 16 year old male child who presented with chronic cholecystitis and diagnosed as adenocarcinoma post operatively on histopathological examination . our seventh case was also an unusual presentation in a 48 year old female patient who after 8 months of cholecystectomy presented to us with gross ascites,she had peritoneal deposits,biopsy under LA was taken which revealed metastatic deposits of the adenocarcinoma of gall bladder .

IV. CONCLUSION:

Our cases illustrate the importance of preoperative,early-stage Gallbladder cancer diagnosis.Given that early detection is important in both decreasing the morbidity and mortality of Gallbladder cancer,with potential for surgical cure in cases limited to the gallbladder,patients with RUQ ultrasound findings such as gallstones or polyps should be offered surgical consultation.Diagnosis of gall bladder in its early stage reduces the morbidity and thereby the patient can be offered curative surgery . Further,consideration of Gallbladder cancer within the differential diagnosis by primary care physicians,radiologists and surgeons may serve to maximize discovery before the time of surgery.Whether early detecting carcinoma of gall bladder improves morbidity and mortality free survival is yet to be observed.

REFERENCES:

- [1]. Nevin J E. Carcinoma of the gallbladder . Cancer 1976; 37 : 141-148
- [2]. Lazano-pounce E C , Miquel J F , Munoz N , Herrero R , Ferruccio C , Wistuba . Epidemiology and molecular pathology of the gall bladder cancer . CA cancer J Clin 2001 ; 51 (6) : 349-64
- [3]. Fong Y , Malhotra s . Gall bladder cancer : recent advances and current guidelines for surgical therapy . Adv Surg 2001 ; 35 : 1-20 .
- [4]. Carriage M T , Henson D E . Liver , gall bladder , extra hepatic bile ducts , and pancreas . Cancer . 1995 ; 75 : 171-90 .

- [5]. Dr.Kavin Sugumar. "Early Diagnosis of Carcinoma Gall Bladder - A Case Series." IOSR Journal of Dental and Medical Sciences (IOSR-JDMS) 16.10 (2017): 74-76
- [6]. Grobmyer SR, Lieberman MD, Daly JM .Gallbladder cancer in the twentieth century: single institutions experience. World J Surg. 2004;28:47.
- [7]. Pandey M Shukla VK.Diet and gallbladder cancer : a case- control study. Eur J Cancer Prev. 2002 ;11:365
- [8]. Gallstones and the risk of biliary tract cancer: a population-based study in China. Hsing AW, Gao YT, Han TQ, Rashid A, Sakoda LC, Wang BS, Shen MC, Zhang BH, Niwa S, Chen J,Fraumeni JF Jr . Br J Cancer. 2007 Dec 3; 97(11):1577-82
- [9]. The time of diagnosis impacts surgical management but not the outcome of patients with gallbladder carcinoma. Löhe F, Meimarakis G, Schauer C, Angele M, Jauch KW, Schauer RJ Eur J Med Res. 2009 Aug 12; 14(8):345-51.
- [10]. Comparison of preoperative serum CA19-9 levels with results of diagnostic imaging modalities in patients undergoing laparotomy for suspected pancreatic or gallbladder disease. Ritts RE Jr, Nagorney DM, Jacobsen DJ, Talbot RW, Zurawski VR Jr Pancreas. 1994 Nov; 9(6):707-16.
- [11]. Sonographic diagnosis of unsuspected gallbladder cancer: imaging findings in comparison with benign gallbladder conditions. Wibbenmeyer LA, Sharafuddin MJ, Wolverson MK, Heiberg EV, Wade TP, Shields JB .AJR Am J Roentgenol. 1995 Nov; 165(5):1169-74.
- [12]. Carcinoma of the gallbladder: CT findings in 50 cases. Kumar A, Aggarwal SAbdom Imaging. 1994 Jul-Aug; 19(4):304-8.