

Choroidal Melanoma Due To Ocular Melanocytosis

Z.HAMMOUMI ; S. ENNAKI ; Z. LAFTIMI ; G.DAGHOUI ; L.
ELMAALOUM ; B. ALLALI ; A. EL KETTANI
OPHTHALMOLOGY DEPARTMENT, HOSPITAL 20 AUGUST 1953
CASABLANCA - MOROCCO

Abstract

Melanomas are the most frequent primary malignant tumors of the eye. The oncogenesis of melanomas is not well understood. Ocular melanocytosis and oculopalpebral nevus (Ota nevus) are definite risk factors. We report the case of a choroidal melanoma in a 62 year old patient with ocular melanocytosis and oculopalpebral nevus. She presented for a rapidly progressive loss of vision in her left eye (OS). The patient has been experiencing temporal visual field loss with phosphene and myodesopsias for the past 4 months, which has complicated into rapidly progressive vision decline (OS). Fundus examination OD was normal. Fundus examination OS demonstrated an achromatic elevated choroidal tumor associated with a total retinal detachment. The patient underwent enucleation OS. Ocular melanocytosis is a known predisposing factor for both unifocal and multifocal melanomas. Lifelong monitoring for uveal melanomas must be done in all patients with ocular melanocytosis. The risk of developing uveal melanoma increases gradually after the first decade of life. Also patients with uveal melanoma arising from ocular melanocytosis are at increased risk for metastasis.

Keywords : Melanoma – Malignant tumor – Ocular melanocytosis – Metastasis.

Date of Submission: 28-05-2024

Date of Acceptance: 08-06-2024

I. Introduction :

Melanomas are the most frequent primary malignant tumors of the eye.(1)

The oncogenesis of melanomas is not well understood and the role of potential endogenous or exogenous risk factors is poorly elucidated. Some melanomas likely arise from a malignant transformation of pre-existing nevi, but the majority of them are formed de novo.(2)

Ocular melanocytosis and oculopalpebral nevus (Ota nevus) are definite risk factors, and there is substantial evidence supporting the involvement of ultraviolet (UV) rays in the formation of these tumors.(2) We report the case of a choroidal melanoma in a 62 year old patient with ocular melanocytosis.

Observation :

Mrs F.N, 62 years old woman with left ocular melanocytosis (Figure1) and oculopalpebral nevus (Figure 2) presented for a rapidly progressive loss of vision in her left eye (OS). The patient has been experiencing temporal visual field loss with phosphene and myodesopsias for the past 4 months, which has complicated into rapidly progressive vision decline (OS). There was no other significant medical or family history.

On presentation, visual acuity was 6/10 in the right eye (OD) and « hand motion » OS.

The anterior segment examination was unremarkable OD while the left eye showed scleral melanocytosis.

Fundus examination OD was normal. Fundus examination OS demonstrated an achromatic elevated choroidal tumor associated with a total retinal detachment.

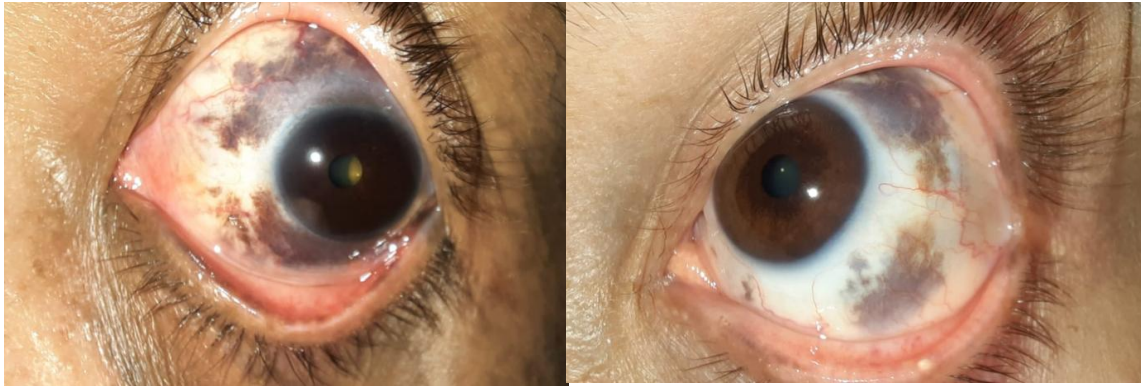


Figure 1 : Photographs showing ocular melanocytosis OS

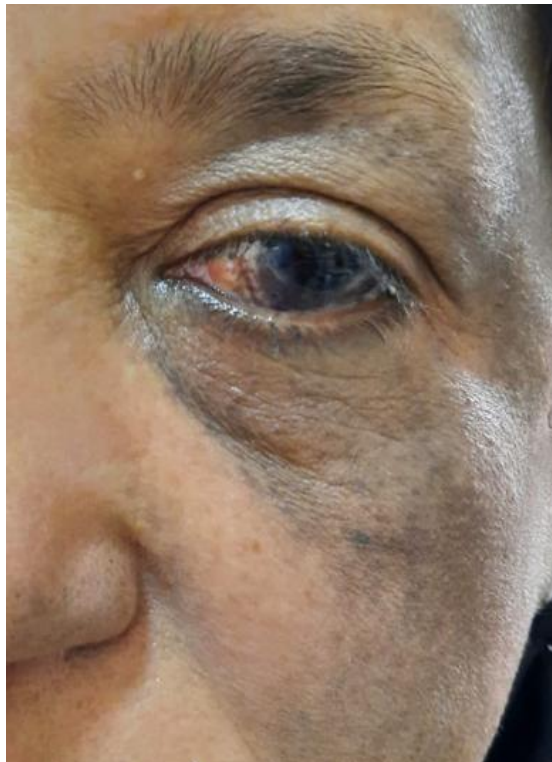

Figure 2 : Photograph showing oculopalpebral nevus OS

B-scan ultrasonography revealed a parietal echogenic process with moderate reflectivity measuring 16.88 mm in thickness with the sign of choroidal excavation present, a satellite retinal detachment and without extrascleral extension. (Figure 3)

Fluorescein angiography showed uneven filling with the presence of multiple pinpoint leaks.

A systemic evaluation was performed with cranio-orbital MRI, a PET scan, imaging of the chest and abdomen and blood tests revealed no evidence of any other primary or secondary malignancy. The findings were consistent with unilateral primary choroidal melanoma of the left eye.

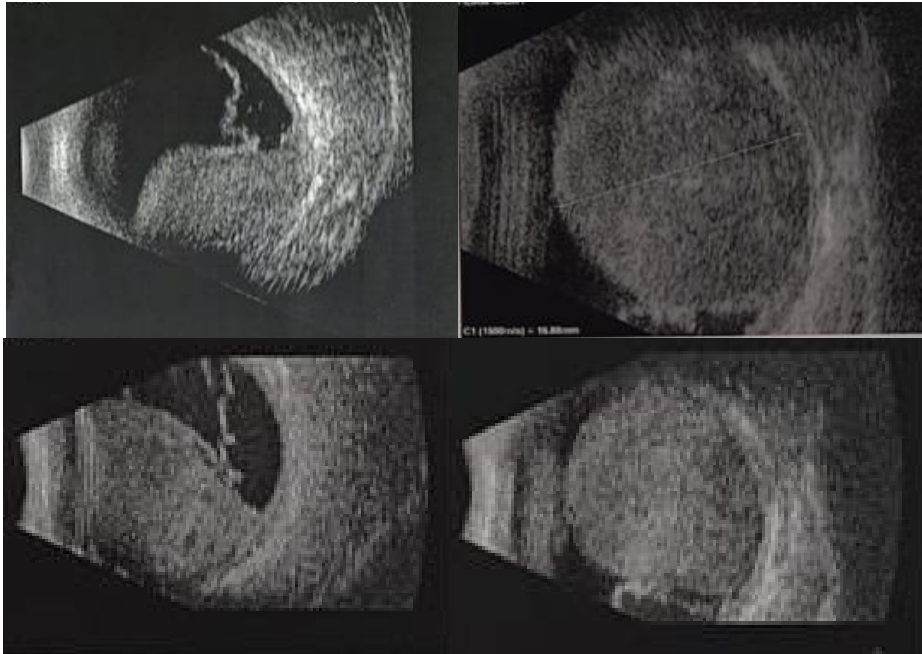


Figure 3 : B-scan ultrasonography showing a parietal echogenic process with moderate reflectivity measuring 16.88 mm in thickness with the sign of choroidal excavation present, a satellite retinal detachment and without extrascleral extension

The patient ultimately underwent enucleation OS after appropriate informed consent.

There was no evidence of orbital recurrence or systemic metastasis 13 months after the enucleation. A close follow up is still performed.

II. Discussion :

Ocular melanocytosis refers to an increase in the number of melanocytes, displaying histopathological characteristics similar to those of nevus cells, within all ocular structures: sclera, episclera, iris, ciliary body, choroid, and sometimes the optic disc.

On the sclera, it manifests as slate-colored patches often merging together; the choroid appears dark, hindering transillumination of the eyeball, and typically, the condition is unilateral, resulting in iris heterochromia.

In cases of oculopalpebral melanocytosis (Ota nevus), there is also skin hyperpigmentation extending into the territories innervated by the first and second branches of the trigeminal nerve.

The main complications of this condition include glaucoma (10% of cases) and uveal and choroidal melanoma. The risk of developing uveal melanoma on ocular melanocytosis has been estimated to be 35 to 50% higher than in the normal population(3). Choroidal melanoma can arise from a preexisting choroidal nevus(4) and sometimes ocular melanocytosis can be subtle and sectoral, often difficult to visualize. This require regular monitoring of these patients which involves fundoscopy to detect early signs of melanoma, along with OCT and enhanced depth imaging to assess choroidal thickness.

Melanomas are most often diffusely pigmented and have a greenish-brown coloration. However, they can also be partially pigmented and, more rarely, entirely unpigmented as is the case with our patient. In such cases, they must be distinguished from metastatic tumors(5).

Moreover, various melanocytic tumors, including choroidal melanoma and ciliary body melanocytoma, have been reported to occur in a single eye with ocular melanocytosis. Hence, individuals with ocular or oculodermal melanocytosis are susceptible to developing both benign and malignant ocular tumors(6,7).

Isolated choroidal melanocytosis seems to represent a limited form of ocular melanocytosis, increasing the risk of uveal melanoma and multifocal melanoma, thus requiring regular ophthalmic assessment. Ocular melanocytosis can be subtle and sectoral, often difficult to visualize(8).

Patients with uveal melanoma arising from ocular melanocytosis are at increased risk for metastasis. (9–12)An analysis of 7872 eyes with uveal melanoma showed a 1.6 times greater risk for metastasis compared to those without melanocytosis(10). This risk was further confirmed by a matched study, which found a two times higher rate of metastasis in patients with uveal melanoma associated with ocular melanocytosis(11). Specifically, the 10-year rate of melanoma metastasis was 48% in eyes with melanoma and melanocytosis, compared with 24% in eyes without melanocytosis.(10,9) Thus, these patients require intensive follow-up for the detection of potential hepatic metastases.

III. Conclusion :

Ocular melanocytosis is a known predisposing factor for both unifocal and multifocal melanomas. Lifelong monitoring for uveal melanomas must be done in all patients with ocular melanocytosis. The risk of developing uveal melanoma increases gradually after the first decade of life.

References :

- [1] Patel Dr, Patel Bc. Ocular Melanoma. In: Statpearls [Internet]. Treasure Island (FL): Statpearls Publishing; 2024 [Cité 30 Avr 2024]. Disponible Sur: [Http://Www.Ncbi.Nlm.Nih.Gov/Books/Nbk551647/](http://www.ncbi.nlm.nih.gov/books/nbk551647/)
- [2] Masson E. Em-Consulte. [Cité 30 Avr 2024]. Le Mélanome De La Choroïde. Disponible Sur: [Https://Www.Em-Consulte.Com/Article/1036545/Le-Melanome-De-La-Choroïde](https://www.em-consulte.com/article/1036545/le-melanome-de-la-choroïde)
- [3] Zografos L. Tumeurs Intraoculaires. Masson. 2002;
- [4] Shields Ja, Shields Cl. Intraocular Tumors: An Atlas And Textbook. Lippincott Williams & Wilkins; 2008. 596 P.
- [5] Mélanome Choroïdien Achrome Sur Mélanocytose Oculaire | Dr Livia Lumbroso-Le Rouic [Internet]. [Cité 1 Mai 2024]. Disponible Sur: [Https://Www.Edimark.Fr/Revues/Images-En-Ophtalmologie/N-3-Juin-2022-Copy/Melanome-Choroïdien-Achrome-Surmélanocytose-Oculaire](https://www.edimark.fr/revues/images-en-ophtalmologie/N-3-Juin-2022-Copy/Melanome-Choroïdien-Achrome-Surmélanocytose-Oculaire)
- [6] Seregard S, Ladenvall G, Kock E. Multiple Melanocytic Tumours In A Case Of Ocular Melanocytosis. Acta Ophthalmol (Copenh). Août 1993;71(4):562-5.
- [7] Gündüz K, Shields Ja, Shields Cl, Eagle Rc Jr. Choroidal Melanoma In A 14-Year-Old Patient With Ocular Melanocytosis. Arch Ophthalmol. 1 Août 1998;116(8):1112-4.
- [8] Di Nicola M, Ebert J, Hagen Mc, Augsburger Jj, Williams Bk. Unilateral Multifocal Choroidal Melanoma With Underlying Isolated Choroidal Melanocytosis. Ocul Oncol Pathol. Juin 2022;8(2):100-4.
- [9] Rao R, Honavar Sg, Mulay K. Multifocal Choroidal Melanoma In Oculodermal Melanocytosis In An Asian Indian. Indian J Ophthalmol. Déc 2019;67(12):2089-91.
- [10] Gonder Jr, Shields Ja, Albert Dm, Augsburger Jj, Lavin Pt. Uveal Malignant Melanoma Associated With Ocular And Oculodermal Melanocytosis. Ophthalmology. Août 1982;89(8):953-60.