

# Age Of Apophyseal Fusion In Iliac Crest Among The Manipuri Undergraduate Students Of Rims

Soibam Balasana Devi<sup>1</sup>, Ch. Rajlakshmi<sup>2</sup>, Y. Priyabarta

<sup>1</sup>(Post Graduate Trainee, Department Of Anatomy, Regional Institute Of Medical Sciences, Imphal, India)

<sup>2</sup>(Professor, Department Of Anatomy, Regional Institute Of Medical Sciences, Imphal, India)

<sup>3</sup>(Associate Professor, Department Of Radiodiagnosis, Regional Institute Of Medical Sciences, Imphal, India)

## Abstract

**Background:** An apophysis is a growing center which grows upon the mother bone. In the anteroposterior roentgenographic view of the pelvis, the iliac apophysis appears laterally and anteriorly on the iliac crest and is termed as capping. With continued growth it develops posteriorly across the iliac crest to dip down to contact the ilium medially at its junction near the sacrum and is considered to be completed or attached. The iliac apophysis may develop in fragments. After the usual capping or the appearance of ossification anteriorly and laterally on the iliac crest, further development may occur posteriorly, leaving a space or a gap to be filled in later.

The necessity of determination of age of an individual is a matter of everyday occurrence in every part of the world. Evaluation of age by radiological study of union of ossification centers is helpful to solve many civil and criminal cases. Age determination at the time of death is of supreme importance for identification purpose. The fusion of the various epiphyses occurs at a specified order and period of time in life and their correlation is useful to establish an age in both antemortem and post mortem cases.

**Materials and methods:** This analytical cross-sectional study was carried out at the Department of Anatomy and Radiodiagnosis, Regional Institute of Medical Sciences, Imphal, from August 2022 to Jan 2024 on 137 undergraduate Manipuri students of Regional Institute of Medical Sciences, Imphal belonging to age group of 18 to 25 years. After obtaining written consent from the subjects satisfying the inclusion criteria, the general physical examination was conducted to know the health status and rule out any deformities to select the subjects. X-Ray AP view of pelvis was done and staging was done accordingly.

**Results:** In the present study, females show apophyseal union at 22 years of age & males show apophyseal union at 24 years of age.

**Conclusion:** Such a study among both males and females was required in Manipur. We can conclude that age of appearance of ossification centres around iliac crest vary in many cases from age old data which is considered till date. The data recommended by us can be taken as reference in future for forensic and surgical purposes.

**Keyword:** Apophyseal, iliac crest, X-Rays, age determination, civil and criminal cases.

Date of Submission: 26-05-2024

Date of Acceptance: 06-06-2024

## I. Introduction

The hip bone ossification is by three primary centres: one each for the ilium, ischium and pubis. At about the ninth week the iliac centre appears above the greater sciatic notch prenatally; the ischial centre in its body in the fourth month; and the pubic centre in its superior ramus between the fourth and fifth months. At birth the whole of iliac crest, the acetabular floor and the inferior margin are cartilaginous. Gradual medially to the pelvic surface as a Y-shaped epiphysial plate between the ilium, ischium and pubis, and including the anterior iliac spine. Secondary ossification centres, other than the acetabulum, appear at about puberty and fuse between the fifteenth and twenty fifth years. There are usually two for the iliac crest<sup>1</sup>.

A growing center which grows upon the mother bone is known as apophysis. In the anteroposterior roentgenographic view of the pelvis, the iliac apophysis appears laterally and anteriorly on the iliac crest and is termed as capping. With continued growth it develops posteriorly across the iliac crest to dip down to contact the ilium medially at its junction near the sacrum and is considered to be completed or attached. The iliac apophysis may develop in fragments. After the usual capping or the appearance of ossification anteriorly and laterally on the iliac crest, further development may occur posteriorly, leaving a space or a gap to be filled in later<sup>6</sup>. The rate of bone maturation differs among ethnic groups although the bone maturation process itself is similar among all people. The main cause of the difference in bone maturation rate among ethnic groups is the difference in the timing of pubertal onset<sup>2</sup>.

Age estimation in the living is one of the most important tasks in a developing country like India as birth records are often not well maintained. There is variation in the timing of appearance and fusion of the epiphyses

of the bones. Ossification is seen earlier in the tropical countries and in females. Various factors like climate, heredity, race, nutrition, dietary habits, gender and socioeconomic status of the population can cause the variation in the age of appearance and union of ossification<sup>1</sup>. It is impracticable to enunciate a hard and fast rule for age determination for the whole India from study of union of a region as India is composed of areas which differs in climate, dietetic and disease factors which affect skeletal growth<sup>3</sup>.

The necessity of determination of age of an individual is a matter of everyday occurrence in every part of the world. Evaluation of age by radiological study of union of ossification centers is helpful to solve many civil and criminal cases. Determination of age at the time of death is of supreme importance for identification purpose<sup>4</sup>.

## **II. Material And Methods**

This is an analytical cross-sectional study conducted at the Department of Anatomy and Radiodiagnosis, Regional Institute of Medical Sciences, Imphal, India from August 2022- Jan 2024 on 137 undergraduate Manipuri students of Regional Institute of Medical Sciences, Imphal.

### **Inclusion criteria:**

Subjects belonging to Manipur by origin.  
Subjects having documentary evidence of age in the form of birth certificate issued by competent authority.  
Age group: 18 to 25 years.  
Subjects who gave their written consent.

### **Exclusion criteria:**

Subjects without proof of birth record.  
Subjects with Chronic illness.  
Subjects with Endocrinal disorders.  
Subjects with the deformity of pelvis.

### **Data Analysis:**

Data was entered in IBM SPSS version 21 for Windows.

### **Method of collection of data:**

After obtaining written consent from the subjects satisfying the inclusion criteria, the general physical examination will be conducted to know the health status and rule out any deformities to select the subjects.

### **Method for X-Ray examination:**

#### **AP View for Pelvis:**

Patient was in supine position with the median sagittal plane adjusted to coincide with the central longitudinal axis of the couch. Anterior superior iliac spines equidistant from the couch top. The knees flexed over foam pads for comfort. The heels separated and the limbs rotated medially so that the long axis of the feet is approximately 5-10 degrees to the vertical. The film was centered at a level midway between anterior superior iliac spines and superior border of the symphysis. Centering of the X-Ray beam-centre in the midline midway between the level of the anterior superior iliac spine and the superior border of the symphysis pubis with the central ray perpendicular to the film<sup>5</sup>.

### **Staging Of The Degree Of Fusion:**

The degree of fusion of the apophysis of crest of ilium are graded into stages and sub-stages according to the study done by Wittschieber D et al<sup>6</sup> as follows:

Stage 1 – Ossification center has not ossified yet.

Stage 2 – Ossification center has ossified, apophyseal cartilage has not ossified.

2a- The lengthwise apophyseal measurement is one third one less compared to the maximal lengthwise measurement of the iliac wing

2b- The lengthwise apophyseal measurement is over one third and less than two third compared to the maximal lengthwise measurement of the iliac wing

2c- The lengthwise apophyseal measurement is over two third compared to the maximal lengthwise measurement of the iliac wing.

Stage 3 – Apophyseal cartilage has partially ossified.

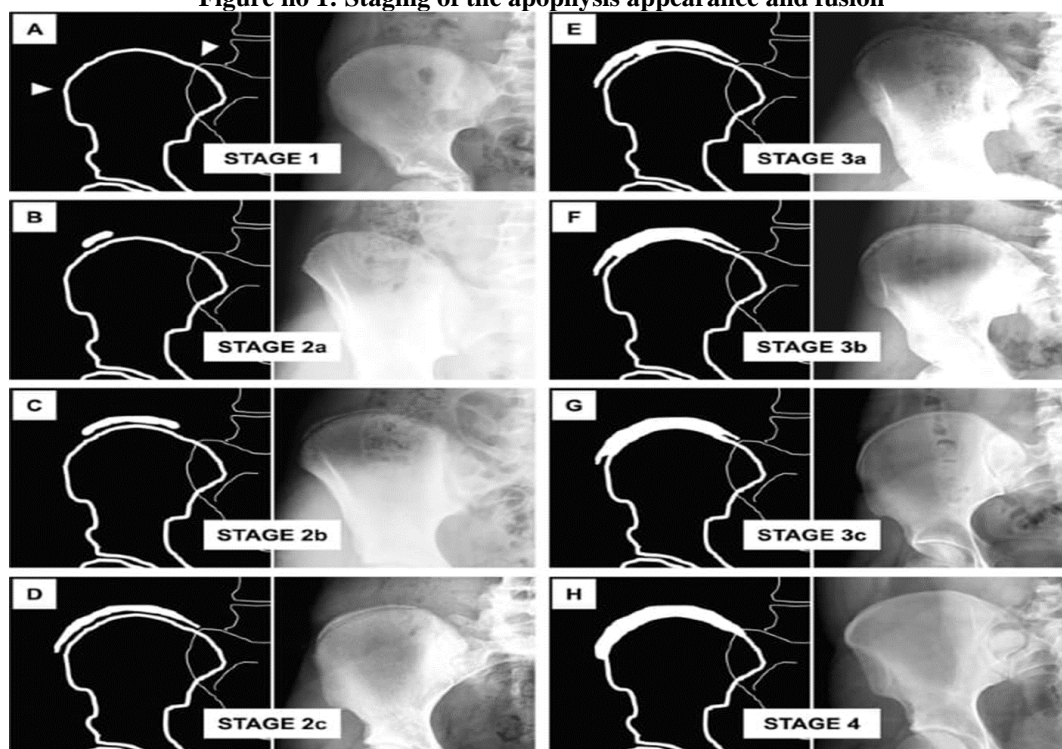
3a – The apophyseal fusion of the iliac bone is completed in one third or less.

3b – The apophyseal fusion of the iliac bone is completed in over one third and less than two thirds.

3c – The apophyseal fusion to the iliac bone is completed in over two thirds.

Stage 4 – Apophyseal cartilage has fully ossified.

Figure no 1: Staging of the apophysis appearance and fusion



**Materials:**

- X-Ray machine - Digital radiography system (SAMSUNG GU60, wavelength: 635nm)
- Data collecting instrument, X-ray film
- Lead marker, lead apron
- Film hanger
- View box
- Magnifying lens
- Weighing machine and height measurement scale.

**Sampling method:** Convenient sample collection

**Ethical issues:**

Ethical approval was obtained from the Research Ethics Board (REB), RIMS, Imphal before beginning the study with REB number- A/206/REB-Comm(SP)/RIMS/2015/888/226/2022. Written consent from all participants were obtained. Steps were taken to maintain confidentiality. Data collected were kept under lock and key. Entered data was password protected.

**III. Result**

A total of 137 (one hundred and thirty-seven) conventional pelvic radiographs of participants between the age range of 18-25 years were sighted for assessment of pelvic skeletal maturity. Out of the 137 participants 70 were males and 67 participants were female as shown in table no.1 and figure no.2

Table no 1: Age-Gender Distribution

Age	Gender		Total
	Male	Female	
18	5	5	10
19	6	9	15
20	14	12	26
21	14	22	35
22	16	12	28
23	10	2	12
24	2	3	5
25	4	1	6
Total	70	67	137

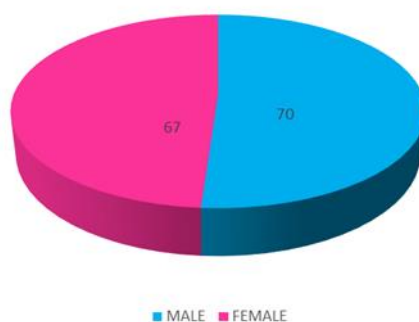


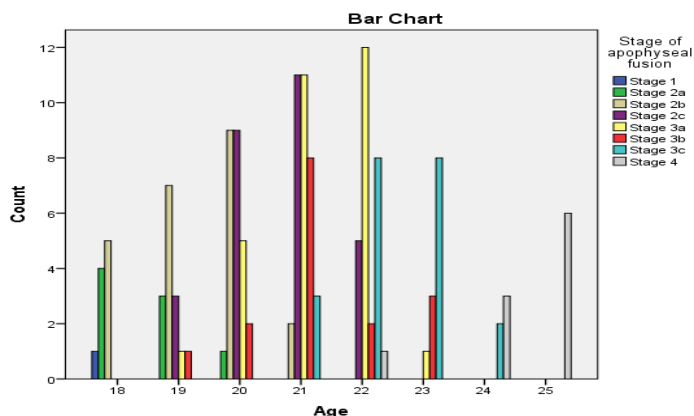
Figure no.2- Gender distribution of the participants

In 18years age group, only 1 female was observed in stage 1, 2 males and 2 females in stage 2a, 3 males and 2 females in stage 2b, stages 2c, 3a, 3b, 3c and 4 were not observed in this age group. In 19years age group, stage1 was not observed, stage 2a was seen only in 3 females, 6 males and 1 female in stage 2b, three females in stage2c, one female each in stages 3a and 3b, stage 3c and 4 were not observed. In 20years age group, stage1 was not observed, one male in stage 2a, 6 males and 3 females in stage 2b, 7 males and 2 females in stage 2c, 5 females in stage 3a, 2 females in stage 3b, stages 3c and 4 were not observed In 21years age group, stage1 and 2a were not observed, 2 males in stage 2b, 5 males and 6 females in stage 2c, 5 males and 6 females in stage 3a, 1 male and 7 females in stage 3b, 3 females in stage 3c, stage 4 was not observed In 22years age group, stages 1, 2a and 2b were not observed, 2 males and 3 females in stage 2c, 9 males and 3 females in stage 3a, 1male and 1 female in stage3b, 4 males and 4 females in stage 3c, 1 female in stage 4 In 23years age group, stages 1, 2a, 2b, 2c and 4 were not observed, 1 male in stage 3a, 3 males in stage 3b, 6 males and 2 females in stages 3c, stage 4 was not observed In 24years age group, stages 1, 2a, 2b, 2c, 3a and 3b were not observed, 1 male and 1 female in stage 3c, 1 male and 2 female in stage 4. In 25years age group, stages 1,2a,2b,2c,3a,3b and 3c were not observed, 4 males and 2 females were observed in stage 4 as shown in table no.2, figure no. 3 and figure no.4. Figure no. 5 to figure no.12 shows the X-Rays at various stages.

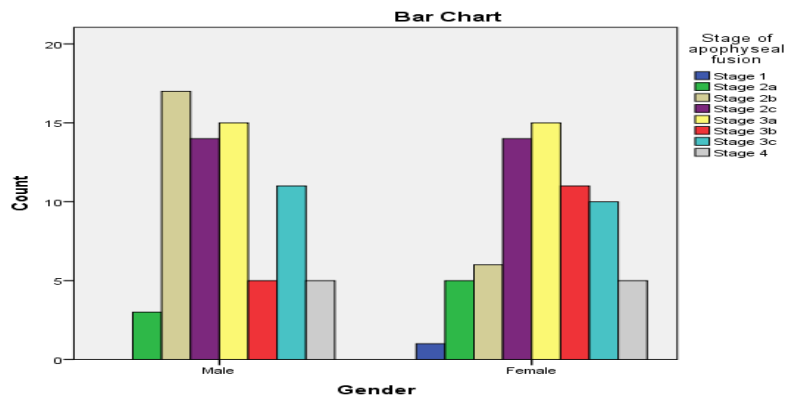
Table no. 2- Age wise distribution of stages

Age	Stage1		Stage2a		Stage2b		Stage2c		Stage3a		Stage3b		Stage3c		Stage4		Total
	M	F	M	F	M	F	M	F	M	F	M	F	M	F	M	F	
18	-	1	2	2	3	2	-	-	-	-	-	-	-	-	-	-	10
19	-	-	-	3	6	1	-	3	-	1	-	1	-	-	-	-	15
20	-	-	1	-	6	3	7	2	-	5	-	2	-	-	-	-	26
21	-	-	-	-	2	-	5	6	5	6	1	7	-	3	-	-	35
22	-	-	-	-	-	-	2	3	9	3	1	1	4	4	-	1	28
23	-	-	-	-	-	-	-	-	1	-	3	-	6	2	-	-	12
24	-	-	-	-	-	-	-	-	-	-	-	-	1	1	1	2	5
25	-	-	-	-	-	-	-	-	-	-	-	-	-	-	4	2	6
Total	0	1	3	5	17	6	14	14	15	15	5	11	10	5	5	137	

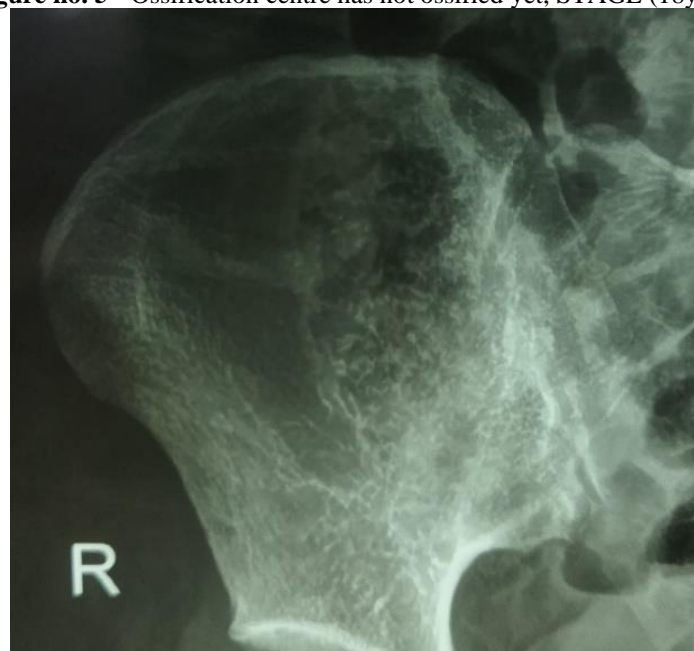Figure no. 3- Bar chart of Age wise distribution of stages



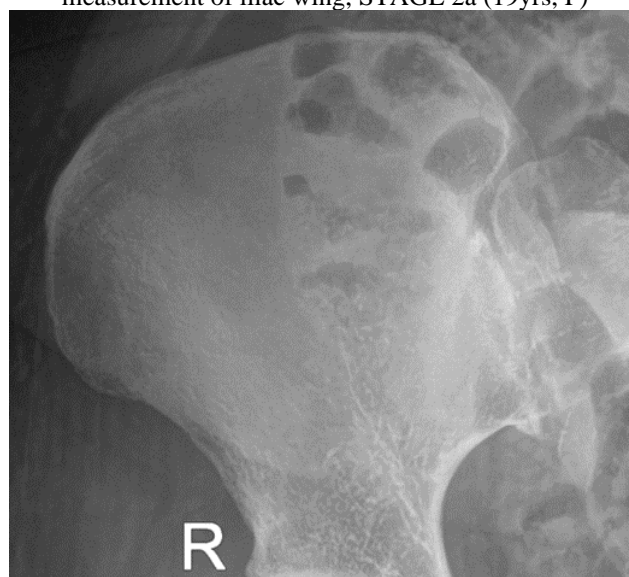**Figure no. 4-** Bar chart of gender wise distribution of stages



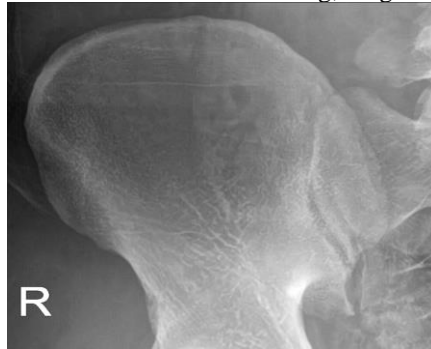**Figure no. 5 -** Ossification centre has not ossified yet, STAGE (18yr, F)



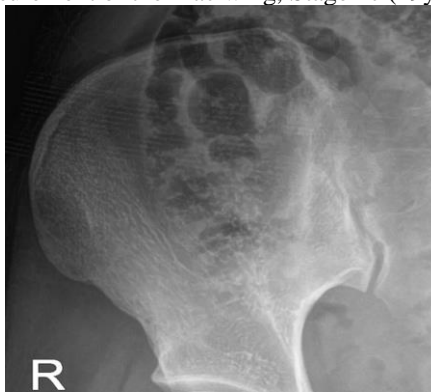**Figure no.6 –** Lengthwise apophyseal measurement is 1/3<sup>rd</sup> or less compared to the maximal lengthwise measurement of iliac wing, STAGE 2a (19yrs, F)



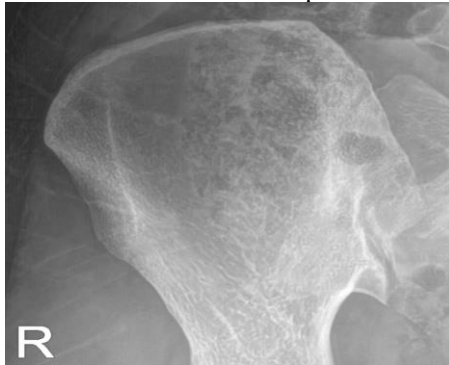**Figure no. 7** – Lengthwise apophyseal measurement is over  $1/3^{\text{rd}}$  and less than  $2/3^{\text{rd}}$  compared to the maximal lengthwise measurement of the iliac wing, Stage 2b (18yrs, M)



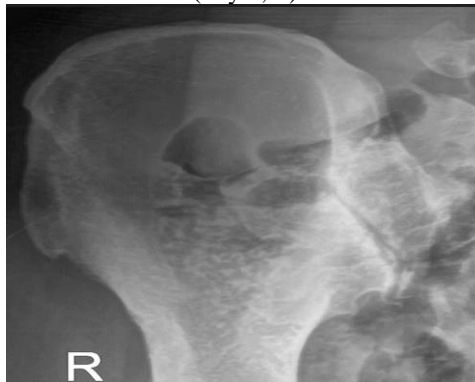**Figure no.8** – Lengthwise apophyseal measurement is over  $2/3^{\text{rd}}$  compared to the maximal lengthwise measurement of the iliac wing, Stage 2c (19yrs, F)



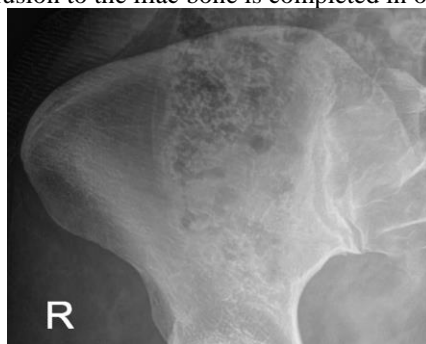**Figure no. 9** - Apophyseal fusion of the iliac bone is completed in  $1/3^{\text{rd}}$  or less, STAGE 3a (20yrs, F)



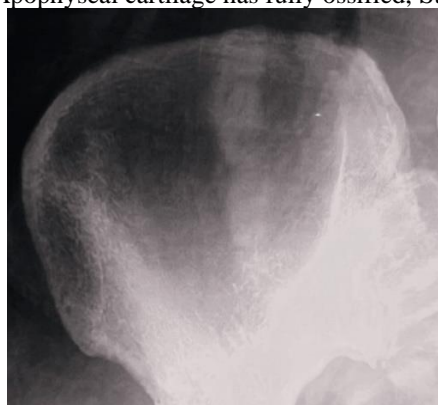**Figure no. 10** – Apophyseal fusion of the iliac bone is completed in over  $1/3^{\text{rd}}$  and less than  $2/3^{\text{rd}}$ , STAGE 3b (21yrs, F)



**Figure no. 11** – Apophyseal fusion to the iliac bone is completed in over 2/3<sup>rd</sup>, STAGE 3c (21yrs, F)



**Figure no. 12** -Apophyseal cartilage has fully ossified, Stage 4 (22YRS, F)



#### IV. Discussion

In the present study, females show apophyseal union at 22 years of age & males show apophyseal union at 24 years of age

Table 2 shows for male in 24year age group one case of complete union, in 25year age group 4 cases of complete union. For females in 22year age group one case show complete union, in 24year age group 2 cases show complete union and in 25year age group 2 cases show complete union. Total 5 cases of males and 5 cases of females shows completed union in this study.

The present study findings are close to Davies & Parson study on English population and Bennet KA study on American population as shown in table no.3

#### V. Conclusion

Such a study among both males and females was required in Manipur. We can conclude that age of appearance of ossification centres around iliac crest vary in many cases from age old data which is considered till date. The data recommended by us can be taken as reference in future for forensic and surgical purposes

**Table no. 3-** Comparison of time of fusion of iliac crest with that shown by other authors

Researcher	Region/Population	Iliac crest		
		Male	Female	
1	Galstaun	Bengalis	19-20	17-19
2	Pillai	Madrasis	14-18	14-18
3	Dasgupta et al	Uttar Pradesh	19-20	19-20
4	Parikh	Indian	20-21	18-19
5	Sankhyan S et al	Himachal Pradesh	21 ½	21 ½
6	Bhise S et al	Mumbai	21-22	20-21
7	Devraj N et al	Maharashtra	-	20-21
8	Sangma W et al	Manipur	-	21
9	Sharma Y et al	Rajasthan	21-22	20-21
10	Naik M et al	Andhra Pradesh	15-17	15-17
11	Nagrle N et al	Chhattisgarh	21-22	21-22
12	Flecker	Australia	18	15-16
13	Davies & Parson	English	23	23
14	Bennet KA	USA	23	23
15	Present study	Manipur	24	22

### References

- [1] Shoja MM. Pelvic Girdle, Gluteal Region And Thigh. In: Tubbs RS, Stranding S, Editors. Gray's Anatomy The Anatomical Basis Of Clinical Practice. 42<sup>nd</sup> Ed. Philadelphia: Elsevier; 2020. P.1352-1394.
- [2] Ashizawa K, Asami T, Anzo M, Matsuo N, Matsuoka H, Murata M Et Al. Standard RUS Skeletal Maturation Of Tokyo Children. *Ann Hum Biol.* 1996;23: 457-69.
- [3] Bhise SS And Nanandkar SD. Age Determination From Pelvis A Radiological Study In Mumbai Region. *J Indian Acad Forensic Med.* 2012 Apr;34(2): 104-107.
- [4] Nagrale N, Patond S, Ambad R, Bankar N, Jain K. Radiological Evaluation Of Innominate Bone For Age Estimation: A Cross Sectional Study From Central India. *Indian JFMT.* 2020 Oct;14(4):6849-6852.
- [5] Dikshit KR, Dikshit JK. North-East India: Land, People And Economy, *Advances In Asian Human-Environmental Research.* 2013 Jul 24;285-420
- [6] Wittschieber D, Vieth V, Domnick C, Pfeiffer H, Schmeling A. The Iliac Crest In Forensic Age Diagnostics: Evaluation Of The Apophyseal Ossification In Conventional Radiography. *Int J Legal Med.* 2013 Oct;127: 473-479.
- [7] Phanjoubam M, Nabachandra H, Kharrubon B, Fimate L. Determination Of Age Of Majority Of Manipuri Girls From Radiological Examination Of Joints. *Medico-Legal Update.* 2007 Jul;2(41).
- [8] Singh TB. Determination Of Age In Majority Of Manipuri Girls From The Radiological Examination Of The Joints. *Medico-Legal Update.* 2007 Apr;7(2).
- [9] Lottering N, Knox A, Macgregor D M, Izatt M T, Grant C A, Adam C J Et Al. Apophyseal Ossification Of The Iliac Crest In Forensic Age Estimation: Computed Tomography Standards For Modern Australian Subadults. *J Forensic Sci.* 2016 Nov 25;62(2):292-307.
- [10] Yatiraj S, Deshmukh K, Bijapur. Assessment Of Age In Adolescents By Radiological Examination Of Pelvis And Hip Joint. *Int J Of Med And Health Sci.* 2012 Apr; 1(2): 10-16.
- [11] Singh P, Gorea RK, Oberoi SS, Kapila AK. Estimation Of Age From Epiphyseal Fusion In Iliac Crest. *Indian Acad FM.* 2011 Jan;33(1): 24-26.
- [12] Saksena JS And Vyas SK. Epiphyseal Union At The Wrist, Knee And Iliac Crest In Residents Of Madhya Pardesh. *J Indian Med Assoc.* 1969 Jul 16;53(2): 67-8.
- [13] Smith EP, Boyd J, Frank GR, Takahashi. Estrogen Resistance Caused By A Mutation In The Estrogen-Receptor Gene In A Man. *N English J Med.* 1994;331: 1056-61.
- [14] Saini PC, Punia RK, Simatwal NK. An Observational Study Of Radiological Age And Documented Age In 16-20 Years Age Group In Jaipur. *Medico-Legal Update.* 2019 Jul;19(2): 134-140.
- [15] Assumi NK. Survey Committee Report On Medicolegal Practice In India, Ministry Of Health. 1964. 2010 July 22; 1-70.
- [16] Sangma WBC, Marak FK, Singh M S, Kharrubon B. Age Determination In Girls Of North- Eastern Region Of India. *J Indian Acad FM.* 2007;29(4): 102-108