

# Noninvasive Procedures In Paediatric Dentistry And Assessing The Clinical Effect Of Silver Diamine Fluoride [Sdf] Application In Arresting Dental Caries In Deciduous Teeth

Dr. Rawaa Basil Fadhil Al-Meshaikhy, Dr. Maryam Riyadh Yaseen Al-Bayati,  
Dr. Tamara Shaker Hasson, Dr. Hamza Waleed

(Assistant Lecturer In The Department Of Dentistry, Alfarabi University College, Iraq)

(Assistant Lecturer In The Department Of Dentistry, Alfarabi University College, Iraq)

(Assistant Lecturer In The Department Of Dentistry, Alfarabi University College, Iraq)

(Lecturer In The Department Of Dentistry, Alfarabi University College, Iraq)

---

## Abstract:

Minimally invasive techniques that use silver compounds and glass ionomer cement are suggested for caries management due to their effectiveness, simplicity, and low cost. The aim of this study is to assess the clinical effect of silver diamine fluoride [SDF] application on dental caries in deciduous teeth. Study design or material and methods: The study includes paediatric patients who had carious primary teeth according to international caries detection system II. A 38% SDF solution was applied directly to the lesion on deciduous teeth as per the manufacturer's instructions. A follow-up evaluation was performed after two and four months. Clinical results were used to assess the effectiveness of SDF application. Results: The use of silver diamine fluoride [SDF] was shown to be effective in arresting caries. This compound reduces cariogenic microorganisms. Its chemical properties inhibit bacterial growth while promoting remineralization. It is simpler and less time-consuming than conventional restorations. It also causes less discomfort and anxiety to patients. Conclusions: Minimally invasive therapies are easy to apply, non-invasive, and cost-effective. Further studies should be done to provide more evidence for the effectiveness of silver diamine fluoride [SDF] application for caries management.

**Keywords:** Dental caries, Atraumatic Restorative Treatment (ART), silver diamine fluoride (SDF), remineralization, inhibition of bacterial growth.

---

Date of Submission: 19-06-2024

Date of Acceptance: 29-06-2024

---

## I. Introduction

Although the great developments in the dental knowledge of the people and the dramatic advancements in the dental management techniques during the past decades, international records on caries epidemiology prove that dental caries continues to be a predominant and serious ailment that is found in both developing and developed countries around the world [1], [2]. There are many significant factors of high-risk causing dental caries which include; Dietary sugars, bad oral hygiene, poor parental education, adverse socioeconomic conditions, low family income, and regular medications [1].

Dental caries is a common chronic infectious disease resulting from tooth-adherent cariogenic bacteria, primarily Streptococcus Mutans, which metabolize sugars to release acid, demineralizing the tooth structure over time [3]. Tooth decay starts when the bacteria in the oral cavity produce acids that attack the tooth's surface (enamel). This results in a small hole in a tooth, called a cavity. If appropriate management will not be applied for carious tooth, this will lead to pain, infection, and destruction of the tooth.

Management of dental caries in a general population is often either unavailable or expensive, especially for children. Furthermore, child's cooperation during dental management is usually very challenging, demanding improved skills of clinicians besides the high cost of general anaesthesia or sedation for patient management. Recently, the trend is directed toward the including of minimally invasive techniques for caries management in dentistry [2],[4].

Typically, treatment of dental caries consists of restorative therapies, which includes too much removal of intact dental tissue in order to enhance the mechanical retention of restorative material. Recently, with the development of new biomaterials, non-invasive treatments have been suggested as an alternative treatment.

Minimally invasive treatments have been used in primary teeth with activated lesions in order to maintain pulp vitality, allow space conservation, and enable the natural process of exfoliation and tooth

replacement without the administration of local anaesthesia [5]–[7].

Between these strategies of minimally invasive managements, the introduction of atraumatic restorative treatment with glass ionomer cement (ART), silver nitrate (SN), and silver diamine fluoride (SDF) have been suggested for caries management in dentistry. In Japan, China, and Australia these materials have been used for decades for caries management. Fluoride, a mineral, is naturally present in many foods and available as a dietary supplement.

Fluoride is the ionic form of the element fluorine, and it prevents or arrests the starting and progression of dental caries (tooth decay) and enhances the formation of new bone. SDF is a clear fluid that integrates the antibacterial effects of silver with the remineralization power of fluoride. SDF is applied on the areas those affected by caries in a fast and painless technique. Then, the treated areas are permanently stained black [8].

Silver diamine fluoride [SDF] treatment is one of the best alternatives to conservative treatments for cavities in deciduous teeth. SDF was introduced to dentistry by Reichi Yamaga, Misuho Nishino, and colleagues to prevent and manage tooth decay. SDF was approved by PMDA (equivalent of FDA) in 1970 in Japan and has been used there since that time. Since 1980 SDF has been widely used in Australia and Brazil in researches and *In vivo* studies.

SDF stop initiation of dental caries through three primary mechanisms of action: 1-Remineralization, 2-Antiproteolytic activity and 3- Antimicrobial activity [9]. All of these effects are assigned to the feature of bioavailability of fluoride and silver ions [10]. SDF ions elevate the local pH, which stimulates remineralization by calcium and fluoride [11].

SDF impedes the formation of caries due to the inhibitory effect on matrix metalloproteinases and cathepsins, which are responsible for dentin collagen degradation during the caries process. Silver ions in the SDF solution act on the biofilm, inhibiting the bacterial aggregation of streptococci, actinomycetes, and lactobacilli, which are the essential bacteria responsible for developing the process of caries [11].

The ions of silver work on the cell wall of bacteria, results in cell lysis and prevent bacterial metabolic activity and stop duplication of bacterial DNA [12]. Furthermore, the patency of dentinal tubules can be reduced by silver deposits, therefore these silver precipitants prevent bacteria and their metabolites from extending to the deeper parts of pulp and dental structures [13]. whereas, the ammonia represents as a stabilizer, helping the other ions to stay stable over a longer period of time [11].

There are many Indications of SDF which include: 1. Patients in the high risk group for dental caries, 2. Patients who cannot allow common treatment for Mental or medical causes, 3. Patients who have more dental caries that can't be treated in a single call, 4. Lesions that are hard to treat like root cavities. 5. Patients with no attainment to dental treatment. 6. Can also be used on non-cariou cervical Lesions prior to restoration placement and in molar incisor hypomineralization (MIH) to reduce sensitivity [11].

However, there are some Contraindications of SDF 1. Clinical signs or symptoms of irreversible pulpitis.

2. Dental abscess/fistula. 3. Radiographic signs of pulpal involvement or peri-radicular pathology. 4. Silver, fluoride, or ammonia allergy. 5. Patients with ulceration, mucositis, or stomatitis. 6. Pregnant or breastfeeding women due to concerns of overloading the developing thyroid with iodide [14].

Although the black staining on the carious lesion that formed after SDF application, many previous studies and reports have illustrated the advantages of SDF in controlling the pain and infection by arresting the caries progression, affordability, immediate relief of dentine hypersensitivity by blocking dentine tubules, easily performed and painless technique.

Additionally, The Treatment does not require expensive Equipment or support infrastructure such as piped water and electricity [15] 6. The procedures are simple. This allows non- dental professionals Including primary health care workers to be easily trained to apply SDF to children [15]. 7. Stabilisation/arrest of caries in elderly patients eg root caries. Quick and Easy application makes it useful for patients who are vulnerable, Uncooperative, have behavioural problems and those with limited access to conventional dental treatment [16] Remineralisation of incipient carious lesion (2-3 times more fluoride Concentration than sodium fluoride varnish) [16].

The aim of this study is to assess the effect of SDF application on dental caries in primary teeth and illustrate the importance of minimally invasive techniques in caries managements especially child populations.

## **II. Materials And Methods**

Four years old patient attended to our clinic presented with multiple active caries. We had the consent from the patient's parents, they were informed of all the treatment details including the discolouration followed by the application of SDF. Lara had 6 teeth with carious lesions without history of pulpal inflammation, the teeth were upper (primary left second molar, primary right second molar) lower (primary right first & second molar, primary left first & second molar

This research was done in Paediatric Dentistry Department at Al-Farabi University College with Supervision of a preventive dentistry specialist. In this study we included paediatric patients who have multiple

caries in the deciduous teeth, the caries was classified in the active phase (soft) using the International Caries Detection and Assessment System II (ICDAS).

Score	ICDAS criteria
0	sound
1	First visual change in enamel (seen only after prolonged air drying or restricted to within the confines of a pit or fissure)
2	Distinct visual change in enamel
3	Localized enamel breakdown (without clinical visual signs of dentinal involvement)
4	Underlying dark shadow from dentine
5	Distinct cavity with visible dentine
6	Extensive distinct cavity with visible dentine

### Materials & instruments

- 1- SDF
- 2- Plastic dish.
- 3- Disposable microtip brush
- 4- Dental probe.
- 5- Dental mirror
- 6- Cotton roll
- 7- Protection medium to protect the lips and oral soft tissues from the discoloration (Vaseline).
- 8- Sodium fluoride varnish to protect the other teeth that were not treated by SDF and to reduce the metallic taste of SDF after treatment.

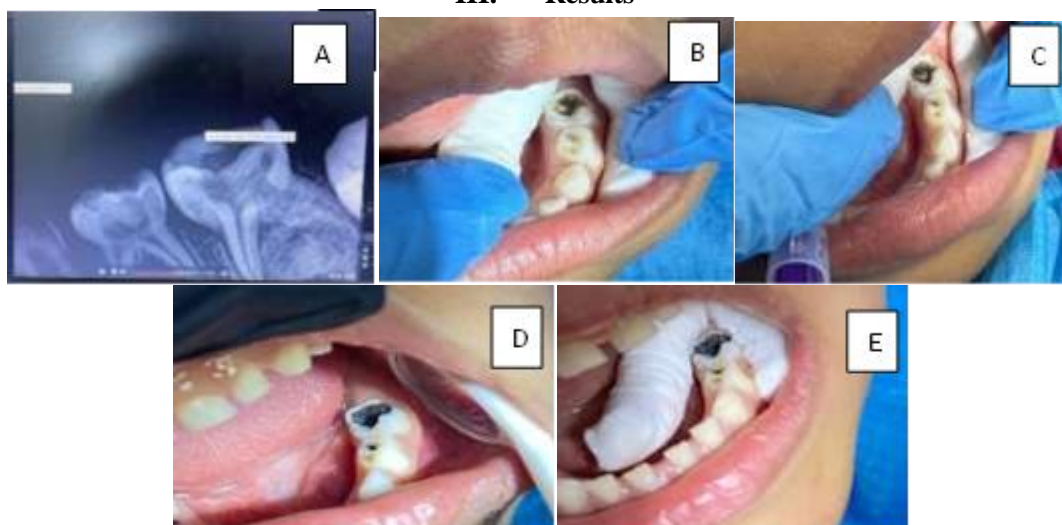


**Figure 1: Materials used in the SDF application**

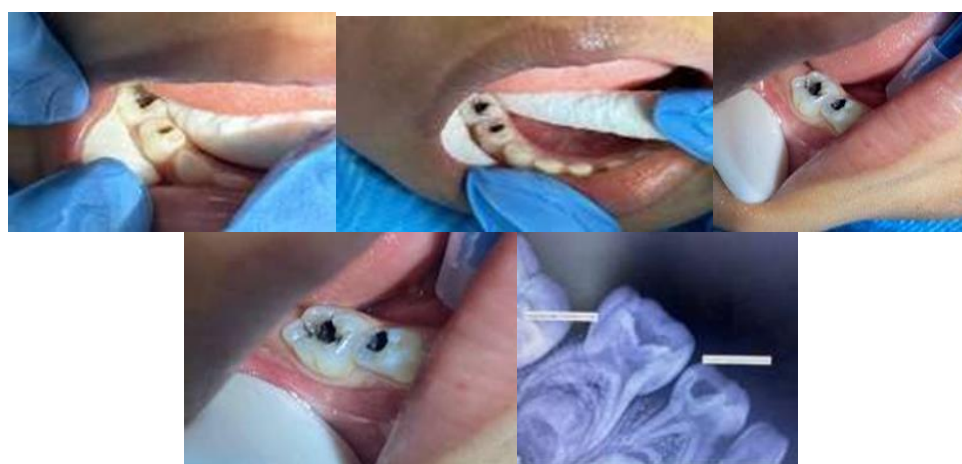
### Method of SDF application:

1. First: the protection medium is applied to the soft tissue
2. As per the manufacturer's instructions, 38% SDF (kids crown company), the tooth with active caries was dried and isolated with cotton rolls to prevent the saliva contact
3. Solution was put in a plastic dish and applied with a disposable microtip applicator directly to the lesion on primary teeth.
4. It was then left to absorb for up to 4 minutes
5. After finishing of the SDF application sodium fluoride varnish then is applied for 3 minutes.
6. A follow-up examination was performed to evaluate the lesion's colour and consistency after 2 months, then it was evaluated again after 2 months. At each follow-up visit, the presence or absence of pain and infection was noted. Dark, hard, and black lesions without pain or infection were regarded as positive outcomes when evaluating the efficacy of SDF based on clinical outcomes.

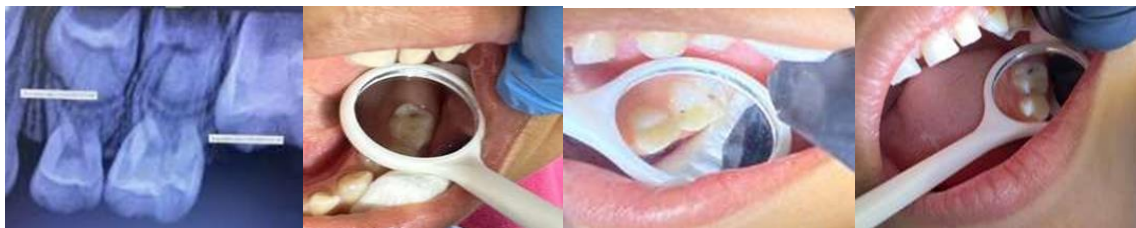### III. Results



- A) Peri- Apical X-Ray Showing Caries On Lower Left Primary First And Second Molars, No Signs Of Infection, No Periapical Radiolucency, No Root Resorption**
- B) The Teeth Before Application Of SDF: Lower Left Primary First Molar Score 4 Cavity According To ICDAS) & Lower Left Primary Second Molar (Score 5 According To ICDAS)**
- C) The Teeth Immediately After Application Of SDF (The Carious Lesion Turned From Brown To Black).**
- D) First Follow Up Visit (After 2 Months): Lower Left First Molar With Hard, Black Carious Lesion ( No Catch By Probe), Lower Primary Left Second Molar With Carious Lesion ( Slightly Catch By Probe). No Signs And Symptoms Of Pain And Infection Reapplication Of SDF On Lower Primary Left Second Molar.**
- E) Second Follow Up Visit (After 4 Months): ) : Lower Left First Molar With Hard, Black Carious Lesion ( No Catch By Probe), Lower Primary Left Second Molar With Carious Lesion ( Slightly Catch By Probe), No Signs And Symptoms Of Pain And Infection**



- A) Peri- Apical X-Ray Showing Caries On Lower Right Primary First And Second Molars, No Signs Of Infection, No Periapical Radiolucency, No Root Resorption**
- B) The Teeth Before Application Of Sdf: Lower Left Primary First Molar Score 5 Cavity According To Icdas) & Lower Right Primary Second Molar (Score 5 According To Icdas)**
- C) The Teeth Immediately After Application Of Sdf ( The Carious Lesion Turn From Brown To Black).**
- D) First Follow Up Visit (After 2 Months): Lower Right First Molar With Hard, Black Carious Lesion ( No Catch By Probe), Lower Primary Right Second Molar With Carious Lesion ( Slightly Catch By Probe). No Signs And Symptoms Of Pain And Infection Reapplication Of Sdf On Lower Primary Right Second Molar.**
- E) Second Follow Up Visit (After 4 Months): Lower Right First Molar With Hard, Black Carious Lesion (No Catch By Probe), Lower Primary Right Second Molar With Carious Lesion (Slightly Catch By Probe), No Signs And Symptoms Of Pain And Infection.**



- A) Peri- Apical X-Ray Showing Caries On Upper Right Primary First Molar, No Signs Of Infection, No Periapical Radiolucency, No Root Resorption**
- B) The Teeth Before Application Of Sdf: Upper Right Primary First Molar Score 4 Cavity According To Icdas)**
- C) First Follow Up Visit (After 2 Months): Upper Right First Primary Molar With Hard, Black Carious Lesion ( No Catch By Probe**
- D) Second Follow Up Visit (After 4 Months) : Upper Right First Primary Molar With Hard, Black Carious Lesion ( No Catch By Probe), No Signs And Symptoms Of Pain And Infection**

#### **IV. Discussion**

Although dental caries does not threaten life, it brings significant consequences like pain, infections, and tooth loss if not treated on time, as well as aesthetic and functional consequences [17].

Dental caries is a disease produced by bacterial infection, with patients at different degrees of risk, rather than just a lesion. Although many dental schools have taught the surgical method of restoring the damage caused by caries in the past decades, the modern caries-management philosophy has changed dramatically from the traditional approach to less invasive management, which includes the application of fluoride and antimicrobial agents [18]. Instead of just focusing on restorative treatment, dentists should also focus on the infection caused by bacteria to improve an individual strategy to manage the bacterial part of caries, so that it can inhibit further decay. Oral hygiene improvement and diet modification reduce the possibility for dental caries. Moreover, dentists should focus on remineralization instead of caries removal (demineralized tissue). The process of remineralization can be assisted with the use of fluoride agents [18], [19]. To prevent and inhibit caries, Fluoride can be applied in different forms; however, the integrated effects of silver and fluorides have been shown to be more effective in inhibiting caries advancement and blocking the development of new carious lesion [20]. For example, the application of 38% SDF twice a year was shown to be more efficient than semi-annual application of 5% NaF in arresting the process of caries [21]. comparably, according to the reports the yearly application of 38% SDF was shown to be more effective than every three-month application of 5% NaF.[22]. Therefore, based on the previous studies those were conducted on the application of SDF, it can be concluded that SDF was an effective, and safe caries-preventive material that seems to show the criteria of the Millennium Goals of the World Health Organization.

In this clinical trial of application SDF, the results proved that the application of SDF was significant in caries reduction. The goal of the present research was to evaluate the efficiency of 38% SDF solution in halting dental caries in deciduous teeth. At 4 months of follow-up, we found that SDF was 75% efficient in arresting dental caries in deciduous teeth. The application of SDF on decayed enamel of primary tooth, completely enhances the microhardness of enamel. Without proper and timely intervention, dental caries and other oral diseases can lead to severe systemic infections, may negatively affect oral health-related quality of life, and are associated with decreased student academic performance and school attendance. To address the high rate of untreated caries in high-risk populations, our results support the use of SDF which have demonstrated clinical effectiveness and cost effectiveness, as an arresting and preventive material for school-based oral health programs and complement previous results from other studies of nonrestorative managements and techniques in schools. Overall, we showed that SDF had an approximate 75%-80% caries prevention rate.

Minimally invasive dentistry can be used for the management of deeper carious lesions by using the approach of atraumatic restorative treatment, which removes selectively infected carious tissue, leaving caries-affected dentin for therapeutic remineralisation. Atraumatic restorative treatments are known to show an integrated technique-material effect. They stop caries and stimulate dental remineralisation by utilizing the potential of SDF [23]

Many studies have shown that the using of SDF was much more better than glass ionomer cement or fluoride varnish in arresting caries in primary teeth [23]. Before the application of silver compounds does not necessary to remove caries and this atraumatic restorative technique does not need well developed instruments. They are affordable agent to treat dental caries. The process of SDF application is characterised by being painless and simple and can be used for the general population [24]. Silver agents have been introduced in dental treatments for more than a century. Many studies have showed the effectiveness of silver nitrate + fluoride varnish as well as the silver diamine fluoride for caries management. Although the black staining is unavoidable and most parents



feel it is aesthetically unacceptable, many of them accept this kind of treatment to prevent their children from going under the classical treatment even with sedation or general anaesthesia.

## V. Conclusion

According to the results of many clinical studies have been conducted on SDF, this preventive material proves its effectiveness in dentistry. SDF treatment is an efficient, simple, quick, and safe method of dental treatment. It has shown to be an effective material in preventing caries initiation and stopping existing caries. It can also be employed to treat dentin hypersensitivity. In addition, it can be used to disinfect root canal (s) in endodontics treatment. SDF at 38% contains a high concentration of Silver and fluoride ions. Furthermore, many studies have not shown that the use of SDF results in irritation of gingiva, significant toxicity and dental fluorosis. Therefore, according to the literature it is a safe dental material

## References

- [1] S. S. Gao Et Al., "Clinical Trials Of Silver Diamine Fluoride In Arresting Caries Among Children: A Systematic Review," *Jdr Clin. Transl. Res.*, Vol. 1, No. 3, Pp. 201–210, Oct. 2016, Doi: 10.1177/2380084416661474.
- [2] E. Lo, "Promoting Caries Arrest In Children With Silver Diamine Fluoride: A Review," *Oral Heal. & Prev. Dent.*, Jan. 2008, Accessed: Jun. 12, 2024. [Online]. Available: [https://www.academia.edu/22321261/Promoting\\_Caries\\_Arrest\\_In\\_Children\\_With\\_Silver\\_Diamine\\_Fluoride\\_A\\_Review](https://www.academia.edu/22321261/Promoting_Caries_Arrest_In_Children_With_Silver_Diamine_Fluoride_A_Review).
- [3] M. A. R. Buzalaf, J. P. Pessan, H. M. Honório, And J. M. Ten Cate, "Mechanisms Of Action Of Fluoride For Caries Control," *Monogr. Oral Sci.*, Vol. 22, Pp. 97–114, Jun. 2011, Doi: 10.1159/000325151.
- [4] W. Wang, Y. Zhang, M. Gao, J. Wang, And Y. Hou, "Effect Of Rosuvastatin On Atrial Structural Remodeling In Rabbits With Myocardial Infarction," *Biomed. Reports*, Vol. 3, No. 1, Pp. 78–82, Jan. 2015, Doi: 10.3892/Br.2014.366.
- [5] M. L. Mei, E. C. M. Lo, And C. H. Chu, "Arresting Dentine Caries With Silver Diamine Fluoride: What's Behind It?," *J. Dent. Res.*, Vol. 97, No. 7, Pp. 751–758, Jul. 2018, Doi: 10.1177/0022034518774783.
- [6] P. Arrow And E. Klobas, "Minimum Intervention Dentistry Approach To Managing Early Childhood Caries: A Randomized Control Trial," *Community Dent. Oral Epidemiol.*, Vol. 43, No. 6, Pp. 511–520, Dec. 2015, Doi: 10.1111/Cdoe.12176.
- [7] S. Vanegas, A. Godoy, L. Urdaneta, D. Olávez, K. Padrón, And E. Solórzano, "Effect Of Silver Diamine Fluoride On Caries Induced In Wistar Rats," *Rev. Fac. Odontol. Univ. Antioquia*, Vol. 26, No. 1, Pp. 76–88, Jul. 2014, Doi: 10.17533/Udea.Rfo.15953.
- [8] Y. O. Crystal Et Al., "Use Of Sdf For Dental Caries Management E135 Recommendations: Clinical Practice Guideline Use Of Silver Diamine Fluoride For Dental Caries Management In Children And Adolescents, Including Those With Special Health Care Needs," Accessed: Jun. 13, 2024. [Online]. Available: <http://gdtd.guidelinedevelopment.org/app/handbook/handbook.html>.
- [9] L. De O. Fernandes Et Al., "Pulp Cell Response To The Application Of Silver Diamine Fluoride And Potassium Iodide On Caries-Like Demineralized Dentin," *Clin. Oral Investig.*, Vol. 27, No. 12, Pp. 7295–7306, Dec. 2023, Doi: 10.1007/S00784-023-05320-8.
- [10] J. Greenwall-Cohen, L. Greenwall, And S. Barry, "Silver Diamine Fluoride - An Overview Of The Literature And Current Clinical Techniques," *Br. Dent. J.*, Vol. 228, No. 11, Pp. 831–838, Jun. 2020, Doi: 10.1038/S41415-020-1641-4.
- [11] N. Seifo Et Al., "The Use Of Silver Diamine Fluoride (Sdf) In Dental Practice," *Br. Dent. J.*, Vol. 228, No. 2, Pp. 75–81, Jan. 2020, Doi: 10.1038/S41415-020-1203-9.
- [12] D. Natarajan, "Silver Modified Atraumatic Restorative Technique: A Way Towards 'Smart' Pediatric Dentistry During The Covid-19 Pandemic," *Front. Dent.*, Vol. 19, 2022, Doi: 10.18502/Fid.V19i12.9215.
- [13] A. Zaeneldin, C. H. Chu, And O. Y. Yu, "Dental Pulp Response To Silver-Containing Solutions: A Scoping Review," *Dent. J.*, Vol. 11, No. 5, May 2023, Doi: 10.3390/Dj11050114.
- [14] J. A. Horst, "Silver Fluoride As A Treatment For Dental Caries," *Adv. Dent. Res.*, Vol. 29, No. 1, Pp. 135–140, Feb. 2018, Doi: 10.1177/0022034517743750.
- [15] S. Nelson, J. M. Albert, And P. Milgrom, "Comparative Effectiveness Of Two Nonsurgical Treatments To Reduce Oral Health Disparities From Untreated Tooth Decay In Older Adults: Protocol For A Cluster Randomized Trial," *Jmir Res. Protoc.*, Vol. 9, No. 9, Sep. 2020, Doi: 10.2196/17840.