

Globulomaxillary Cyst : A Rare Case Report

Dr. Apeksha Dhole, Dr. Mukta Motwani, Dr. Mayuri Sonole,
Dr. Pratiksha Ghotkekar

(Department Of Oral Medicine And Radiology, Ranjeet Deshmukh Dental College Nagpur, Muhs, Nashik, India)

Abstract:

Background:

Globulomaxillary cyst is a rare and unique cyst. Traditionally, it was thought to be a fissural cyst between the maxillary lateral incisor and canine teeth caused by epithelial proliferation between the globular section of the medial nasal and maxillary processes. These submucosal, non-odontogenic jaw cysts cause soft tissue swellings in the maxillary anterior muco-labial fold lateral to the midline and are not painful. A 18-year-old female patient presented with pain in the upper front region of the jaw since 1 month and history of discharge from the same tooth since 5 days upon which patient took over the counter medication. Radiography revealed an inverted pear-shaped radiolucency in the left maxillary periapical area. The cyst was removed using an intra-oral technique.

Keywords: globulomaxillary cyst, inverted pear-shaped

Date of Submission: 11-05-2024

Date of Acceptance: 21-05-2024

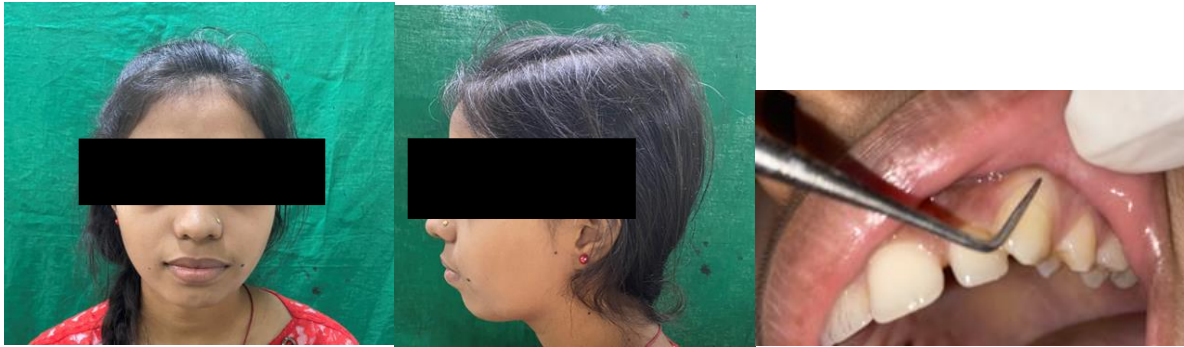I. Introduction:

A cyst is a pathological cavity in the bone or soft tissue, with an outer wall of connective tissue and an inner wall composed of epithelium. The cystic cavity contains cystic content, which can be fluid, colloidal, or semisolid.¹ Odontogenic cysts are usually intraosseous and are classified into developmental and inflammatory. Residual cysts are inflammatory in nature and result from the extraction of a tooth with a radicular cyst, but with no removal of the lesion remnants in the same surgical procedure.² An uncommon cyst called a globulomaxillary cyst is located in the maxilla, between the canine and lateral incisor. At the intersection of the medial nasal process and maxillary process, it is also referred to as a fissural cyst.³ About 17% of all non-epithelial and non-odontogenic cysts of the maxilla and mandible are composed of non-odontogenic epithelium. As they emerge from the imprisoned epithelium as a result of the union of the odontogenic (arising from tooth-developing epithelium) and upper jaw bones.⁴

This cyst has an etiopathogenesis akin to oral and facial clefts, and it is situated in the globular and maxillary process fusion area. Nonetheless, a variety of tumor types, including radicular cysts, keratocystic or adenomatoid odontogenic tumors, and periodontal cysts, can arise in the globulomaxillary region. The first description of this type of cyst was made by Thomas in 1937.⁵ Since then, several studies propose the elimination of the term as a self-sufficient entity. Ferenczy, was the first to propose that the point of fusion of the embryonic processes was anterior to and not at the bone suture seen between the maxillary lateral incisor and canine teeth (the globulomaxillary, incisive, or premaxillary-maxillary suture), the suture in which the cyst was believed to form.⁵ Embedded in the literature since years, this cyst was included in the 1971 WHO classification of histologic typing of odontogenic tumors but removed in the second edition in 1992.³

II. Case Report:

A 18-year-old female reported with a chief complaint of pain in the upper front region of the jaw since 1 month. Patient was apparently alright one month back then she started experiencing pain which was sudden onset, intermittent, throbbing, non-radiating type and mild in intensity. Then since last 5 days patient again started experiencing pain in the same region which is severe in intensity, intermittent, throbbing and non-radiating type which aggravates on biting food and reduces on its own after some time.



Patient also gives history of discharge from the same tooth since 5 days upon which patient took over the counter medication. Patient then didn't notice any pus discharge after 2 days after taking medications but she got partially relieved from pain, only the intensity of pain decreased to mild. There was no H/O tooth mobility. No H/o any food lodgement in the same region or swelling in the same region or any trauma in the same region in the past.

There was no sign of swelling extra-orally or intra-orally. Pulp vitality test in relation to 21, 22, 23, 24 revealed that the teeth were vital. Intraoral periapical radiographic investigation was suggestive of a single, well defined inverted pear shaped, unilocular radiolucency with partially corticated borders of size 2x2.5 cm is seen with partially corticated border is seen in the region of 22 23 24 extending S/I from the floor of nasal cavity upto alveolar crest and M/L from apex 21 upto apex of 24 and loss of lamina dura of 22 and distally tilted 22 and mesially tilted 23. Occlusal radiograph was suggestive of a single, well defined completely radiolucent lesion which is roughly rhomboidal in shape and is approximately 3 cm M/L from mid palatine suture upto palatal aspect of 26 and 3.5 cm A/P is extending from apex of 21 upto floor of nasal cavity with loss of lamina dura with 22 And distally tilted 22 and mesially tilted 23. CBCT was suggestive of a well-defined radiolucent lesion with corticated borders and internal structure completely radiolucent is seen in the anterior maxilla involving the periapical region of 22 and 23 of size 18.8 mm supero-inferiorly, 22.6 mm mesio-distally and 13.3 mm buccolingually in the apical third region with loss of lamina dura. No root resorption seen with 22 and 23. Discontinuity in the buccal cortical plate is seen in the region of 22. (Section 11 to 13). Discontinuity in the buccal cortical plate is seen in the region of 23. (Section 17 to 21). Thinning of buccal cortical plate seen in the region of 22. (Section 8 to 10). Thinning of buccal cortical plate seen in the region of 23. (Section 13 to 26). Discontinuity in the lingual cortical plate is seen in the region of 22. (Section 11 and 12).

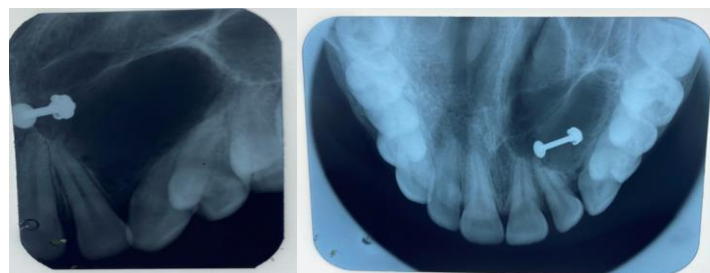


Image Showing Inverted Pear- Shaped Radiolucency (Fig 1) And Occlusal Radiograph Of The Maxilla Involving Same Region (Fig 2)

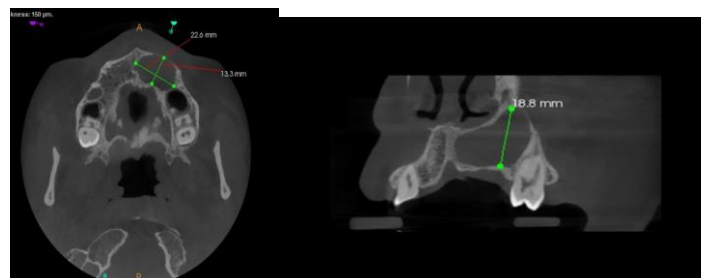

Figure Showing Cbct Images Of The Same Lesion In Axial (I) And Sagittal Section (II)

Clinical differential diagnosis of globulomaxillary cyst included lateral periodontal cyst, Adenomatoid odontogenic tumor (AOT), Odontogenic keratocyst (OKC) and surgical cleft. Patient's informed consent was

availed for the surgical removal of these cysts. Medical history did not present any contraindication for the surgical procedure. Under local anesthesia with adrenaline, a Neumann flap was raised, followed by osteotomy to reach the cystic cavity and later by enucleation. The mass of size 0.5x 0.5cm which was roughly square in shape, greyish in color, soft in consistency was completely excised and then flap was closed and uninterrupted sutures were placed. The patient was kept at follow up for four months and progress of the cystic lesion was recorded.

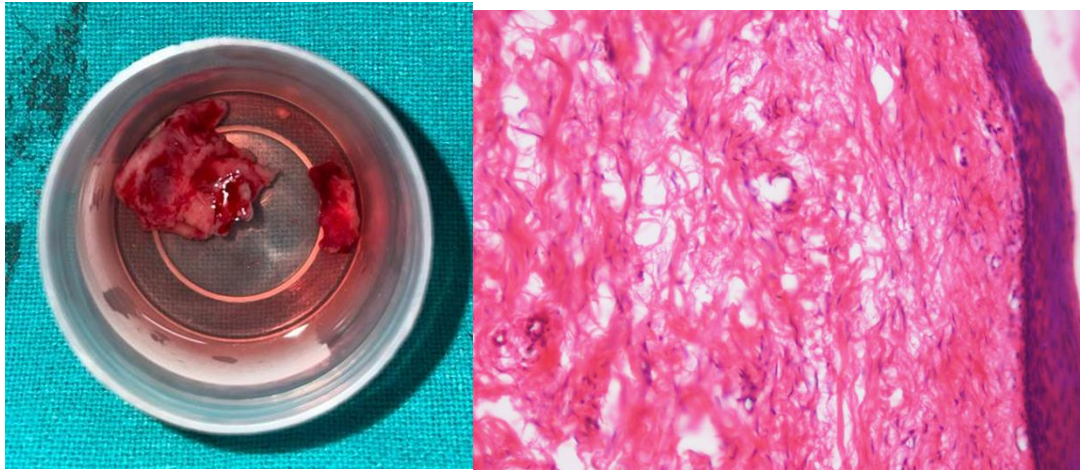


Figure Showing Biopsy Specimen And Histopathology At 20x Of The Same

An exploratory biopsy revealed cystic lumen with a thin uniform para-keratinized stratified squamous epithelium, supporting fibrous connective tissue wall, which shows dense chronic inflammatory cell infiltrate and few blood vessels features s/o globulomaxillary cyst.

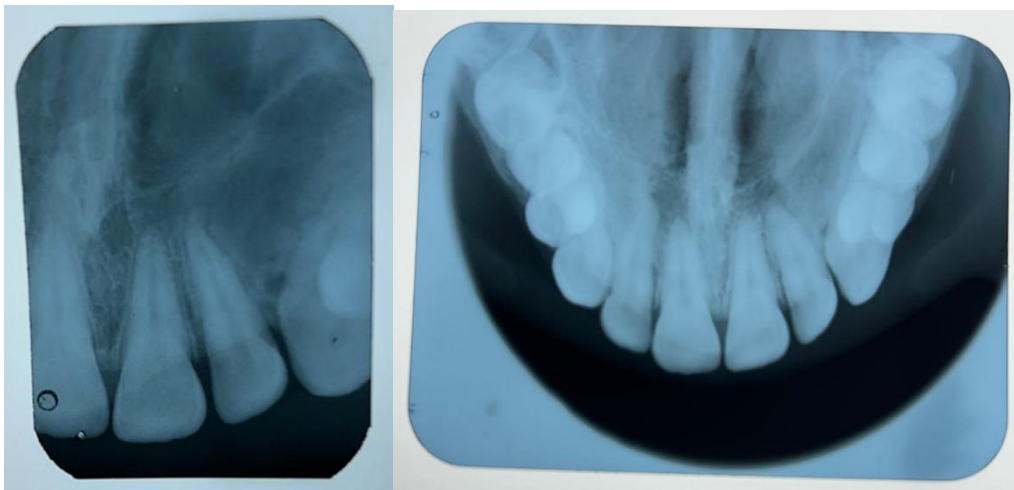


Figure Showing Iopa And Occlusal Radiograph Of The Site Of The Lesion After 4 Months After Treatment

III. Discussion:

Intraorally, a globulomaxillary cyst presents as a soft-tissue swelling of the maxillary anterior mucolabial fold, lateral to midline leading to obliteration of the nasolabial fold. In radiography, the characteristic appearance of a globulomaxillary cyst is that of an inverted pear or teardrop, with a clearly visible radiolucency between the separated roots of the canine and lateral incisor. To offer an accurate diagnosis and suitable treatment, a thorough documentation of the case history, a precise clinical examination, sufficient imaging, and a histological report are required. The cyst in most cases presents the characteristic shape of a reverse pear. Nevertheless, there are more than a few reports in the literature of true globulomaxillary cysts which cannot be ignored.

Recently, it has been included as a fissural cyst secondary to proliferation of entrapped epithelium between the globular portion of the medial nasal and maxillary processes. Aisenberg and Inman announced a very rare case of ameloblastoma arising from the epithelium of a nonodontogenic globulomaxillary cyst. Robinson et al noted in a GBC both stratified, squamous, and ciliated columnar epithelium, with clinical, radiographic, and microscopic evidences compatible with a diagnosis of an infected GBC.³

A globulomaxillary cyst might lead to disposition of teeth involved or inflammation. Rarely, a globulomaxillary cyst might enter the nasal cavity, causing nasal obstruction, bleeding, inflammation and cosmetic deformity. Thus, the certain diagnosis and rapid treatment with excision of the cyst are essential. The excision can be a simple procedure performed by sub-labial approach, which helps avoiding any cosmetic deformity.

The extant literature suggests that a mass may be classified as a globulomaxillary cyst if it satisfies the following criteria: (a) the location of the cyst in relation to the globulomaxillary bone and the vitality of the teeth that are associated with it (regarded as clinical criteria); (b) the shape of a reverse pear and the divergence of the associated teeth's roots (regarded as radiographic criteria); and (c) the nature of the cyst's lining, which is a histologic criterion. In our instance, however, it met the majority of the requirements, including the radiological inverted pear form and the histologically stratified squamous epithelium. If FNAC had been performed before to the cyst's enucleation, the results would have been more conclusive. Additionally, since it did not point to a specific cyst, we made the diagnosis by exclusion. Taking into account that the initial differential diagnosis in this case is a lateral periodontal cyst, we ruled it out because no accessory canal was present. The patient had no history of trauma in that area, and there were no signs of an odontogenic infection, so we again ruled out radicular cysts, which are very common at that site. The radiograph revealed loss of lamina dura with lateral incisor and canine, but this could be due to pressure from the cyst or retrograde infection. Thus, we deduced that this is a globulomaxillary cyst based on these exclusion criteria.

"In line with past comparable investigations, we use the name "globulomaxillary cyst" to refer to this lesion since no other terminology can adequately characterize it. Huston et al. (2017) state that this particular sort of cyst has unique characteristics that do not correspond with other possible diagnosis.⁵ Following a thorough review of the literature, Haring et al. came to the conclusion in their study that globulomaxillary cysts shouldn't be categorized as distinct entities because they don't appear to be one. According to them, the word "globulomaxillary" should only be used to describe a lesion that lies between the neighboring canine and the maxillary lateral incisor. They insisted that a comprehensive clinical, radiographic, and histological evaluation was necessary before a final diagnosis could be made. The WHO's 2005 categorization of head and neck malignancies did not publish or acknowledge the word "globulomaxillary cyst" as an entity, which lends credence to the dispute surrounding it.⁵

All the same, recent research in embryology has refuted Christ's theory of facial development. There is fusion of the facial processes and entrapment of the epithelium in areas that would eventually reside between the canines and maxillary lateral incisors. Based on both embryological and histological evidence, this review proposes that globulomaxillary cysts should once again be recognized as distinct clinicopathologic entities.³

IV. Conclusion:

In the presented case; clinical, radiographic and histological features of the lesions were suggestive of Globulomaxillary cyst (residing on the alveolar surface) on the left side, which were successfully enucleated by a modification of intraoral sublingual surgical approach. After four months of follow-up, no evidence of complications or recurrence was observed.

References:

- [1] Chhabra N, Chhabra S, Kumar A. Cyst Enucleation Revisited: A New Technical Modification To Ensure Complete Removal Of Cystic Lining. *Journal Of Maxillofacial And Oral Surgery*. 2020 Jun;19:173-7.
- [2] Romero-Blanquicett A, Martínez-Martínez A, Díaz-Caballero Aj. Treatment Of A Residual Cyst Located In The Upper Maxilla. A Case Report. *Revista Facultad De Odontología Universidad De Antioquia*. 2018 Dec;30(1):121-6.
- [3] Saran G, Umopathy D, Mishra N, Channaiah Sk, Sumalatha G, Rai P. Globulomaxillary Cyst In A 16 Year Old Male Patient—A Case Report With Review. *Journal Of Oral Medicine, Oral Surgery, Oral Pathology And Oral Radiology*. 2016;2(3):164-6.
- [4] Mojumder D, Chowdhury Ru, Podder A. Enucleation After Marsupialization: A Case Report Of Globulomaxillary Cyst. *Updcj*. 2020 Apr;10(1):25-7.
- [5] Panagouli E, Tsoucalas G, Vasilopoulos A, Thomaidis V, Fiska A. Globulomaxillary Cyst: Does It Still Exist?. A Case Report. *Arch Balk Med Union*. 2019 Jun;54(2):11-5.