

Evaluation Of Golden Proportion And Gingival Zenith In Younger Population Of Saurashtra Region – A Randomized Clinical Study

Dr. Arun Gupta, Dr. Nidhiben Patel, Dr. Sandesh Gosavi, Dr. Pratik Bhatnagar,
Dr. Gunjan Gupta And Dr. Nikunjibhai Sorathiya

¹professor And Head, Department Of Prosthodontics, College Of Dental Science And Hospital,
Amargarh – 364 210, Gujarat, India

²pg Student – 3rd Year, Department Of Prosthodontics, College Of Dental Science And Hospital,
Amargarh – 364 210, Gujarat, India

³professor, Department Of Prosthodontics, College Of Dental Science And Hospital,
Amargarh – 364 210, Gujarat, India

⁴reader, Department Of Prosthodontics, College Of Dental Science And Hospital,
Amargarh – 364 210, Gujarat, India

⁵reader, Department Of Periodontics, College Of Dental Science And Hospital,
Amargarh – 364 210, Gujarat, India

⁶pg Student – 3rd Year, Department Of Conservative And Endodontics, College Of Dental Science
And Hospital,
Amargarh – 364 210, Gujarat, India

Abstract

We aimed to measure and compare the golden proportion and gingival zenith position in adult volunteers in Saurashtra region, Gujarat. In esthetic dentistry, anterior rehabilitation and smile designing cases thorough knowledge of golden proportion and gingival zenith position of maxillary anterior teeth merit clinical importance. Young adult's volunteers in age group between 18 to 30 years without any dental deformity were selected for the study. Inclusion criteria involved absence of periodontal diseases. Alginate impressions were made and diagnostic casts was obtained. A MGW digital caliper (No. BO7XRLIFJ8) was used to measure the golden proportion and gingival zenith positions of maxillary right and left anterior teeth. Data were statistically analyzed by IBM SPSS Version software. The findings indicated that there was significant difference in the value of golden proportion ($p \leq 0.05$) between right and left side of lateral incisor (LI). The mean values of gingival zenith position in central incisor – lateral incisor (CI-LI) at right and left side were statistically significant ($p \leq 0.05$). The average values of gingival zenith position at right side and left side of central incisor – canine (CI-canine) were significantly differed ($p \leq 0.05$). To validate the findings, further studies need to be carried out with larger sample size in different ethnic groups and races.

Keywords: Golden proportion, Gingival zenith position, Maxillary anterior teeth, Esthetic dentistry, Digital caliper

Date of Submission: 11-05-2024

Date of Acceptance: 21-05-2024

I. Introduction

Gingival esthetics has always been an important component of a beautiful smile. It plays a symbolic role in oral rehabilitation and affects positively in the self-esteem and psychosocial wellbeing of patients^{1,2}. The esthetic outcomes merit importance for the satisfaction of patient which comprises adequate size, shape, color, biotype, gingival zenith, smile line, axial inclination graduation, incisal embrasure graduation, and gingival frame contour²⁻⁴.

Levin (1978) proposed the theory of golden proportion (GP) which postulates that the dimensions of the central incisor (CI), lateral incisor (LI), and the canine (Ca), as well as within the dimensions of a smiling face should be applied to the arrangement of anterior teeth in their esthetic rejuvenation⁵. It is a mathematically constant ratio (1.618:1.0) and widely observed in nature. This particular relationship is distinct, precise, idyllic and suitable and its application to dental esthetics is facilitated by the description and inclusion of a dental grid for the anterior esthetic segment. However, the theory postulated by Snow (1999) on GP concluded that dividing the relative width of each tooth by the sum of the widths of all the teeth yields the percentage width

occupied by each individual tooth in the inter canine distance seen in frontal view⁶. Albeit, several investigators used the GP tool to quantify and analyze facial features in their countries such as Brazil⁷, Japan⁸ and India⁹. On the contrary, Preston suggested that the tooth dimensions vary greatly by race and gender and therefore the GP cannot be applied to the relationship of maxillary anterior teeth¹⁰.

The appearance of the gingival tissues surrounding the teeth plays an important role in the esthetics of the anterior maxillary region of the mouth¹¹. The location of gingival zenith in a medial-lateral position relative to the vertical tooth axis of the maxillary anterior teeth remains to be clearly defined. In addition, the apex of the free gingival margin of the lateral incisor teeth relative to the gingival zeniths of the adjacent proximal teeth remains undermined². Correct positioning of zenith following therapeutic manipulation merits importance, because it may greatly influence the emergence profile and axial inclination of teeth¹².

Within this context, we find paucity of data on dento-gingival components of esthetics like golden proportion (GP) and gingival zenith position (GZP) in adult population of Saurashtra region and therefore, the study was designed to measure and report the golden proportion (GP) and gingival zenith position (GZP) of the maxillary anterior teeth in adult volunteers of Saurashtra region.

II. Materials And Methods

Study Population: The experimental sample consisted of 80 adult volunteers (aged -18 to 30 years) attending the Department of Prosthodontics, College of Dental Science and Hospital, Amargadh – 364 210, Gujarat. The inclusion criteria being the subjects should be of Saurashtra region with intact dentition, caries and periodontal disease-free anterior teeth, no signs of incisal attrition, gingival recession or passive eruption, and no previous history of orthodontic treatment. A short description of the study was given to all participants and informed consent received from each subject. The study was approved from the institutional ethical committee.

Clinical Data Collection: Alginate impressions of the subjects was made using irreversible hydrocolloid impression material and immediately poured with dental stone according to the manufacturer's specifications (Kalabhai Dental Stone No. 3). A digital caliper (No. BO7XRL1FJ8; accurate to 0.01 mm) was used to measure the sites of the anterior maxillary teeth from canine to canine (Fig. 1). The device was calibrated prior to each reading. Evaluations regarding the occurrence of the golden proportion were conducted by drawing of grids that obtained by placing the casts on a flat surface and drawing vertical lines representing the visible mesiodistal widths of the teeth. Measurements were taken for the spaces in the grids using the digital caliper (Fig. 2). The highest point of the free gingival margin was marked on both right and left maxillary central incisors, lateral incisors and canines. The distance of the highest gingival margin position from the vertical bisector of the respective tooth was measured. This provides the mesio-distal position of gingival zenith from midline of each individual tooth. A line connecting gingival zenith of maxillary central incisor, lateral incisors and canine was drawn on both right and left sides. The digital caliper was used to measure the distance between three gingival zenith line (Fig. 3). The actual width of the anterior teeth and the visible width of anterior teeth view from front were measured using a digital caliper.

Statistical analysis: All the data were coded and entered Microsoft Excel 2007 and then transferred into IBM SPSS version 20.0 software for statistical analysis. Quantitative data were interpreted as mean \pm SD. The level of significance was considered statistically significant at $p \leq 0.05$.



Fig. 1: Digital caliper

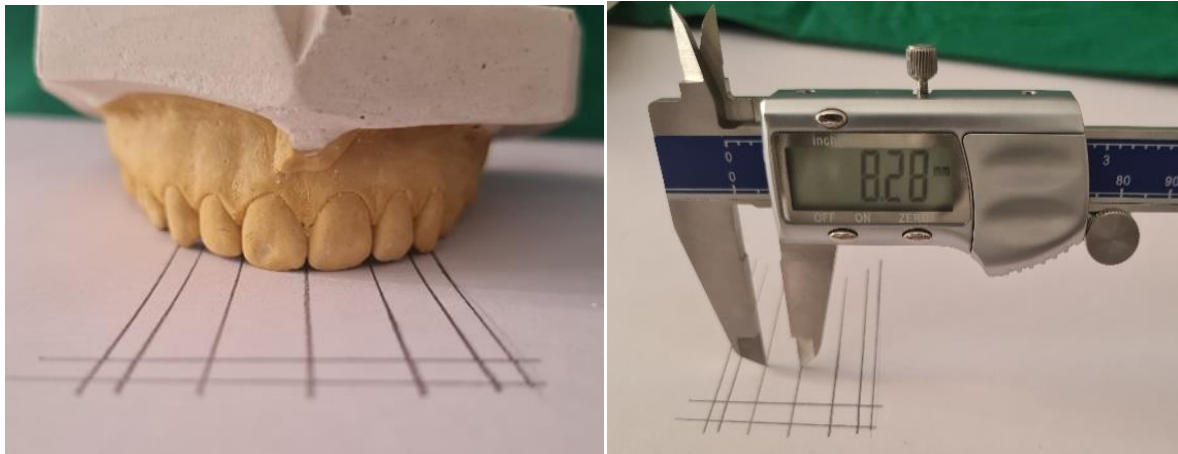


Fig. 2: Measurement of golden proportion with grids

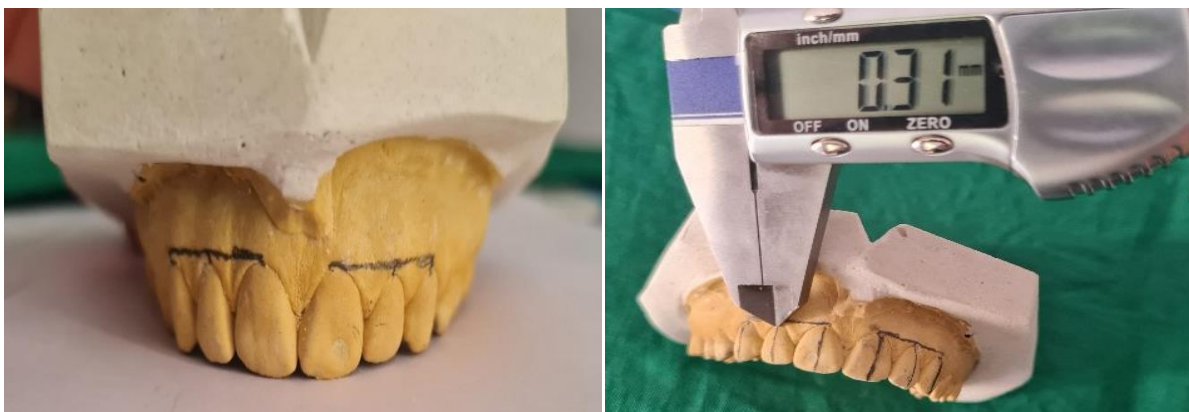

Fig. 3: Measurement of Gingival Zenith markings

III. Results

Table 1 summarizes the data on golden proportion in central incisor (CI), lateral incisor (LI) and canine. Mean golden proportion value in LI was higher (5.49) than right side (5.45) and the difference were statistically significant ($p \leq 0.05$). The value of golden proportion in left side of CI was higher than right side, but the difference was not significant. Also, no significant difference in the value of golden proportion of canine was noticed between left side and right side.

Table1: Mean value of golden proportion in CI, LI and canine

Tooth	Side	Number	Mean	SD	P Value
CI	Right	80	8.43	0.51	0.481
	Left	80	8.44	0.50	
LI	Right	80	5.45	0.48	0.006*
	Left	80	5.49	0.44	
Canine	Right	80	2.91	0.36	0.485
	Left	80	2.90	0.33	

SD = standard deviation; *Mean difference is significant at 0.05 level

Data on mean value of gingival zenith position in right and left side of CI-LI, canine-LI and CI-canine have been given in Table 2. The value of gingival zenith position in left side of CI-LI was higher (0.29) than the right side (0.28). Statistically, the difference between right and left side in gingival zenith at CI-LI was highly significant. Statistically, no significant difference was present between right and left side in gingival zenith position at canine-LI. The value of gingival zenith was high in right side (0.21) than the left side (0.20). Statistically, significant difference was observed between right and left side in gingival zenith at CI-canine.

Table 2: Mean value of gingival zenith position in CI-LI, Canine-LI and CI-canine

Tooth	Side	Number	Mean	SD	Significance
CI-LI	Right	80	0.28	0.03	0.008*
	Left	80	0.29	0.04	
Canine-LI	Right	80	0.23	0.03	0.256
	Left	80	0.23	0.03	
CI-canine	Right	80	0.21	0.03	0.002*
	Left	80	0.20	0.03	

SD = standard deviation; *Mean difference is significant at 0.05 level

IV. Discussion

The formation of geometric relationship in anterior teeth of maxilla is essential in order to make an esthetically acceptable restoration. Esthetics is the prime consideration for all the patients seeking replacement of missing teeth. The width-to-height ratio of the maxillary central incisors has been suggested to be significant in terms of overall dental appearance because these teeth normally dominate the smile of an individual and proposed to be related to a golden proportion^{13,14}. The results of the present study showed significant difference in the mean value of golden proportion between left side and right side of lateral incisor ($p \leq 0.05$).

The dentogingival esthetic units have been studied extensively in dental literature. Along with other parameters related to dental esthetics, these clinical parameters applied to gingival contours may serve as esthetic guidelines and may enable us to obtain a more predictable esthetic outcome. Our findings on GZP indicated significant difference between left and right side of CI-LI and CI-canine. In our study, we relied on the measurement from cast rather than clinical examination. Quantitative and qualitative evaluation of the degree of crown inclination and the position of the GZP and levels has not yet been extensively studied. These data could be used as reference points during esthetic anterior oral rehabilitation and clinical management of the dentogingival complex and enhance periodontal and restorative procedures in the anterior maxillary dentition. Facial beauty is evaluated by several factors such as genetic, ethnic, cultural and environmental¹⁵. It can be assessed literally by global parameters such as neoclassic laws and the GP, and the faces with different characteristics which may found attractive in different ethnic groups, races and culture¹⁶. The major limitation of the study was the small sample size and therefore, a multi-centric study with a large sample size and cultural diversity may be recommended.

V. Conclusion

The findings indicated that there was significant difference in the value of golden proportion ($p \leq 0.05$) between right and left side of lateral incisor (LI). The mean values of gingival zenith position in central incisor – lateral incisor (CI-LI) at right and left side were statistically significant ($p \leq 0.05$). The average values of gingival zenith position at right side and left side of central incisor – canine (CI-canine) were significantly differed ($p \leq 0.05$).

Conflicts of Interest

The authors declare no conflict of interest.

Acknowledgements

The authors thank all participants for support and facilitation of the study.

References

- [1] Ahmed N, Halim Msb, Ghani Za, Khan Za, Abbasi Ms, Jamayet Nb, Alam Mk. A 2d Photographic And 3d Digital Dental Model Analysis Of Golden Percentage In Maxillary Anterior Teeth. *Biomed Res Inter* 2021, Article Id 6674400 | <https://doi.org/10.1155/2021/6674400>
- [2] Chu Sj, Tan J H-P, Stappert Cfj, Tarnow Dp. Gingival Zenith Positions And Levels Of The Maxillary Anterior Dentition. *Jour Esthet Restor Dent* 2009;21(2):113-120.
- [3] Bhuvaneshwaran M. Principles Of Smile Design. *Jour Conser Dent* 2010;13(4):225-232.
- [4] Sharma A. A Descriptive Study Of Some Of The Dentogingival Components Of Esthetics Of Patients At A Tertiary Care-Center In The Eastern Part Of Nepal. *Inter Jour Dent* 2022, Article Id 558930; [Doi.Org/10.1155/2022/5589309](https://doi.org/10.1155/2022/5589309)
- [5] Levin E. I. Dental Esthetics And The Golden Proportion. *Jour Prosthet Dent* 1978;40(3):244-252.
- [6] Snow Sr. Esthetic Smile Analysis Of Maxillary Anterior Tooth Width: The Golden Percentage. *Jour Esthet Dent* 1999;11(4):177-184.
- [7] Peron Aplm, Morosini Ic, Correia Kr, Moresca R, Petrelli E. Photometric Study Of Divine Proportion And Its Correlation With Facial Attractiveness. *Dent Press Jour Orthod* 2012;17(2):124-131.
- [8] Mizumoto Y, Deguchi T, Fong Kwc. Assessment Of Facial Golden Proportions Among Young Japanese Women. *Amer Orthod Dentofac Orthop*. 2009;136(2):168-174.
- [9] Sunilkumar Ln, Jadhav Ks, Nazirkar G, Singh S, Nagmode Ps, Ali Fm. Assessment Of Facial Golden Proportions Among North Maharashtra-An Population. *Jour Inter Oral Hlth*. 2013;5(3):48-54.
- [10] Preston Jd. The Golden Proportion Revisited. *Jour Esthet Restor Dent* 1993;5(6):247-251.
- [11] Mattos Cm, Santana Rb. A Quantitative Evaluation Of The Spatial Displacement Of The Gingival Zenith In The Maxillary Anterior Dentition. *Jour Periodontal* 2008;79(10):1880-1885.
- [12] Gowd S, Shankar T, Chatterjee S, Mohanty P, Sahoo N, Baratam S. Gingival Zenith Positions And Levels Of Anterior Dentition In Cases Of Bimaxillary Protrusion: A Morphometric Analysis. *Jour Contem Dent Pract* 2017;18(8):700-704.
- [13] Sulaiman E, Yaakab Ms, Zulkifi Na, Abdulla M, Gonzalez Ma. Existence Of Golden Proportion In Maxillary Anterior Teeth Of University Of Malaya Dental Students. *Annal Dent Univ Malaya* 2010;17:9-14.
- [14] Kaya Ks, Turk B, Cankaya M, Seyhun N, Coskun Bu. Assessment Of Facial Analysis Measurements By Golden Proportion. *Brazilian Jour Otorhinolaryn* 2019;85(4):494-501.
- [15] Havens Dc, Mcnamara Ja, Sigler Lm, Baccetti T. The Role Of The Posed Smile In Overall Facial Esthetics. *Angle Orthod* 2005;80:322-328.
- [16] Mizumoto Y, Deguchi T Sr, Fong Kw. Assessment Of Facial Golden Proportions Among Young Japanese Women. *Amer Jour Orthod Dento-Facial Orthop* 2009;136:168-174.